



HAL
open science

Quantification of intramuscular fat and subcutaneous adipose tissue in rainbow trout using MRI and vision

G. Collewet, Jérôme Bugeon, J. Idier, S. Quellec, Benjamin Quittet, M. Cambert, Pierrick Haffray, Marc Vandeputte, Mathilde Dupont-Nivet

► To cite this version:

G. Collewet, Jérôme Bugeon, J. Idier, S. Quellec, Benjamin Quittet, et al.. Quantification of intramuscular fat and subcutaneous adipose tissue in rainbow trout using MRI and vision. 1. Annual Conference on Carcass Evaluation, Meat Quality, Software and Traceability, Sep 2012, Dublin, Ireland. 2012, First annual Conference on Carcass Evaluation, Meat Quality, Software and Traceability. hal-02600018

HAL Id: hal-02600018

<https://hal.inrae.fr/hal-02600018>

Submitted on 16 May 2020

HAL is a multi-disciplinary open access archive for the deposit and dissemination of scientific research documents, whether they are published or not. The documents may come from teaching and research institutions in France or abroad, or from public or private research centers.

L'archive ouverte pluridisciplinaire **HAL**, est destinée au dépôt et à la diffusion de documents scientifiques de niveau recherche, publiés ou non, émanant des établissements d'enseignement et de recherche français ou étrangers, des laboratoires publics ou privés.

Quantification of intramuscular fat and subcutaneous adipose tissue in rainbow trout using MRI and vision

G. Collewet^{1,2}, J. Bugeon³, J. Idier⁴, S. Quéllec^{1,2}, B. Quittet⁵,
M. Cambert^{1,2}, P. Haffray⁵, M. Vandeputte^{6,7}, M. Dupont-Nivet⁷

¹ Irstea, UR TERE, 17 avenue de Cucillé, CS 64427, F-35044 Rennes ² Université européenne de Bretagne ³ INRA, UR1037, LPGP, IFR140, F-35000 Rennes
⁴ IRCCyN, CNRS, UMR 6597, F-44321 Nantes 03 ⁵ SYSAAF, F-35000 Rennes ⁶ Ifremer, UMR110 INTREPID, Chemin de Maguelone, F-34250 Palavas-les-Flots
⁷ INRA, UMR1313 Génétique Animale et Biologie Intégrative, F-78350 Jouy-en-Josas

Objective and context

The aim of this work was to evaluate the potentiality of Magnetic Resonance imaging (MRI) to quantify both **intramuscular lipids** and **subcutaneous adipose tissue** on cutlets of rainbow trouts **after freezing and thawing** in a view to handling large number of samples needed in selective breeding programs for example.

Intramuscular lipids measurements were compared to NMR measurements and vision was used to validate the MRI measurements of subcutaneous adipose tissue.

Intramuscular lipids: comparaison of MRI with NMR on fresh and frozen-thawed cutlets

27 half-cutlets were analysed 3 by 3, firstly fresh and then frozen and thawed, by MRI (1.5T Avanto, Siemens, fig. 1) at 4°C. Acquisition parameters were set so as to obtain the best compromise between spatial resolution and acquisition time (7min 22sec). MRI signal intensity was converted into lipid content and variations of the signal linked to the position of the cutlets in the device were corrected for. Flesh was cut and analysed by NMR (fig. 2). Intramuscular fat content on fresh and frozen-thawed cutlets measured by MRI were highly correlated with the NMR measurements. The standard error of calibration was respectively **0.80%** and **0.89%** (fig. 3). **The freezing-thawing process did not significantly disturb the measurement.**




Fig 1. experimental device

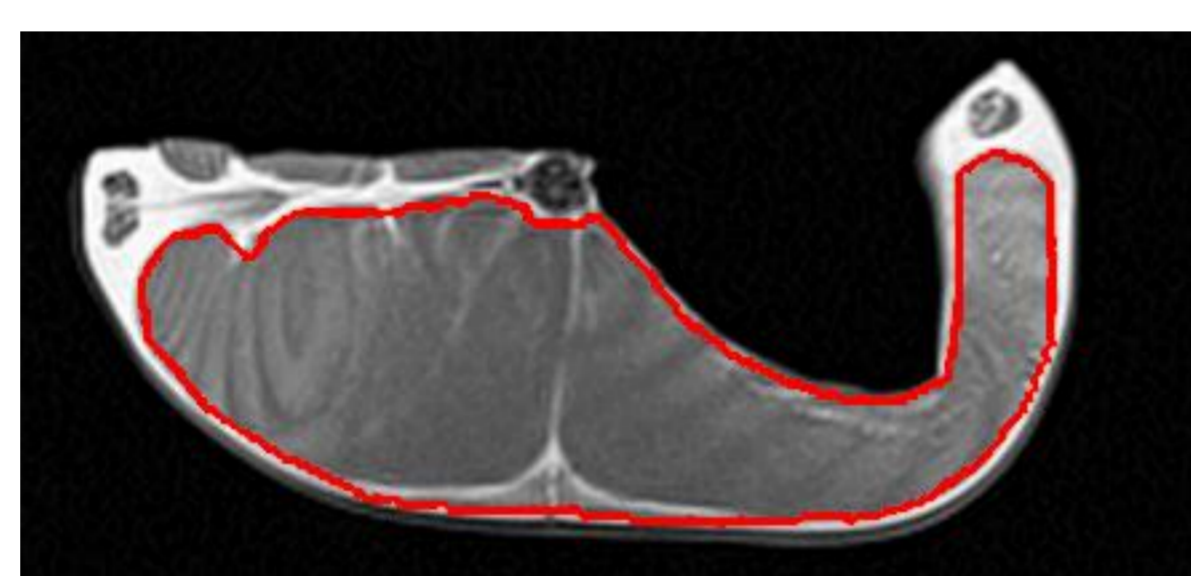


Fig 2. MR image of a half-cutlet. The average signal intensity inside the region delimited in red was computed. The flesh was then cut, crushed, dried and analysed for the lipid content measurement by NMR.

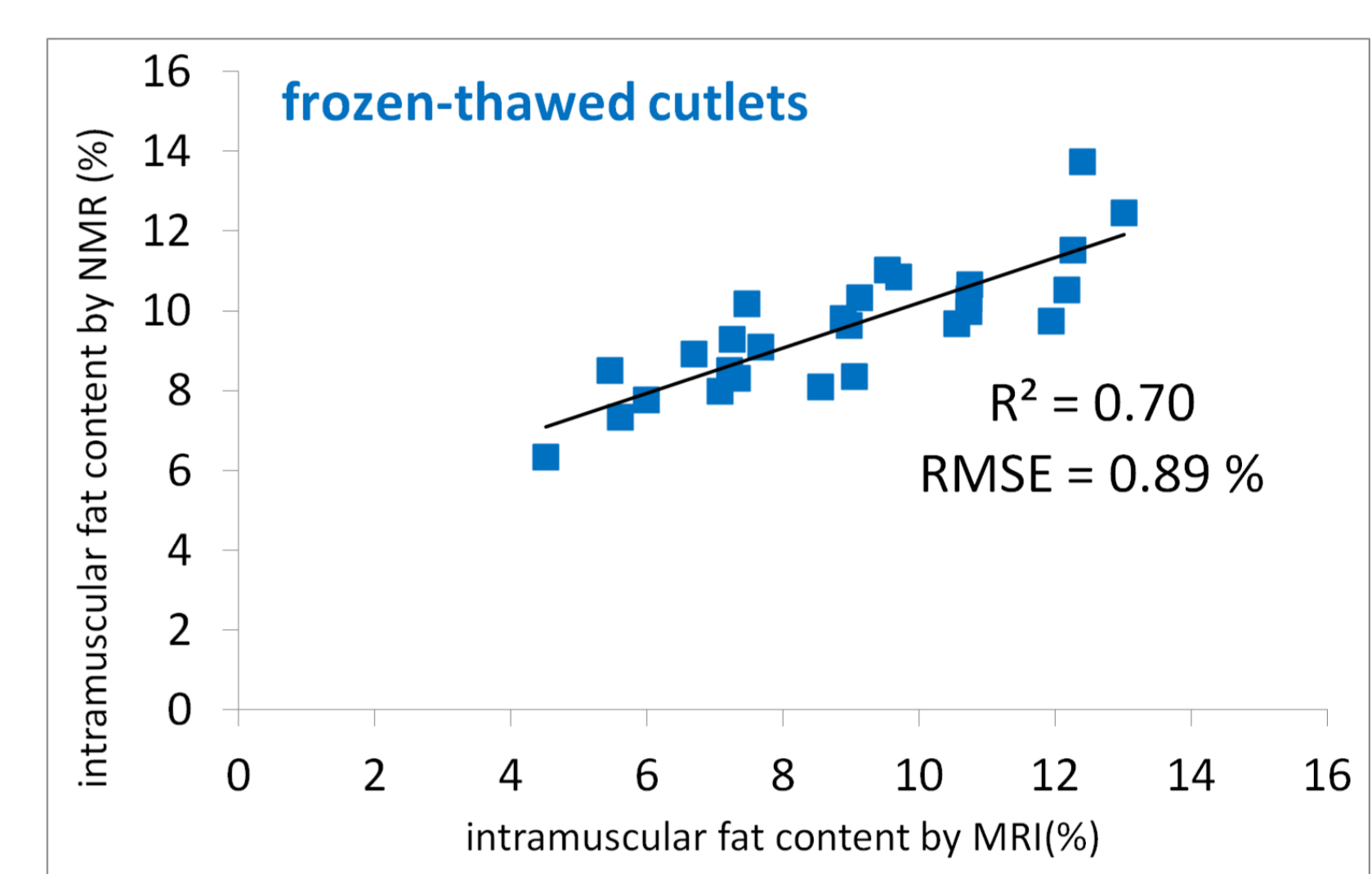
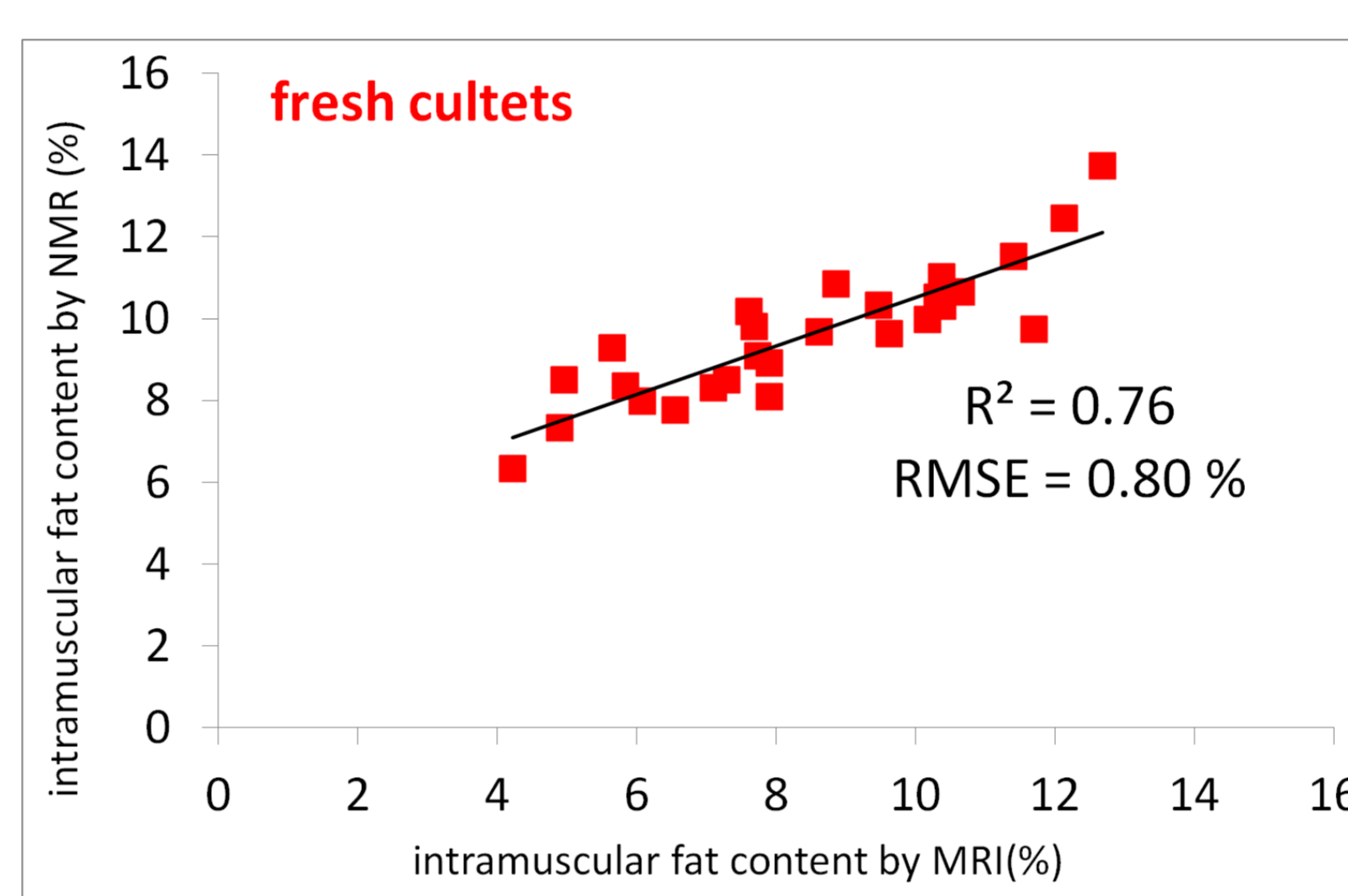


Fig 3. Comparison of MRI and NMR intramuscular fat content measurements, on the left for fresh cutlets, on the right for frozen-thawed cutlets

Quantification of subcutaneous tissue: comparison of MRI with vision

Images of 84 cutlets of large rainbow trouts (1.7 ± 0.29 kg) were acquired with a colour scanner (Epson 10000 XL pro, fig 4) and then frozen. After thawing there were set horizontally in the MRI four by four and analysed with the same protocol used for the quantification of intramuscular lipids. Scanner and MRI images were automatically analysed in order to delimitate the subcutaneous fat and quantify its area. Dorsal and ventral subcutaneous fat were separated (fig. 5). **High correlation between MRI and vision results were found : $R^2 = 0.77$ and 0.87 for ventral and dorsal subcutaneous fat areas** (fig. 6).

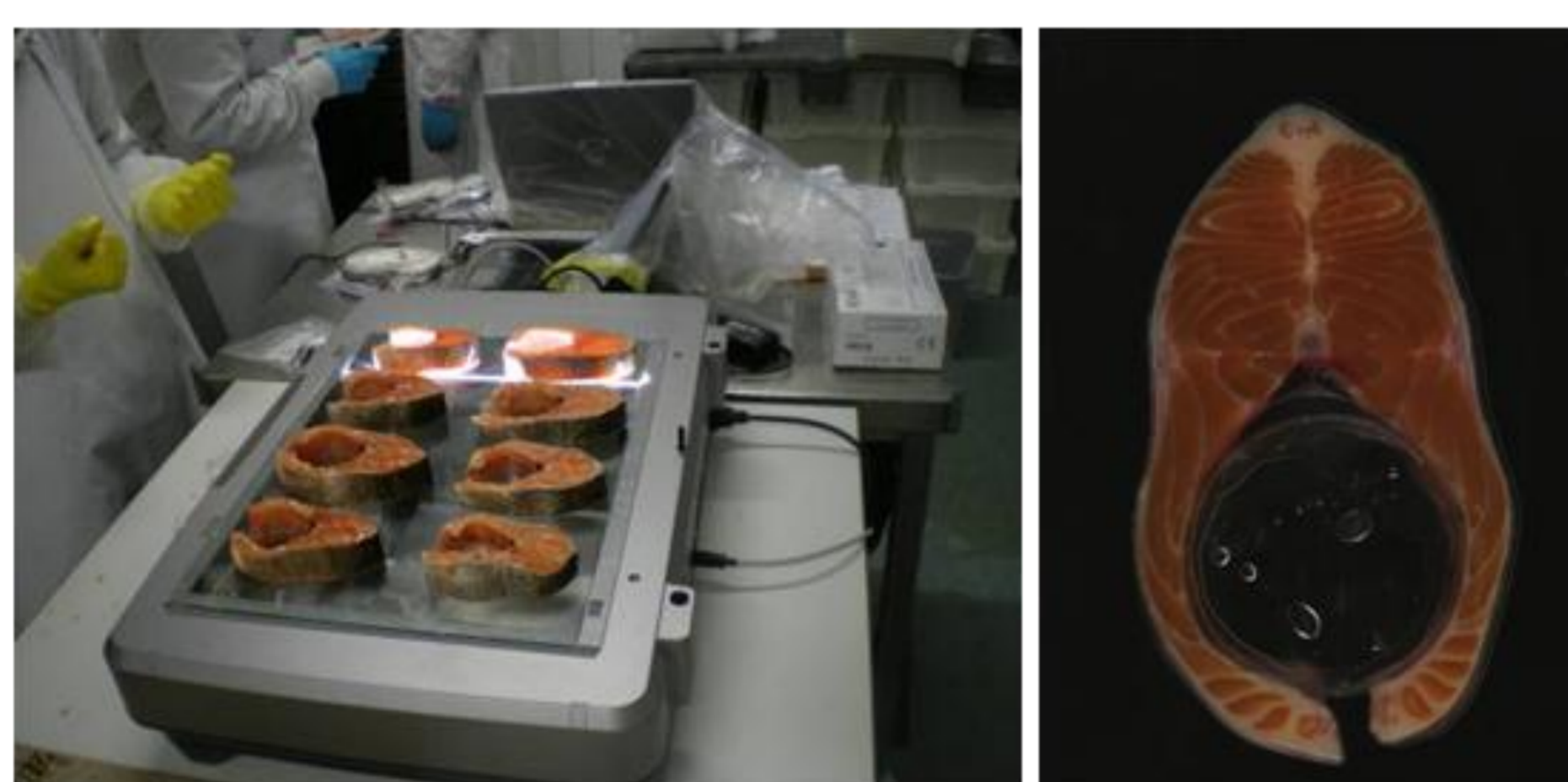


Fig. 4. Colour scanner and an example of an image of a cutlet

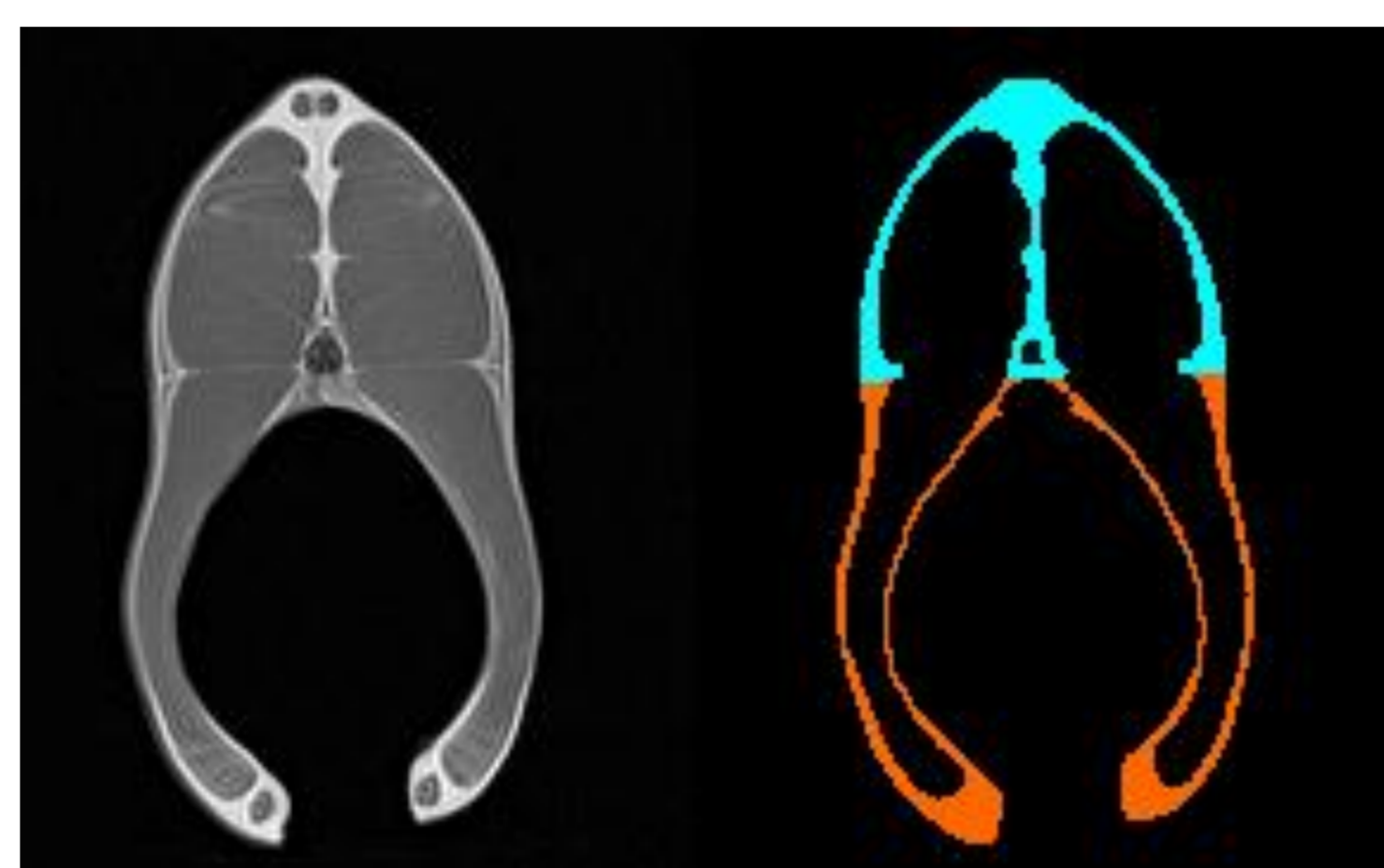


Fig. 5. MRI image on the left, ventral and dorsal subcutaneous fat on the right

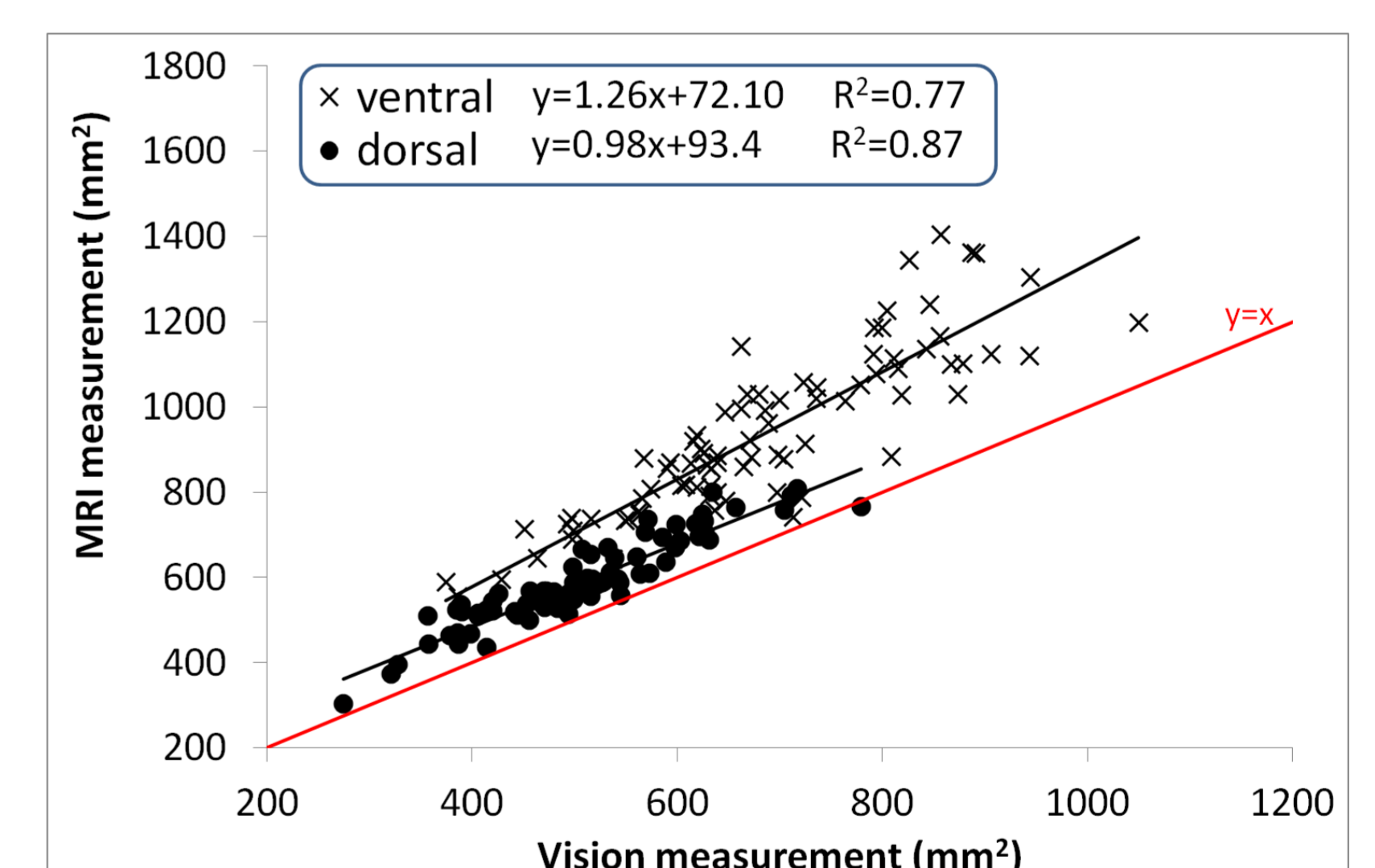


Fig 6. Comparison of MRI and vision measurements for ventral and dorsal subcutaneous fat

Conclusion and perspectives

These results showed the feasibility of intramuscular lipids measurement with MRI on cutlets after freezing and thawing. One great advantage of MRI is that no preparation of the samples is required. Moreover, the quantification and the repartition of subcutaneous fat can also be measured by MRI. The acquisition time was about 2 minutes per cutlet. This opens the way to experiments including high number of samples as encountered in selective breeding programs