



HAL
open science

Rapidly Growing Tumour on the Forearm of an 83-year-old Woman: A Quiz

Chakib El Habnoui, H el ene Cornillier, Val erie Tauveron, Serge Guy etant,
Annabel Maruani

► **To cite this version:**

Chakib El Habnoui, H el ene Cornillier, Val erie Tauveron, Serge Guy etant, Annabel Maruani. Rapidly Growing Tumour on the Forearm of an 83-year-old Woman: A Quiz. *Acta Dermato-Venereologica*, 2019, 99, pp.121-122. 10.2340/00015555-3054 . hal-02618135

HAL Id: hal-02618135

<https://hal.inrae.fr/hal-02618135v1>

Submitted on 25 May 2020

HAL is a multi-disciplinary open access archive for the deposit and dissemination of scientific research documents, whether they are published or not. The documents may come from teaching and research institutions in France or abroad, or from public or private research centers.

L'archive ouverte pluridisciplinaire **HAL**, est destin ee au d ep ot et  a la diffusion de documents scientifiques de niveau recherche, publi es ou non,  emanant des  tablissements d'enseignement et de recherche fran ais ou  trangers, des laboratoires publics ou priv es.



Distributed under a Creative Commons Attribution - NonCommercial 4.0 International License

Rapidly Growing Tumour on the Forearm of an 83-year-old Woman: A Quiz

Chakib EL HABNOUNI^{1,2}, H el ene CORNILLIER^{1,2}, Val erie TAUVERON², Serge GUYETANT^{1,3} and Annabel MARUANI^{1,2}

¹University of Tours, ²Department of Dermatology, CHRU Tours, FR-37044 Tours Cedex 9, and ³Department of Pathology, CHRU Tours, Tours, France. E-mail: habnoui@gmail.com

An 83-year-old woman underwent a radical mastectomy with axillary lymph-node dissection on the left side to treat breast cancer, followed by chemotherapy and radiation therapy in 2006. Three years after the radiation therapy, chronic lymphoedema developed in her left arm.

In March 2018, the patient reported erythema and induration with a small erythematous nodule on her left forearm. Topical steroids had no clinical benefit. Two months later, the first nodular lesion rapidly increased in size, to reach 15 cm in circumferential length (Fig. 1a). Multiple violaceous satellite lesions developed within the area of the erythema and induration and extended to the chest wall (Fig. 1b).

Blood cell count and results of haemostasis, liver and renal function tests were within normal limits. Doppler ultrasound examination of the left forearm revealed arterial blood flow inside the main lesion.

Two nodular lesions on the chest were biopsied. Histopathology with immunochemistry showed extensive infiltration of the dermis by atypical cells positive for CD31 and negative on pan-cytokeratin and human herpesvirus-8 staining.

What is your diagnosis? See next page for answer.

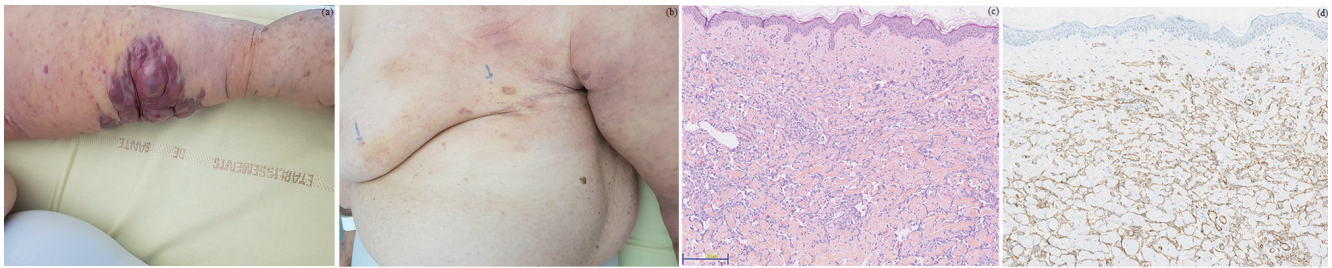


Fig. 1. (a) Clinical photography of the left forearm of an 83-year-old woman with a violaceous skin tumour and surrounding satellite lesions. (b) Clinical image: extensive lesions on the chest wall (ecchymotic areas with lilaceous nodules). (c) Coloration haematoxylin phloxine saffron stain (HPS), $\times 10$ magnification: section of a cutaneous papule from the chest revealing a normal epithelium and a dermis infiltrated by irregular anastomosing vascular channels. (d) Immunohistochemistry, $\times 10$ magnification: infiltration of dermis by CD31⁺ cells.

ANSWERS TO QUIZ

Rapidly Growing Tumour on the Forearm of an 83-year-old Woman: A Commentary

Acta Derm Venereol 2018; XX: XX–XX.

Diagnosis: Stewart-Treves syndrome

Stewart-Treves syndrome is a rare cutaneous angiosarcoma arising in the setting of lymphoedema, with poor prognosis. This malignant vascular tumour can develop in cases of long-standing chronic lymphoedema. Most reported cases have been associated with lymphoedema following mastectomy (1). The syndrome develops a mean of 10 years after mastectomy.

The underlying pathophysiology of Stewart-Treves syndrome is unknown. Lymphatic blockage may encourage neoplastic transformation due to local immunodeficiency, which could promote vascular oncogenesis (2). Radiotherapy does not seem to be directly involved in the pathogenesis of Stewart-Treves syndrome; however, the practice of axillary irradiation increases the risk of post-treatment lymphoedema.

Clinically, in the area of the chronic lymphoedema, the initial lesion includes a palpable subcutaneous mass. Multiple violaceous macules or nodules subsequently develop, with surrounding satellite lesions. Finally, extensive cutaneous nodules and metastatic disease develop (3).

Histologically, Stewart-Treves syndrome displays networks of proliferating vascular channels that dissect the dermal collagen. The overlying epidermis may be hyper-

keratotic and acanthotic or atrophic. Immunohistochemistry is necessary to establish the diagnosis. Antibodies against endothelial cells are the stain of choice (4). Angiosarcomas can typically express CD31, CD34, D2-40 and ERG.

Chemotherapy and radiation therapy for locally advanced tumours or metastatic forms do not significantly improve overall survival. Early amputation or wide local excision offers the best chance for long-term survival (5).

This case illustrates the importance of follow-up for all post-mastectomy lymphoedema. Physicians must be aware of this rare syndrome and perform skin biopsy of every suspicious lesion. Early diagnosis and treatment have crucial prognostic value.

REFERENCES

1. Cozen W, Bernstein L, Wang F, Press MF, Mack TM. The risk of angiosarcoma following primary breast cancer. *Br J Cancer* 1999; 81: 532–536.
2. Ruocco V, Schwartz RA, Ruocco E. Lymphedema: an immunologically vulnerable site for development of neoplasms. *J Am Acad Dermatol* 2002; 47: 124–127.
3. Sharma A, Schwartz RA. Stewart-Treves syndrome: pathogenesis and management. *J Am Acad Dermatol* 2012; 67: 1342–1348.
4. Tomita K, Yokogawa A, Oda Y, Terahata S. Lymphangiosarcoma in postmastectomy lymphedema (Stewart-Treves syndrome): ultrastructural and immunohistologic characteristics. *J Surg Oncol* 2006; 38: 275–282.
5. Berebichez-Fridman R, Deutsch YE, Joyal TM, Olvera PM, Benedetto PW, Rosenberg AE, et al. Stewart-Treves syndrome: a case report and review of the literature. *Case Rep Oncol* 2016; 9: 205–211.