



**HAL**  
open science

## Search for RASA1 Variants in Capillary Malformations of the Legs in 113 Children: Results from the French National Paediatric Cohort CONAPE

Annabel Maruani, Marine Durieux-Verde, Juliette Mazereeuw-Hautier, Olivia Boccara, Ludovic Martin, Christine Chiaverini, Catherine Eschard, Nathalie Beneton, Pierre Vabres, Xavier Balguerie, et al.

### ► To cite this version:

Annabel Maruani, Marine Durieux-Verde, Juliette Mazereeuw-Hautier, Olivia Boccara, Ludovic Martin, et al.. Search for RASA1 Variants in Capillary Malformations of the Legs in 113 Children: Results from the French National Paediatric Cohort CONAPE. *Acta Dermato-Venereologica*, 2018, 98 (2), pp.251-255. 10.2340/00015555-2835 . hal-02621329

**HAL Id: hal-02621329**

**<https://hal.inrae.fr/hal-02621329v1>**

Submitted on 26 May 2020

**HAL** is a multi-disciplinary open access archive for the deposit and dissemination of scientific research documents, whether they are published or not. The documents may come from teaching and research institutions in France or abroad, or from public or private research centers.

L'archive ouverte pluridisciplinaire **HAL**, est destinée au dépôt et à la diffusion de documents scientifiques de niveau recherche, publiés ou non, émanant des établissements d'enseignement et de recherche français ou étrangers, des laboratoires publics ou privés.



Distributed under a Creative Commons Attribution - NonCommercial 4.0 International License

# Search for *RASA1* Variants in Capillary Malformations of the Legs in 113 Children: Results from the French National Paediatric Cohort CONAPE

Annabel MARUANI<sup>1-3#</sup>, Marine DURIEUX-VERDE<sup>1,2#</sup>, Juliette MAZEREEUW-HAUTIER<sup>4</sup>, Olivia BOCCARA<sup>5</sup>, Ludovic MARTIN<sup>6</sup>, Christine CHIAVERINI<sup>7</sup>, Catherine ESCHARD<sup>8</sup>, Nathalie BENETON<sup>9</sup>, Pierre VABRES<sup>10</sup>, Xavier BALGUERIE<sup>11</sup>, Patrice PLANTIN<sup>12</sup>, Didier BESSIS<sup>13</sup>, Sébastien BARBAROT<sup>14</sup>, Ali DADBAN<sup>15</sup>, Catherine DROITCOURT<sup>16</sup>, Aline BERTHELOT<sup>17</sup>, Gérard LORETTE<sup>1,2</sup>, Sophie LEDUCQ<sup>1,2</sup>, Mahtab SAMIMI<sup>1,2</sup>, Christian ANDRES<sup>1,17</sup>, Agnès CAILLE<sup>1,3</sup>, Patrick VOUREC<sup>1,17</sup>; and Groupe de Recherche de la Société Française de Dermatologie Pédiatrique

<sup>1</sup>University François Rabelais Tours, <sup>2</sup>CHRU Tours, Department of Dermatology, <sup>3</sup>CHRU Tours, Clinical Investigation Center-INSERM 1415, Tours, <sup>4</sup>Department of Dermatology, University Hospital Center of Toulouse, Toulouse, <sup>5</sup>Department of Dermatology and Reference Center for Genodermatoses and Rare Skin Diseases (MAGEC), University Hospital Necker-Enfants Malades, Paris, Departments of Dermatology, <sup>6</sup>University Hospital Center of Angers, Angers, <sup>7</sup>University Hospital Center of Nice, Nice, <sup>8</sup>University Hospital Center of Reims, Reims, <sup>9</sup>Hospital Center of le Mans, le Mans, <sup>10</sup>University Hospital Center of Dijon, Dijon, <sup>11</sup>University Hospital Center of Rouen, Rouen, <sup>12</sup>Hospital Center of Quimper, Quimper, <sup>13</sup>University Hospital Center of Montpellier, Montpellier, <sup>14</sup>University Hospital Center of Nantes, Nantes, <sup>15</sup>University Hospital Center of Amiens, Amiens, <sup>16</sup>University Hospital Center of Rennes, Rennes, and <sup>17</sup>INSERM U930, CHRU Tours, Laboratory of Biochemistry and Molecular Biology, Tours, France

#These authors contributed equally and should be considered as first authors.

**Patients with an inherited autosomal-dominant disorder, capillary malformation–arteriovenous malformation (CM-AVM), frequently have mutations in Ras P21 protein activator 1 (*RASA1*). The aims of this study were to determine the prevalence of germline *RASA1* variants in a French multicentre national cohort of children, age range 2–12 years, with sporadic occurrence of capillary malformation (CM) of the legs, whatever the associated abnormalities, and to identify genotype–phenotype correlates. DNA was extracted from leukocytes in blood samples, purified and amplified, and all exons of the *RASA1* gene were analysed. Among 113 children analysed, 7 had heterozygous variants (6.1%). Four different variants were identified; 2 were new. In children with *RASA1* variants, CMs were more frequently bilateral and multifocal. In conclusion, *RASA1* variants are rarely found in children with sporadic CM of lower limbs without CM-AVM syndrome. CMs in this study were heterogeneous, and no disease-causing relationship could be proven.**

**Key words:** *RASA1*; mutations; variants; polymorphism; capillary malformations; vascular anomalies.

Accepted Nov 2, 2017; Epub ahead of print Nov 7, 2017

Acta Derm Venereol 2018; 98: 251–255.

**Corr:** Annabel Maruani, CHRU Tours, Hospital Trousseau, Department of Dermatology, Avenue de la République, FR-37044, Tours Cedex 9, France. E-mail: annabel.maruani@univ-tours.fr

Our knowledge of the genetic causes of vascular malformations has increased considerably in recent years. In capillary malformations (CMs), post-zygotic activating mutations of G protein subunits alpha Q (*GNAQ*) and alpha 11 (*GNAI1*) have been found in affected skin of patients with facial port-wine stains in Sturge-Weber syndrome or phacomatosis pigmentovascularis (1, 2). Post-zygotic activating phosphatidylinositol-4,5-bisphosphate 3 catalytic (*PIK3CA*) mutations also account for a

number of capillary/lymphatic malformations as part of the CLOVES and macrocephaly-CM syndromes (3, 4). Cutaneous CMs might be associated with germline mutations in the Ras P21 protein activator 1 gene (*RASA1*) as part of the autosomal dominant syndrome, capillary malformation-arteriovenous malformation (CM-AVM) (5, 6).

CM-AVM syndrome was initially described as a combination of very suggestive and typical multifocal cutaneous CMs (small, round CMs, with pale halos), associated with high-flow superficial lesions, arteriovenous fistulas (AVFs) or cerebral AVMs (6). However, mutations in *RASA1* have been reported in 3 families of patients with CM, but without AVM (7). Similarly, Wooderchak-Donahue reported *RASA1* mutations associated with hereditary CM, with or without AVF or AVM in 8 subjects (8). In sporadic cases, germline *RASA1* mutations have been identified in the peripheral blood of 1 patient with Sturge-Weber syndrome (9).

*RASA1* mutations were found to be responsible for aberrant lymphatic architecture and functional abnormalities other than CM in mice and humans (10). *RASA1* encodes the 120-RasGAP protein involved in the RAS-MAPK signalling pathway that controls proliferation, migration, and survival of various cell types, including vascular endothelial cells. The P120-RasGAP protein converts active GTP-bound Ras into inactive GDP-bound Ras and has been involved in vascular development in *RASA1*<sup>-/-</sup> mice (11). Loss of function mutations in *RASA1* in humans are associated with abnormal angiogenic remodelling of the primary capillary plexus, with vascular anomalies, not compensated by other RasGAPs, such as *RASA2*, *RASAL*, or *NF1* (6, 12).

Since 2010 we have implemented a multicentre national cohort (CONAPE) from 14 French tertiary centres of paediatric dermatology specialized in vascular anomalies, including 120 children aged 2–12 years with CMs

of the legs. CMs are either simple, combined (associated with a venous, arterial and/or lymphatic abnormal component), or associated with other anomalies, as defined in the updated classification of vascular anomalies (13).

The aim of this study was to assess the prevalence of *RASAI* variants in children with CM of the legs from this cohort, and to identify genotype-phenotype correlates.

## METHODS

### Study design and setting

Data were obtained from a multicentre French national cohort including 120 children with CM of the legs in 14 French hospitals (Departments of Dermatology from Amiens, Angers, Dijon, Le Mans, Montpellier, Nantes, Nice, Paris-Necker, Quimper, Reims, Rennes, Rouen, Toulouse, Tours). The recruitment period ranged from 10 November 2010 to 8 January 2015.

### Participants

Eligibility criteria were age 2–12 years with congenital CM of at least 1 lower limb, regardless of the size and type of CM and associated anomalies.

### Ethical aspects

Both parents gave their informed consent for children to participate in the study. The protocol was approved by the institutional review board of the University Hospital Center of Tours (#2010-R22).

### Collected data

At baseline, dermatologists collected data on demographics (age, sex), anatomical measurements, personal and familial medical history, clinical description of the CM (location, features such as extension, and demarcation; sharply demarcated CMs were called “geographic”) (14, 15). They collected data on general complications, lymphatic complications (lymphedema, lymphangiectasia) or venous complications (functional signs, varicose or dilated veins, leg ulcer). Additional collected data was leg hypertrophy (discrepancy of leg length and/or of girth (difference  $\geq 15$  mm), measured by tape, considered significant for both)) (16, 17).

### Blood samples and genetic analyses

Blood samples (5 ml) were collected from 113 of 120 children from the cohort, after obtaining signed consent for genetic analyses from both parents. DNA analysis was centralized in the laboratory of the Biochemistry and Molecular Biology Department of the University Hospital of Tours. Sanger sequencing was performed on DNA extracted from blood and purified by using a Qiasymphony SP system (Qiagen), then amplified by PCR with primers designed with Primer 3 software (Table S1<sup>1</sup>). PCR was carried out in a volume of 20  $\mu$ l, consisting of 50 ng genomic DNA, 0.15 mM of each of the 4 deoxyribonucleotides, 0.5  $\mu$ M of each of the forward and reverse primers, 1X Green GoTaq Flexi Buffer (Promega Corp., Madison, WI, USA), 1.5 mM MgCl<sub>2</sub>, and 1 unit of GoTaqG2 Flexi DNA Polymerase (Promega Corp.). PCR products were sequenced in both directions with Big Dye Terminator Kit (Applied Biosystems, Foster City, CA, USA) and analysed with an ABI Prism 3130 XI Genetic Analyser (Applied Biosystems).

Investigators blinded to the patient’s clinical status (PV, AB) analysed sequences using Seqscape software (Applied Biosystems).

### Outcomes

The primary outcome was prevalence of *RASAI* variants in children with CM of the legs. In addition, the clinical phenotype of patients with a *RASAI* polymorphism was described, to eventually identify correlated specific clinical signs.

### Statistical analyses

Continuous variables are expressed as mean  $\pm$  standard deviation (SD) and qualitative variables are reported with number (%). Fisher’s exact test was used to compare *RASAI* mutations in the cohort and the general population using the Exome Variant Server (EVS) database;  $p < 0.01$  was considered significant. To compare the characteristics between children with or without mutation, Wilcoxon rank sum tests were used for continuous variables and Fisher’s exact tests for categorical variables.

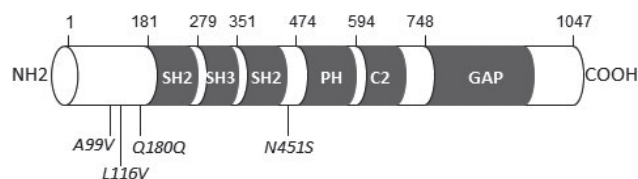
## RESULTS

### Demographic and clinical characteristics of children

A total of 113 children were analysed for *RASAI* mutations. The mean age was  $5.7 \pm 3.1$  years, and 60 (53.1%) were male (Table I). Sixteen of the 113 patients (14.2%) had bilateral CM of the legs, and the mean body surface area of CM was  $13.1 \pm 18.3\%$ . All CMs were port-wine stains (there were no cutis marmorata telangiectatica congenita, salmon patches or telangiectasia) (13); 51 patients (45.5%) had a CM of the geographic type; 32 patients (28.6%) had multi-site CMs. Venous and lymphatic abnormalities were associated in 36 (31.9%) and 11 cases (9.7%). Twelve patients (12.8%) had discrepancy in leg length and 20 (21.3%) in leg circumference.

### Description of *RASAI* polymorphism

Among the 113 children studied, 7 harboured heterozygous *RASAI* variants (6.1%); with missense substitutions and an intronic substitution (Fig. 1, Tables I and II). None had personal medical history, morphological abnormalities, malformation syndromes, general complications, tumour development or AVM. No first-degree family history of CM was present, and none had CMs with features of those found in CM-AVM syndrome (small CMs surrounded by halo) (18).



**Fig. 1. Schematic structure of the protein 120 Ras-GAP (Prosite profiles) with localization of the identified mutations (in *italic*).** Protein domains are represented by grey boxes. SH: Src Homology domain; PH: Pleckstrin homology domain; C2: calcium-dependant phospholipid-binding domain; GAP: GTPase activating domain.

<sup>1</sup><https://www.medicaljournals.se/acta/content/abstract/10.2340/00015555-2835>

**Table I. Baseline characteristics of 113 children with capillary malformations (CM) of the legs without and with genetic RASA1 variant**

Variable	All patients n = 113 (%)	Without variants n = 106 (%)	With variants n = 7 (%)	p-value
Age, years, mean±SD	5.7±3.1	5.8±3.1	4.3±2.8	0.24
Sex – male	60 (53.1)	56 (52.8)	4 (57.1)	1
Family history of CM, n (%)	12 (11.0)	12 (11.8)	0	1
Family history of AVM, n (%)	2 (1.8)	1 (1.0)	1 (14.3)	0.12
Weight, mean±SD	22.2±10.2	22.4±10.4	18.2±7.5	0.24
Height, mean±SD	113.0±19.9	113.5±19.9	106.1±20.3	0.37
Head circumference, mean±SD	51.3±3.3	51.6±2.8	46.6±6.6	0.01
CM, Affected side – right, n (%)	42 (37.2)	41 (38.7)	1 (14.3)	
CM, Affected side – left, n (%)	55 (48.7)	51 (48.1)	4 (57.1)	
CM, Affected side – bilateral, n (%)	16 (14.2)	14 (13.2)	2 (28.6)	0.25
CM extended to other sites, n (%)	32 (28.6)	28 (26.7)	4 (57.1)	0.10
Increased heat on the affected vs. contralateral limb, n (%)	18 (18.6)	17 (18.5)	1 (20.0)	1
Pulsatility (on palpation), n (%)	0	0	0	–
Geographic type, n (%)	51 (45.5)	46 (43.8)	5 (71.4)	0.24
Percentage extension of body surface, mean±SD	13.1±18.3	12.9±18.6	16.4±12.4	0.14
Venous anomalies, n (%)	36 (31.9)	35 (33.0)	1 (14.3)	0.43
Varicose dilatations	31 (86.1)	30 (85.7)	1 (100.0)	
Leg ulcers	1 (2.9)	1 (3.0)	0	
Lymphatic abnormalities, n (%)	11 (9.7)	10 (9.4)	1 (14.3)	0.52
Lymphatic malformations or lymphedema	7 (63.6)	6 (60.0)	1 (100.0)	
Lymphangiectasia	6 (66.7)	6 (75.0)	0	
Bleeding events, n (%)	1 (0.9)	1 (0.9)	0	1
Thromboembolic events, n (%)	1 (0.9)	1 (0.9)	0	1
Clinical discrepancy in length of legs ≥15 mm, n (%)	18 (16.5)	16 (15.7)	2 (28.6)	0.33
Clinical discrepancy in circumference of legs ≥15 mm, n (%)	33 (30.3)	29 (28.4)	4 (57.1)	0.20

AVM: arteriovenous malformation; SD: standard deviation.

Four patients carried a heterozygous p.A99V variant located in the N-terminal domain (rs111840875 [c.296c>t]). Thus, allelic frequency in our cohort was 0.018. This variant was previously recorded in the European-American population (allelic frequency 0.029). It is predicted to be neutral (score –0.342) by *in silico* prediction tools PROVEAN and benign (score 0.334) by Polyphen-2. The age of these 4 children was 28 months (Fig. 2a), 33 months (Fig. 2b), 35 months and 9 years (Fig. 2c). CM was unilateral for all 4 patients and extended to the whole limb for 3. The proportion of the body surface area affected by CM ranged from 7% to 40%. No CM had a geographic pattern. No case showed venous or lymphatic complications. For one patient, the lower limb with CM was hypertrophic (circumference +25 mm compared with the other limb), with no discrepancy in leg lengths. For another patient, the circumference was lower for the limb with CM than the contralateral limb (–20 mm), with no discrepancy in limb length.

**Table II. Allelic frequencies of the RASA1 mutations identified in the cohort**

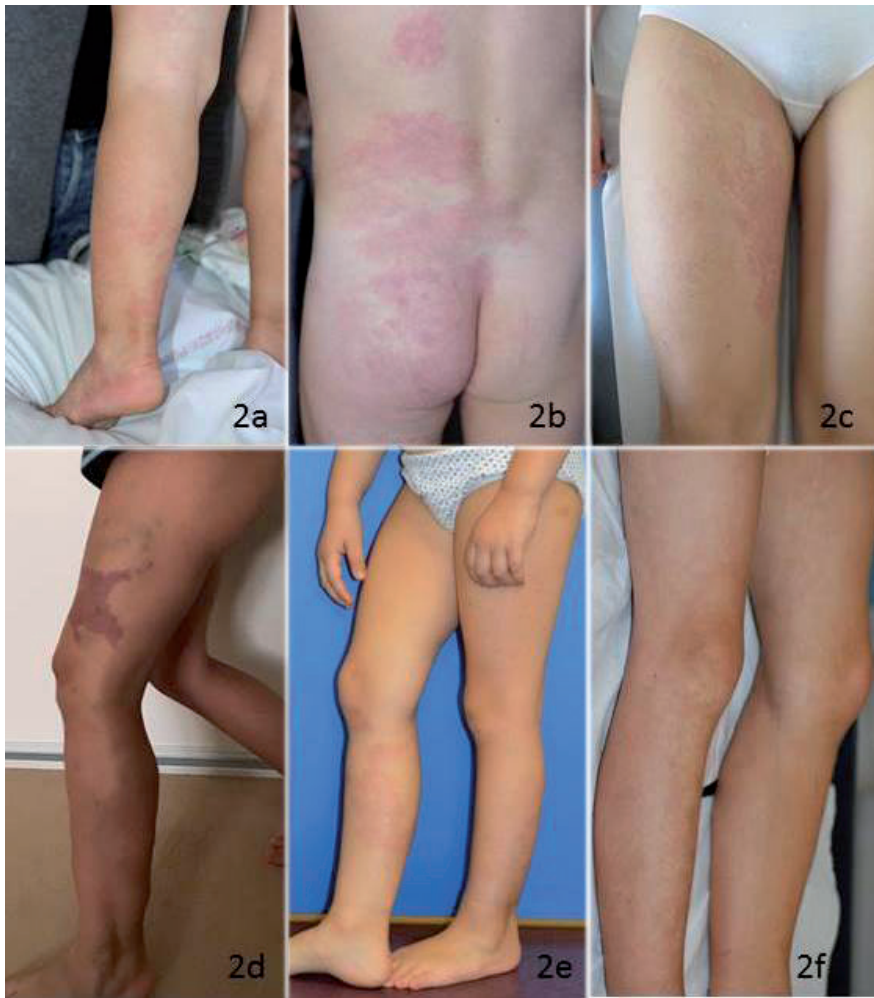dbSNP	Nucleotide change	Amino acid change	Alleles	Alleles (patients)	Alleles (controls)	p-value
rs111840875	c.296c>t	p.A99V	C	222	8354	0.11 0.07
			T	4	246	
rs149246093	c.346c>g	p.L116V	C	225	8598	
			G	1	2	
Unknown	c. 539+1g>a	ND	G	225	ND	
			A	1		
rs529871259	c.1352a>g	p.N451S	A	225	ND	
			G	1		

Nucleotide and protein numbers refer to NM\_002890.2 sequence. Allelic frequencies in a control population (European-American) were obtained from the Exome Variant Server (<http://evs.gs.washington.edu/EVS/>).

A p.L116V variant was identified in one patient. It was considered non-pathogenic by PROVEAN and Polyphen-2 analysis. This missense variant rs149246093 (c.346c>g) was reported as very rare variant in the European-American population (0.00023). The patient was a 4-year-old girl, with a unilateral geographic-type, warm CM located on the thigh, leg and foot, spreading over 2% of the body surface, and associated with a macrocystic lymphatic malformation of the buttock. The limb affected by CM was hypertrophic, with a slight discrepancy in leg length (+12 mm), and dilated superficial veins (Fig. 2d).

A novel variant, c.539+1g>a was identified in a 31-month-old-girl. This variant is located within the donor site for splicing of intron 1. The child had bilateral asymmetric CMs, spreading over 21% of the body surface on the thighs and legs (Fig. 2e). On her right leg she had a geographic-type CM, and on the contralateral leg, a small CM on her leg and a round CM on her thigh. There was no discrepancy in the leg lengths or other abnormalities.

Finally, a variant p.N451S, located close to the Pleckstrin homology domain in the RASA1 protein was identified in a 7-year-old boy. This variation was considered non-pathogenic by PROVEAN and Polyphen-2 analysis. This missense variant, rs529871259 (c.1352a>g), was never described in the European-American population EVS, but was reported in the African population with very rare frequency (0.002). The child had CMs located on both legs, spreading over 10% of the body surface (Fig. 2f). The legs had discrepant lengths (+20 mm) but similar circumferences. The patient also had lymphedema on both feet.



**Fig. 2. Examples of clinical characteristics.** (a) A 28-month-old boy with widespread capillary malformations (CM) of the left leg (variant p.A99V). (b) A 33-month-old boy, showing CM extending to the back (variant p.A99V). (c) A 9-year-old girl, with CM of her right thigh (variant p.A99V). (d) A 4-year-old girl, showing a geographic-type CM of her left thigh associated with dilated veins and macrocystic lymphatic malformation of her left buttock (variant p.L116V). (e) A 31-month-old girl with bilateral CMs on legs (intronic variant). (f) A 7-year-old boy showing widespread bilateral CMs (variant p.N451S).

## DISCUSSION

This is the first study of the *RASA1* gene in a population of children with CM of the legs. Among the 113 children analysed for all exons of the *RASA1* gene, 7 had a heterozygous variant. All were considered non-pathogenic based on our analysis, although this was questionable for the variant N451S and for an intronic variant in intron 1.

Four children in our cohort harboured the missense variant c.296c>t, p.A99V. This variant was originally classified as a variant of uncertain significance, which was later changed to benign, as it is found in 2.9% of the European-American general population EVS. This variant was first reported by Wooderchak-Donahue et al. (8) in a patient with multifocal CMs on the head, face and chest with AVM. It was considered benign, since this patient also had another pathogenic stop codon mutation.

We observed a novel variant c. 539+1g>a at the beginning of intron 1 of *RASA1*, in the donor site for splicing. This variant may affect the splicing of *RASA1* pre-mRNA as suggested by *in silico* analysis using MaxEntScan (MES; Markov model). We next searched for an impact of this variant by analysing the expression of *RASA1* in RNA extracted from blood of the girl carrying the variant. We did not observe an alternative transcript by RT-PCR (data not shown). Further studies, particularly on other tissues, could be of interest.

The mutation c.1352a>g (p.N451S) was considered non-pathogenic by PROVEAN and Polyphen-2 analysis, but it is a very rare variant that was never described in the European-American population EVS, and only reported in the African population with a very rare frequency (0.002). Moreover, it is located in exon 10, where several mutations were previously associated with CM-AVM (5, 19). Further studies including protein functional tests could be interesting to attest the pathogenicity of the variant.

We did not observe missense mutations or frameshift mutations causing a premature stop codon in our study, as previously reported (6, 8, 19). The rate of *RASA1*

variants is lower in our cohort of children with CM on the legs than in populations with multifocal CMs: 29% and 78% in studies reported by Wooderchak-Donahue and Revencu, respectively, but those included patients with or without other vascular malformations (8, 19). Also, another study of 13 patients considered to have Klippel-Trenaunay syndrome and 17 with single CM associated with an overgrown limb found no germinal *RASA1* mutations (20).

In our cohort, bilaterality of the CM tended to be more frequent (28.6% vs. 13.2%), affected the mean total percentage extension of CM to the body more (16.4% vs. 13%) and extended more often to other sites (57.1% vs. 26.7%) in children with than without *RASA1* variants, although not significantly. No children with *RASA1* variants had AVM or small round CMs with surrounding halo typical of those in CM-AVM syndrome. In previous reports on patients with CM and *RASA1* mutations,

most multifocal and bilateral CMs were associated with CM-AVM syndrome. Multifocal CMs without AVM could also be associated with *RASA1* variants, but CM were more frequently patchy CMs than widespread CM extending to other sites, as observed in patients with our variants (7, 8, 20). We hypothesize that identification of a germline variation in *RASA1* may favour bilateral CM compared with post-zygotic mutations that may lead to unilateral segmental CM (1). Overgrowth syndrome, described in several cases of CMs with somatic mutations of *PIK3CA3* (3), did not appear to be more frequent in our patients with than without *RASA1* variants.

This study has a number of limitations. First, the sample size of children with *RASA1* variants was too small to confirm the clinical differences with children and without variants. Secondly, the study would have been strengthened if clinical characteristics of CMs were more precisely classified (15). Thirdly, genetic analyses were performed on blood samples and yield would have possibly be higher with lesional tissue analysis. Also, we focused our search on germline mutations of the *RASA1* gene; 1 case of CM-AVM with mutation on *EBH4* has been reported recently (21). Finally, the conditions involving CMs were heterogeneous, and no disease-causing relationship could be proven in these cases.

In conclusion, variants of *RASA1* are rarely found with CM of the legs without associated CM-AVM syndrome. We found no clinical phenotype associated to germline *RASA1* mutation. However, mutations in the promoter of *RASA1* could be investigated in patients with CM. Similarly, deletions or duplications of particular exons or the entire *RASA1* gene could be investigated. Use of comparative genetic hybridization array or next-generation sequencing studies of cohorts of patients with CM could lead to more discovery of *RASA1* mutations in this population.

## ACKNOWLEDGEMENTS

The authors are indebted to Mrs A. Darmaillacq, from CHRU Tours, and Mrs M. Carriot, CIC Tours, France, for their technical help.

ClinicalTrials.gov registration: NCT01364857.

**Funding sources:** the study was funded by the French Ministry of Social Affairs and Health (French National Program of Clinical Research (PHRC-N), 2009)

*The authors have no conflicts of interest to declare.*

## REFERENCES

- Shirley MD, Pevsner J. Sturge-Weber syndrome and port-wine stains caused by somatic mutation in GNAQ. *N Engl J Med* 2013; 368: 1971–1979.
- Thomas AC, Zeng Z, Rivière JB, O’Shaughnessy R, Al-Olabi L, St-Onge J, et al. Mosaic activating mutations in GNA11 and GNAQ are associated with phakomatosis pigmentovascularis and extensive dermal melanocytosis. *J Invest Dermatol* 2016; 136: 770–778.
- Keppler-Noreuil KM, Rios JJ, Parker VER, Semple RK, Lindhurst MJ, Sapp JC, et al. PIK3CA-Related Overgrowth Spectrum (PROS): diagnostic and testing eligibility criteria, differential diagnosis, and evaluation. *Am J Med Genet A* 2015; 167A: 287–295.
- Rivière JB, Mirzaa GM, O’Roak BJ, Beddaoui M, Alcantara D, Conway RL, et al. De novo germline and postzygotic mutations in AKT3, PIK3R2 and PIK3CA cause a spectrum of related megalencephaly syndromes. *Nat Genet* 2012; 44: 934–940.
- Revenu N, Vikkula M. RASA1 mutations and associated phenotypes in 68 families with capillary malformation-arteriovenous malformation. *Hum Mutat* 2013; 34: 1632–1641.
- Eerola I, Vikkula M. Capillary malformation-arteriovenous malformation, a new clinical and genetic disorder caused by RASA1 mutations. *Am J Hum Genet* 2003; 73: 1240–1249.
- Hershkovitz D, Lapidot M. RASA1 mutations may cause hereditary capillary malformations without arteriovenous malformations. *Br J Dermatol* 2008; 158: 1035–1040.
- Wooderchak-Donahue W, Stevenson DA, McDonald J, Grimmer JF, Gedge F, Bayrak-Toydemir P. RASA1 analysis: clinical and molecular findings in a series of consecutive cases. *Eur J Med Genet* 2012; 55: 91–95.
- Zhou Q, Qin ZP. Detection of RASA1 mutations in patients with sporadic Sturge-Weber syndrome. *Childs Nerv Syst* 2011; 27: 603–607.
- Burrows PE, Sevic-Muraca EM. Lymphatic abnormalities are associated with RASA1 gene mutations in mouse and man. *Proc Natl Acad Sci USA* 2013; 110: 8621–8626.
- Henkemeyer M, Rossi DJ, Holmyard DP, Puri MC, Mbamalu G, Harpal K, et al. Vascular system defects and neuronal apoptosis in mice lacking ras GTPase-activating protein. *Nature* 1995; 377: 695–701.
- Boon LM, Vikkula M. RASA1: variable phenotype with capillary and arteriovenous malformations. *Curr Opin Genet Dev* 2005; 15: 265–269.
- Wassef M, Vikkula M. Vascular anomalies classification: recommendations from the International Society for the Study of Vascular Anomalies. *Pediatrics* 2015; 136: 203–214.
- Maari C, Frieden IJ. Klippel-Trenaunay syndrome: the importance of “geographic stains” in identifying lymphatic disease and risk of complications. *J Am Acad Dermatol* 2004; 51: 391–398.
- Rozas-Muñoz E, Frieden IJ, Roé E, Puig L, Baselga E. Vascular stains: proposal for a clinical classification to improve diagnosis and management. *Pediatr Dermatol* 2016; 33: 570–584.
- Samimi M, Maruani A, Bertrand P, Arbeille P, Lorette G. Arterial blood flow in limbs with port-wine stains can predict length discrepancy. *Br J Dermatol* 2009; 160: 219–220.
- Kim YW, Lee SH, Kim DI, Do YS, Lee BB. Risk factors for leg length discrepancy in patients with congenital vascular malformation. *J Vasc Surg* 2006; 44: 545–553.
- Gandon C, Bonniaud B, Collet E, Dalac S, Jeudy G, Vabres P. A Typical vascular and pigmentary dermoscopic pattern of capillary malformations in capillary malformation-arteriovenous malformation syndrome: report of four cases. *Pediatr Dermatol* 2016; 33: e337–341.
- Revenu N, Boon LM, Mulliken JB, Enjolras O, Cordisco MR, Burrows PE, et al. Parkes Weber syndrome, vein of Galen aneurysmal malformation, and other fast-flow vascular anomalies are caused by RASA1 mutations. *Hum Mutat* 2008; 29: 959–965.
- Revenu N, Boon LM, Domp Martin A, Rieu P, Busch WL, Dubois J, et al. Germline mutations in RASA1 are not found in patients with Klippel-Trenaunay syndrome or capillary malformation with limb overgrowth. *Mol Syndromol* 2013; 4: 173–178.
- Yu J, Streicher JL, Medne L, Krantz ID, Yan AC. EPHB4 mutation implicated in capillary malformation-arteriovenous malformation syndrome: a case report. *Pediatr Dermatol* 2017; 34: e227–e230.