



HAL
open science

Acute tetraplegia caused by Rat Bite Fever in snake keeper and transmission of *Streptobacillus moniliformis*

Tobias Eisenberg, Simon Poignant, Youenn Jouan, Ahmad Fawzy, Werner Nicklas, Christa Ewers, Laurent Mereghetti, Antoine Guillon

► To cite this version:

Tobias Eisenberg, Simon Poignant, Youenn Jouan, Ahmad Fawzy, Werner Nicklas, et al.. Acute tetraplegia caused by Rat Bite Fever in snake keeper and transmission of *Streptobacillus moniliformis*. *Emerging Infectious Diseases*, 2017, 23 (4), pp.719-721. 10.3201/eid2304.161987 . hal-02625170

HAL Id: hal-02625170

<https://hal.inrae.fr/hal-02625170>

Submitted on 26 May 2020

HAL is a multi-disciplinary open access archive for the deposit and dissemination of scientific research documents, whether they are published or not. The documents may come from teaching and research institutions in France or abroad, or from public or private research centers.

L'archive ouverte pluridisciplinaire **HAL**, est destinée au dépôt et à la diffusion de documents scientifiques de niveau recherche, publiés ou non, émanant des établissements d'enseignement et de recherche français ou étrangers, des laboratoires publics ou privés.



Distributed under a Creative Commons Attribution 4.0 International License

5. Lee DH, Torchetti MK, Winker K, Ip HS, Song CS, Swayne DE. Intercontinental spread of Asian-origin H5N8 to North America through Beringia by migratory birds. *J Virol*. 2015;89:6521–4. <http://dx.doi.org/10.1128/JVI.00728-15>
6. Gabriel G, Dauber B, Wolff T, Planz O, Klenk HD, Stech J. The viral polymerase mediates adaptation of an avian influenza virus to a mammalian host. *Proc Natl Acad Sci U S A*. 2005;102:18590–5. <http://dx.doi.org/10.1073/pnas.0507415102>
7. Lee D-H, Sharshov K, Swayne DE, Kurskaya O, Sobolev I, Kabilov M, et al. Novel reassortant clade 2.3.4.4 highly pathogenic avian influenza A(H5N8) virus in wild aquatic birds, Russia, 2016. *Emerg Infect Dis*. 2017 Feb 15 [Epub ahead of print]. <https://dx.doi.org/10.3201/eid2302.161252>
8. Florin BM. Uvs Nuur, Lake. In: Robert W. H. ed. *Biomes and Ecosystems*. Vol. 4. Amenia (NY): Salem Press; 2013. p. 1260–1.
9. Chen H, Smith GJ, Zhang SY, Qin K, Wang J, Li KS, et al. Avian flu: H5N1 virus outbreak in migratory waterfowl. *Nature*. 2005;436:191–2. <http://dx.doi.org/10.1038/nature03974>
10. United Nations Food and Agriculture Organization. H5N8 highly pathogenic avian influenza (HPAI) of clade 2.3.4.4 detected through surveillance of wild migratory birds in the Tyva Republic, the Russian Federation—potential for international spread [cited 2016 Dec 3]. <http://www.fao.org/3/a-i6113e.pdf>

Address for correspondence: Chakradhar Tosh, ICAR-National Institute of High Security Animal Diseases, Anand Nagar, Bhopal 462022, India; email: chakradhar.tosh@icar.gov.in

Acute Tetraplegia Caused by Rat Bite Fever in Snake Keeper and Transmission of *Streptobacillus moniliformis*

Tobias Eisenberg,¹ Simon Poignant,¹ Youenn Jouan, Ahmad Fawzy, Werner Nicklas, Christa Ewers, Laurent Mereghetti, Antoine Guillon

Author affiliations: Hessian State Laboratory, Giessen, Germany (T. Eisenberg, A. Fawzy); Centre Hospitalier Universitaire de Tours, Tours, France (S. Poignant, Y. Jouan, L. Mereghetti, A. Guillon); Université François Rabelais, Tours (S. Poignant, Y. Jouan, L. Mereghetti, A. Guillon); Cairo University, Giza, Egypt (A. Fawzy); Justus-Liebig-University, Giessen (A. Fawzy, C. Ewers); German Cancer Research Center, Heidelberg, Germany (W. Nicklas)

DOI: <http://dx.doi.org/10.3201/eid2304.161987>

We report acute tetraplegia caused by rat bite fever in a 59-year old man (snake keeper) and transmission of *Streptobacillus moniliformis*. We found an identical characteristic

¹These authors contributed equally to this article.

bacterial pattern in rat and human samples, which validated genotyping-based evidence for infection with the same strain, and identified diagnostic difficulties concerning infection with this microorganism.

Human infections by *Streptobacillus moniliformis* are assumed to be caused by rats on the basis of epidemiologic information. We provide genotyping-based evidence for infection with the same bacterial strain in rat and human samples and highlight diagnostic difficulties concerning this microorganism and its potential for life-threatening consequences.

A 59-year-old man was admitted to Centre Hospitalier Universitaire de Tours (Tours, France) because he was unable to stand and had acute progressive onset of dyspnea and a 15-day history of fever and arthralgia (left knee, right wrist) but no signs of rash. He was sedated, mechanically ventilated, and admitted to the intensive care unit. The patient had a temperature of 39°C, a pulse rate of 63 beats/min, and a blood pressure of 126/68 mm Hg.

After discontinuation of sedation, physical examination showed cervical pain, flaccid tetraplegia, and sensitivity at the T4 level. His knees and left wrist were swollen and had joint effusions. There was little available information for the patient because he could not speak and had no known social contacts. Blood tests showed an increased leukocyte count (15×10^9 cells/L), predominantly neutrophils, and an increased C-reactive protein level (125 mg/L).

The patient was given antimicrobial drugs (amoxicillin and cloxacillin) after blood and synovia (knee) sampling. Cervical magnetic resonance imaging showed C5–T1 vertebral osteomyelitis and an epidural abscess with consecutive compression of the spinal cord (C5–T1) (Figure). Surgical spinal decompression and vertebral stabilization were not attempted because of extensiveness of injury and flaccid tetraplegia. Transthoracic and transesophageal echocardiograms showed no features of endocarditis. Blood cultures showed negative results. Joint effusions contained a culture-negative inflammatory liquid and uric acid crystals. The patient was given a tracheotomy and continuously ventilated.

A final diagnosis was obtained by sequencing the 16S rRNA gene obtained directly from synovia. An 897-nt partial 16S rRNA sequence showed 99.0% identity with sequences of *S. moniliformis* (GenBank accession nos. JQ087393 and CP001779).

The patient was a snake keeper who bred rats for snake food. He reported snake bites but not rat bites. We sampled his snakes (*Boa constrictor* and *Elaphe* sp.) and 1 of his feeder rats (*Rattus norvegicus*) by obtaining swab and biopsy specimens from oral cavities of all animals. All cultures were polymicrobial. We used desorption/ionization time-of-flight mass spectrometry (Bruker Daltonique,

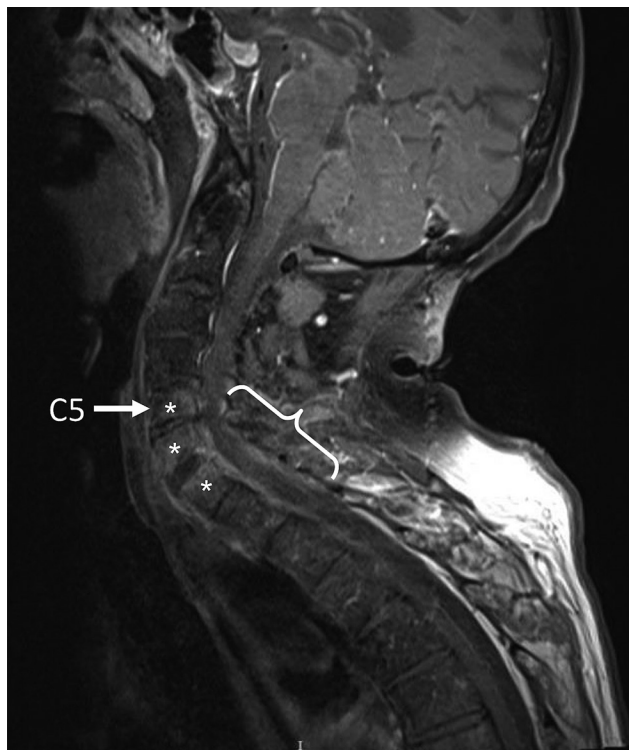


Figure. Fat-saturated, contrast-enhanced T1-weighted magnetic resonance image of the spine of a 59-year-old man (snake keeper) with rat bite fever. Sagittal view of the cervical spine shows spondylodiscitis (*) and an epidural abscess with C5–T1 compression (brace). Preexisting spinal degeneration was observed and was probably a promoting factor for spinal compression.

Wissembourg, France) to identify isolated bacteria but failed to identify *S. moniliformis*.

Synovia and serum samples from the patient and oral swab and biopsy specimens from animals were subjected to three 16S rRNA gene-based PCRs that were genus specific, rather than *S. moniliformis* specific (1). Synovia from the patient and 2 swab and 2 biopsy specimens from the same rat, but none of the oral samples from snakes, were positive. This result suggested rat bite fever. However, diagnosis of rat bite fever on the basis of partial 16S rRNA gene sequencing might be uncertain (1).

We tested the same samples by using *S. moniliformis*-specific multilocus variant analysis (MLVA) (2) to identify the bacterial transmission chain. Results were consistent with those for PCR and identified 2 MLVA genotypes of *S. moniliformis* in rat oral samples. Conversely, genomic information obtained for human synovia showed only 1 of these patterns, indicating a clonal relationship with 1 of the rat bacterial strains. Serum from the patient obtained on day 1 after hospitalization contained antibodies against *S. moniliformis* when tested by bead-based multiplex serologic analysis and indirect immunofluorescence.

Rat bite fever is an underdiagnosed worldwide zoonosis closely associated with bites of rats or close contact with them. Snakes that eat rats might serve, at least temporarily, as reservoirs for human infection. Thus, we attempted to detect the rat bite fever organism in oral and biopsy specimens from the patient's snakes by using different PCRs (including a quantitative PCR that has an analytical sensitivity of 10 DNA molecules). All results were negative.

Four studies reported rat bite fever associated with keeping reptiles, but definitive transmission could not be proven in these instances, in which infections seemed more likely to be introduced by feeder rats (3–6). Regular contact with prey rats might be a general risk factor, and being bitten by a snake shortly after it fed on a prey rat might have the same consequences as a rat bite. In our study, we identified and typed the involved clone by using a recently developed, species-specific, culture-independent MLVA scheme (<http://microbesgenotyping.i2bc.paris-saclay.fr/databases/public>).

We showed that a rat might be simultaneously colonized by >1 clone of *S. moniliformis* and demonstrated identical strains in the human patient and the reservoir host (online Technical Appendix Figure, <https://wwwnc.cdc.gov/EID/article/23/4/16-1987-Techapp1.pdf>). The infectious genotype has been designated as LHL18 on the basis of the novel allele combination 17-3-16.

We demonstrated the presence of an identical characteristic *S. moniliformis* bacterial pattern in rat and human samples, which validated genotyping-based evidence for infection with the same strain. Our case highlights diagnostic difficulties concerning this microorganism and supports tropism of this bacteria for synovial tissue and its potential for life-threatening consequences.

Acknowledgments

We thank the patient for providing written permission to publish this report; Kathkeen Gaillot and Isabelle Griffoul for help in interpreting magnetic resonance imaging results; and Chrystophe Aubert and Elodie Theyssandier for handling snakes.

S.P., Y.J., and A.G. provided care for the patient; T.E., A.F., W.N., C.E., and L.M. performed the microbiological analyses; and T.E., S.P., and A.G. wrote the report.

Dr. Eisenberg is a veterinary specialist in microbiology and team supervisor of the bacteriology department, Hessian State Laboratory, Giessen, Germany. His primary research interests are rat bite fever, other infectious diseases in zoo animals and wildlife, and zoonoses.

References

1. Eisenberg T, Ewers C, Rau J, Akimkin V, Nicklas W. Approved and novel strategies in diagnostics of rat bite fever and other *Streptobacillus* infections in humans and animals. *Virulence*. 2016;7:630–48. <http://dx.doi.org/10.1080/21505594.2016.1177694>

2. Eisenberg T, Fawzy A, Nicklas W, Semmler T, Ewers C. Phylogenetic and comparative genomics of the family *Leptotrichiaceae* and introduction of a novel fingerprinting MLVA for *Streptobacillus moniliformis*. *BMC Genomics*. 2016;17:864. <http://dx.doi.org/10.1186/s12864-016-3206-0>
3. Dendle C, Woolley IJ, Korman TM. Rat-bite fever septic arthritis: illustrative case and literature review. *Eur J Clin Microbiol Infect Dis*. 2006;25:791–7. <http://dx.doi.org/10.1007/s10096-006-0224-x>
4. Gilroy SA, Khan MU. Rat bite fever: case report and review of the literature. *Infectious Diseases in Clinical Practice*. 2002;11:403–5. <http://dx.doi.org/10.1097/00019048-200209000-00007>
5. Irvine L, Wills T. *Streptobacillus moniliformis*: a mouse trying to become a rat. *Clinical Microbiology Newsletter*. 2006;28:118–20. <http://dx.doi.org/10.1016/j.clinmicnews.2006.07.002>
6. Trigo-Daporta M, Cortizo-Vidal S, Pallarés-González Á, García-Campello M. Fever and rash in the owner of exotic pets [in Spanish]. *Enferm Infecc Microbiol Clin*. 2011;29:311–2. <http://dx.doi.org/10.1016/j.eimc.2010.07.019>

Address for correspondence: Antoine Guillon, Centre Hospitalier Régional Universitaire de Tours, 2 Blvd Tonnelle, Tours 37044, France; email: antoine.guillon@univ-tours.fr

Malaria in Children Adopted from the Democratic Republic of the Congo

Elena Chiappini, Sara Sollai, Maurizio de Martino, Luisa Galli

Author affiliation: Meyer University Hospital, Florence University, Florence, Italy

DOI: <http://dx.doi.org/10.3201/eid2304.161777>

Data are lacking regarding asymptomatic and symptomatic malaria prevalence in internationally adopted children. Among 20 children from Democratic Republic of the Congo evaluated in Florence, Italy, in April 2016, malaria prevalence was 80%; 50% of infected children had symptomatic malaria. Adopted children from areas of high malaria endemicity should be screened for malaria.

The Democratic Republic of the Congo (DRC) banned adoption of children by parents from other countries in 2013. In February 2016, the ban was removed, and several hundred children were allowed to join families in Europe and in the United States. The first group of children from DRC arrived in Italy in April 2016, and 20 children were referred to the Center for Internationally Adopted Children at Meyer University Hospital, Florence, Italy. All children

underwent the standard infectious disease screening tests recommended by the American Academy of Pediatrics, including those for tuberculosis (by tuberculin skin test and interferon- γ release assay) and intestinal parasites (by fecal testing for ova, parasites, and antigen test for *Giardia* spp.) and serologic tests for *Toxocara canis*, *Strongyloides* spp., hepatitis B and C viruses, HIV-1/2 viruses, and *Treponema pallidum* (syphilis) (1).

Eight children who were exhibiting fever were admitted to the hospital and received a diagnosis of malaria soon after their arrival in Italy. For malaria testing, PCR and microscopy were performed on thin and thick smears. Parasitemia level was determined by counting the parasitized erythrocytes among the 500–2,000 erythrocytes on the thin smear and calculating the percentage.

The remaining children from DRC were screened, and another 8 children were found to be infected. Thus, malaria was diagnosed in 16 children (10 were boys; median age 7 years [range 4–10 years]), and malaria prevalence was 80% (16/20). *Plasmodium falciparum* infection was documented in 15 cases, whereas a mixed infection (*P. falciparum* and *P. ovale*) was observed in 1 child. All children underwent treatment with intravenous quinine plus artesunate or oral dihydroartemisinin/piperazine (2). Intravenous treatment was administered to 1 child who had severe malaria (generalized seizures) and to 5 children with a parasitemia level $\geq 2\%$ or who exhibited vomiting and therefore were unable to take oral medications reliably (2). Because intravenous artesunate is unlicensed in Europe but is available in our center, we obtained written informed consent for its use from the patients' parents before administration. The study received approval by Meyer University Hospital Ethics Committee.

Other studies have assessed the prevalence of malaria in internationally adopted children. Among a population of 182 children in France, when Blanchi et al. screened for the children originating from malaria-endemic zones who were exhibiting fever, splenomegaly, or both for malaria, they found 2 infected children (3). More recently, Adebo et al. screened 52 children arriving in the United States from Ethiopia for malaria and reported 7 (13.5%) children with asymptomatic malaria (4). These authors suggested that screening be conducted of children coming from malaria-endemic areas with noted risk factors, such as splenomegaly (4). Anemia (hemoglobin levels < 11 g/dL) could be another risk factor for malaria but, because it is common in this population, it was not considered in the study by Adebo et al. (4). However, in our population, we found that tests for parasitemia were positive for 6 children without splenomegaly or hepatomegaly and for 1 child who had neither anemia (< 11 g/dL), hepatomegaly, nor splenomegaly. Therefore, using clinical features to select children who should undergo the screening may be challenging.