



HAL
open science

A locus at 7p14.3 predisposes to refractory celiac disease progression from celiac disease

Barbara Hrdlickova, Chris J. Mulder, Georgia Malamut, Bertrand Meresse, Mathieu Platteel, Yoichiro Kamatani, Isis Ricano-Ponce, Roy L. J. van Wanrooij, Maria M. Zorro, Marc Jan Bonder, et al.

► To cite this version:

Barbara Hrdlickova, Chris J. Mulder, Georgia Malamut, Bertrand Meresse, Mathieu Platteel, et al.. A locus at 7p14.3 predisposes to refractory celiac disease progression from celiac disease. *European Journal of Gastroenterology & Hepatology*, 2018, 30 (8), pp.828-837. 10.1097/MEG.0000000000001168 . hal-02625669

HAL Id: hal-02625669

<https://hal.inrae.fr/hal-02625669>

Submitted on 21 Oct 2021

HAL is a multi-disciplinary open access archive for the deposit and dissemination of scientific research documents, whether they are published or not. The documents may come from teaching and research institutions in France or abroad, or from public or private research centers.

L'archive ouverte pluridisciplinaire **HAL**, est destinée au dépôt et à la diffusion de documents scientifiques de niveau recherche, publiés ou non, émanant des établissements d'enseignement et de recherche français ou étrangers, des laboratoires publics ou privés.



Distributed under a Creative Commons Attribution - NonCommercial 4.0 International License

REFRACTORY CELIAC DISEASE

Affiliations:

Georgia Malamut^{1,2,3}, Christophe Cellier^{1,2,3}

1: Université Paris Descartes; 2: Gastroenterology department, Hôpital Européen Georges Pompidou APHP, Paris; 3: Inserm UMR1163 Paris; France

Contact Info:

Corresponding author: Georgia Malamut, MD, PhD

Hôpital Européen Georges Pompidou, 20 rue Leblanc 75015 Paris

phone: 33.1.56.09.35.52; Fax: (33).1.56.09.35.29, E-mail: georgia.malamut@aphp.fr

Christophe Cellier, MD, PhD

Hôpital Européen Georges Pompidou, 20 rue Leblanc 75015 Paris

phone: 33.1.56.09.35.52; Fax: (33).1.56.09.35.29, E-mail: christophe.cellier@aphp.fr

Synopsis: Refractory celiac disease (RCD) refers to persistence of malnutrition and intestinal villous atrophy for more than 1 to 2 years despite strict gluten-free diet in celiac patients. Diagnosis remains difficult and impacts treatment and follow-up. RCD has been subdivided into two subgroups according to the normal (RCDI) or abnormal phenotype of intraepithelial lymphocytes (IEL) (RCDII). RCDII is considered as a low-grade intraepithelial lymphoma and has a poor prognosis due to gastrointestinal and extra-intestinal dissemination of the abnormal IELs, and high risk of overt lymphoma.

Key Words: Refractory celiac disease; phenotype of intraepithelial lymphocytes; cytokine IL-15; Enteropathy associated T cell Lymphoma

Key Points

- Refractory celiac disease (RCD) refers to two distinct entities according to the normal (RCDI) or abnormal (RCDII) phenotype of intestinal intraepithelial lymphocytes (IEL).
- Diagnosis requires specialized small bowel investigations (enteroscopy, small bowel imaging) and techniques (immunohistochemistry, molecular analysis, flow cytometry)
- Prognosis of RCDII is worse than RCDI one because of more severe malnutrition and an elevated risk of overt lymphoma.
- Therapeutic arsenal is currently mainly based on open capsule budesonide waiting for efficient targeted therapy.

ACKNOWLEDGMENTS

We thank Nadine Cerf-Bensussan (Inserm UMR1163, Institut Imagine) for FACs analysis of normal and abnormal IEL, Nicole Brousse (Anatomopathology Necker, Université Paris Descartes) for immunohistochemistry and Elisabeth Macintyre (Biological Hematology, Hôpital Necker Enfants Malades, Paris) for providing example of Multiplex PCR.

INTRODUCTION

Treatment of celiac disease (CD) relies on a life-long strict gluten-free diet that allows clinical and histological recovery after one year of gluten free diet and prevents long-term complications such as osteopenia [1], onset of other autoimmune disease [2] and malignancies [3]. Yet, systematic follow-up of biopsies has revealed that histological recovery does not occur in all patients. Notably one recent population-based study led in 7648 celiac patients in Sweden showed persistent villous atrophy in 43% cases with an increased risk in older patients (up to 56% versus 17% in children diagnosed after 2000) [4]. The similar rates of persistent villous atrophy among celiac patients biopsied 1-2 years and 2-5 years after diagnosis further argued against mucosal healing after 2 years [4]. Importantly, lack of mucosal healing has been associated with a risk of complications; it is notably a risk factor for fractures [5] and for the development of lymphomas [6]. Most cases of resistance to gluten free diet (GFD) and persistence of villous atrophy are due to bad observance [7]. Nevertheless, a small subgroup of CD patients may be primarily or secondary resistant to a GFD due to an authentic RCD with persistent symptoms of malabsorption and intestinal villous atrophy despite a strict GFD. Diagnosis of this condition is made after exclusion of other intestinal diseases with villous atrophy such as autoimmune enteropathy, tropical sprue, common variable immunodeficiency or drug induced enteropathy [8, 9, 10, 11]. Frequency of RCD remains unknown. A North American referral centre suggests a cumulative incidence of 1.5% for both RCDI and RCDII among CD patients diagnosed in this centre [12]. In the Derby cohort, J. West and G. Holmes report around 0.7% of RCD patients with ulcerative jejunitis in series of 713 celiac patients [13]. Respective proportion of both types of RCD is also undefined with apparently a higher frequency of RCDI than RCDII in US [14] in contrast with European studies [15, 16, 17, 18].

DIAGNOSIS

Diagnosis of RCD relies on persisting malabsorption and villous atrophy after one to two years of strict GFD. Compliance of gluten free diet can be ascertained by a dietician and dosage of serum celiac antibodies IgA and IgG anti-transglutaminase and IgA/IgG anti-deamidated gliadin peptides, positivity of the latest having a good correlation with gluten exposure [19]. Detection of gluten immunogenic peptides (GIP) in stool and urine enlarges the possibilities of control GFD [20, 21].

Upper gastrointestinal endoscopy with duodenal biopsies is necessary to confirm RCD and define its type (Figure 1). Double balloon enteroscopy may be useful, guided by capsule endoscopy in suspicion of RCDII for a better assessment of ulcers particularly for evidence of ulcerative jejunitis found in roughly 70% of patients [17, 22]. Thus, the risk of retention of capsule endoscopy, imposes preliminary radiological imaging of the small bowel in order to rule out strictures. Definitive diagnosis relies on histology. In RCDI, histology is similar to that found in active CD with villous atrophy and increased normal IEL. Molecular analysis showed polyclonal repertoire. Not other diagnostic criteria have been yet defined for RCDI. In contrast, the hallmark abnormal population, detected by 3 combined techniques, makes the diagnosis of RCDII more specific: over 25% of the CD103+ or CD45+ IEL lacking surface CD3-T cell receptor complexes on flow cytometry (Figure 2) or more than 50% IEL expressing intracellular CD3 α but no CD8 in formalin fixed sections and/or the presence of a detectable clonal rearrangement of the gamma chain of the TCR in duodenal biopsies (Figure 2) [23, 24]. Similar features allow detecting lymphocytic gastritis and colitis containing the same abnormal population in around 50% and 30% of RCDII patients, respectively [17]. NKP46 staining represents a promising diagnostic tool for distinguish clonal RCDII from RCDI or celiac disease [25].

FACs analysis of freshly isolated IEL is particularly useful to distinguish RCDII from other causes of severe enteropathy with villous atrophy and clonal TCRgamma rearrangement such as Granular lymphocytic Leukemia infiltrating intestine of CD patients [26] or intestinal small CD4 T cell lymphoma [27]. Analysis of the delta chain rearrangement may be useful in RCDII patients presenting oligoclonal rearrangement of the gamma chain [17]. Interest of detecting of the beta chain of the TCR has also been suggested [28, 29]. Finally, specificity of the PCR product needs to be attested by formation of homoduplexes [17] because of prominent clonal peaks possibly found in RCDI or CD patients [30].

CLINICAL FEATURES AND OUTCOME

Resistance to a GFD is primary in roughly one third and half patients with RCDI and RCDII, respectively [17]. Symptoms are notably less severe in RCDI than RCDII frequently associated to protein losing enteropathy [17]. RCDII is associated with poor prognosis with 5-year survival rates of 44% to 58% [14, 15, 17]. The more severe malnutrition combined with the higher risk of developing overt lymphoma explains the higher mortality in RCDII than in RCDI [17]. Confirming this hypothesis decreased albumin and abnormal IEL phenotype are significantly associated with 5 years mortality in a multivariate model to predict survival in refractory celiac disease [30]. Nevertheless, the mortality rate in RCDI appears higher than in uncomplicated CD [17]. One explanation is the lack of curative treatment for RCD. Immunosuppressive drugs have only a poor therapeutic effect and may predispose to overt lymphoma [32]. The second reason is the natural increased risk of developing overt lymphoma (Enteropathy Associated-T cell Lymphoma (EATL)). Indeed, 33% to 52% of RCDII patients develop EATL within the five years after diagnosis [14, 15, 17]. Onset of EATL in RCDI is not null even if much lower than in RCDII, with a five-year rate of 14% in the more pessimistic studies [17]. In RCDII abnormal IEL may be found in

mesenteric lymph nodes, blood, bone marrow, and in different epitheliums such as lung and skin [17]. Extra-intestinal dissemination of RCDII IEL explains that EATL do not develop exclusively in the intestine. EATL may notably arise from RCDII cutaneous lesions. Their expression of CD103 and their identical TCR α clonality [17] ascertain their origin from RCDII IEL. RCDII patients require regular clinical follow-up combined with enteroscopy, computed tomography scan (CT-scan) or MRI small bowel follow-through and positron emission tomography (Pet-scan) [33]. Pet-scan can further guide realization of radiological guided biopsy or explorative laparoscopy. It must however be stressed that EATL can arise in CD patients who do not display any evidence of RCDII. Histological diagnosis is easier than in RCDII with infiltration by medium to large lymphoid expressing CD30 in more than 80% of cases [34]. The prognosis of EATL is poor with an overall survival currently estimated at 20% to 25%, 5 years after the diagnosis with a better prognosis in EATL complicating CD compared to EATL complicating RCDII [34, 35].

PATHOGENESIS

It remains unknown whether RCD patients have a particular genetic background differentiating them from patients with uncomplicated CD. It has been reported that severity of celiac disease was correlated with the number of HLA-DQ2 copies: homozygosity for HLA-DQ2 was observed in 25.5% of RCD I, 44.1% of RCD II, and 53.3% of EATL patients vs 20.7% of uncomplicated CD patients and 2.1% of controls [36]. In a recent European study most patients with RCDII were homozygous HLA-DQ2 (>64.4%) [37]. Moreover this study identified the locus 7p14.3 as favoring progression to RCDII [37]. Besides inherited genetic factors, some acquired somatic mutations have been identified. Indeed a recurrent partial trisomy 1q22-q44 has been found in majority of RCDII patients [37]. More recently the JAK1 and STAT3 mutations were identified in abnormal IEL in RCDII patients [38].

Onset of RCD may be favored by environmental factors such as exposure to gluten. Risk of lymphomatous complications was reported 4 times higher in patients without adherence to a gluten free diet than compliant patients [39]. The scientific rationale may rely on more intense production of IL-15 under gluten exposure [40].

Infections and particularly viral infections may constitute another environmental factor favouring emergence of RCD. We observed B or C hepatitis at onset of refractoriness in 20% and 10% of RCDI and RCDII patients, respectively [17]. More than a specific virus, it is rather suspected that components of the antiviral responses and notably Type I interferons might promote the onset of chronic inflammatory disorders (reviewed in [41]). Type I interferon may notably stimulate the survival and proliferation of CD8+ T cells and NK cells, either directly or via the induction of IL-15 [41]. We can hypothesize that such mechanism may occur in RCDI helping the immunological reaction initiated by gluten to evolve toward autoimmunity. Accordingly, symptoms improve under immunosuppressive treatments [17]. However mechanisms of RCDI are largely unknown and remain to be substantiated. More progress has been performed recently in the understanding of the pathogenesis of RCDII. Contrary to EATL which expressed Ki67, RCDII is characterized by massive accumulation of abnormal IEL without *in situ* detectable proliferation but with apoptosis defect [40]. In active CD and RCDII, IL-15 produced in excess exerts potent anti-apoptotic effects that prevent the elimination of activated IELs and promote their massive accumulation by activating a survival signal [40, 41]. Indeed clonal RCDII IEL acquired somatic mutations (JAK1, STAT3) which selectively increase their responsiveness to IL-15. Human anti-IL-15 antibodies inhibit *ex vivo* the IL-15 driven signalling pathway in intestinal organotypic cultures of RCDII patients. *In vivo*, treatment, by this antibody of mice overexpressing human IL-15 in small bowel wiped out the IEL hyperplasia observed in these mice [42].

TREATMENTS

Steroids improved clinical symptoms in most patients with either type of RCD with various histological response from 30-40% of cases to nearly 90% in a recent study using open capsule budesonide [17, 43]. Because of steroid dependence, immunosuppressors such as azathioprine or anti-TNF- α are used and produce transient clinical response but rare mucosal improvement [17]. In RCDII immunosuppressive drugs have no impact on the abnormal clonal IEL population and could enhance the risk of overt lymphoma as observed with azathioprine and anti-CD52 by depletive effect [17]. In RCDI no scientific rationale has been yet established to treat specifically RCDI patients with targeted therapy. The non-proliferative RCDII cells are thus difficult to eradicate by regular chemotherapy and may represent a reservoir of cells susceptible to more aggressive transformation. Purine analogues such as pentostatin or cladribine (2-CDA) showed moderate clinical, histological and haematological efficacies [44, 45]. In our experience, 2-CDA can induce clinical and histological response in RCDII patients [17]. However, explosive onset of overt lymphoma was observed in the 2 treated patients within 3-8 weeks after treatment, precluding further use of these drugs. Another strategy is the use of autologous haematopoietic stem cell transplantation which induced clinical and histological response but no sustained reduction of abnormal IEL in the 13 treated patients [46, 47]. The use of chemotherapy before autologous haematopoietic stem cell transplantation may probably increase haematological response. Targeted strategy appears necessary to complete the therapeutic armory to treat RCDII. Blocking IL-15 signaling appears the treatment of choice in RCDII [42]. The preliminary results of phase II clinical trial using the humanized anti-IL-15 antibody are encouraging [48]. Treatment of RCDII will probably combine, in the next future, conventional chemotherapy agents and targeted therapy blocking IL-15 signaling (reviewed in [49]).

CONCLUSION

In conclusion, RCD refers to two distinct entities, RCDI the benign form and the malignant form RCDII characterized by clonal expansion of small aberrant IEL. Small bowel investigations (enteroscopy, videocapsule endoscopy) and specialized techniques of IEL analyses (immunohistochemistry, molecular biology, flow cytometry) are necessary for diagnosis of both forms of RCD. Prognosis of RCDII is severe due to malnutrition and high risk of overt lymphoma. Recent advances in dissecting the lymphomagenesis associated to CD intend to hope next efficient treatments.

REFERENCES

1. Thomason K, West J, Logan RF, et al. Fracture experience of patients with coeliac disease: a population based survey. *Gut*. 2003;52:518-22.
2. Cosnes J, Cellier C, Viola S, et al. Incidence of Autoimmune Diseases in Celiac Disease: Protective Effect of the Gluten-Free Diet. *Clin Gastroenterol Hepatol*. 2008;6:753-8.
3. Holmes GK, Prior P, Lane MR, et al. Malignancy in coeliac disease--effect of a gluten free diet. *Gut*. 1989;30:333-8.
4. Lebwohl B, Murray JA, Rubio-Tapia A, et al. Predictors of persistent villous atrophy in coeliac disease: a population-based study. *Alimentary pharmacology & therapeutics* 2014; 39: 488-495.
5. Lebwohl B, Granath F, Ekbom A, et al. Mucosal healing and risk for lymphoproliferative malignancy in celiac disease: a population-based cohort study. *Annals of internal medicine* 2013;159:169-175
6. Lebwohl B, Michaelsson K, Green PH, et al. Persistent mucosal damage and risk of fracture in celiac disease. *J Clin Endocrinol Metab* 2014; 99: 609-616.
7. Vahedi K, Mascart F, Mary JY, et al. Reliability of antitransglutaminase antibodies as predictors of gluten-free diet compliance in adult celiac disease. *Am J Gastroenterol* ;98:1079-87.
8. Akram S, Murray JA, Pardi DS, et al. Adult autoimmune enteropathy: Mayo Clinic Rochester experience. *Clin Gastroenterol Hepatol*. 2007;5:1282-90.
9. Khokhar N, Gill ML. Tropical sprue: revisited. *J Pak Med Assoc*. 2004;54:133-4.

10. Malamut G, Verkarre V, Suarez F, et al. The enteropathy associated with common variable immunodeficiency: the delineated frontiers with celiac disease. *Am J Gastroenterol.* 2010;105:2262-75.
11. Scialom S, Malamut G, Meresse B, et al. Gastrointestinal Disorder Associated with Olmesartan Mimics Autoimmune Enteropathy. *PLoS One.* 2015 Jun 23;10(6):e0125024.
12. Roshan B, Leffler DA, Jamma S, et al. The incidence and clinical spectrum of refractory celiac disease in a north american referral center. *Am J Gastroenterol.* 2011.106:923-8.
13. West J. Celiac disease and its complications: a time traveller's perspective. *Gastroenterology* 2009;136:32-4.
14. Rubio-Tapia A, Kelly DG, Lahr BD, et al. Clinical staging and survival in refractory celiac disease: a single center experience. *Gastroenterology* 2009;136:99-107.
15. Al-Toma A, Verbeek WH, Hadithi M, et al. Survival in Refractory Coeliac Disease and Enteropathy associated T cell Lymphoma: Retrospective evaluation of single centre experience *Gut* 2007;56:1373-8.
16. Daum S, Cellier C, Mulder CJ. Refractory coeliac disease. *Best practice & research* 2005 ;19:413-24.
17. Malamut G, Afchain P, Verkarre V, et al. Presentation and long-term follow-up of refractory celiac disease: comparison of type I with type II. *Gastroenterology* 2009;136:81-90.
18. Malamut G, Cellier C. Is refractory celiac disease more severe in old Europe? *Am J Gastroenterol* 2011;106:929-32.

19. de Chaisemartin L, Meatchi T, Malamut G, et al. Application of Deamidated Gliadin Antibodies in the Follow-Up of Treated Celiac Disease. *PLoS One*. 2015;10(8):e0136745
20. Comino I, Fernández-Bañares F, Esteve M, et al. Fecal Gluten Peptides Reveal Limitations of Serological Tests and Food Questionnaires for Monitoring Gluten-Free Diet in Celiac Disease Patients. *Am J Gastroenterol*. 2016;111(10):1456-1465.
21. Moreno ML, Cebolla Á, Muñoz-Suano A, et al. Detection of gluten immunogenic peptides in the urine of patients with coeliac disease reveals transgressions in the gluten-free diet and incomplete mucosal healing. *Gut*. 2017;66:250-257
22. Barret M MG, Rahmi G, Samaha A, et al. Diagnostic yield of capsule endoscopy in refractory celiac disease. *Am J Gastroenterol* 2012 ;107(10):1546-53.
23. Cellier C, Patey N, Mauvieux L, et al. Abnormal intestinal intraepithelial lymphocytes in refractory sprue. *Gastroenterology* 1998;114:471-81.
24. Cellier C, Delabesse E, Helmer C, et al. Refractory sprue, coeliac disease, and enteropathy-associated T-cell lymphoma. French Coeliac Disease Study Group. *Lancet* 2000;356:203-8.
25. Cheminant M, Bruneau J, Malamut G, et al. NKP46 is a useful diagnostic biomarker in gastrointestinal T-cell lymphoproliferative diseases. A CELAC network study. ICDS (17th International Celiac disease symposium) India 2017.
26. Malamut G, Meresse B, Verkarre V, et al. Large Granular Lymphocytic Leukemia complicating Celiac disease: a rare cause of refractory celiac disease. *Gastroenterology* 2012. 143:1470-1472.

27. Malamut G, Meresse B, Kaltenbach S, et al. Small intestinal CD4+ T-cell lymphoma is a heterogenous entity with common pathology features. *Clin Gastroenterol Hepatol.* 2014;12(4):599-608
28. Perfetti V, Brunetti L, Biagi F, et al. TCRbeta Clonality Improves Diagnostic Yield of TCRgamma Clonality in Refractory Celiac Disease. *J Clin Gastroenterol* 2012;46:675-9.
29. Ritter J, Zimmermann K, Jöhrens K, et al. T-cell repertoires in refractory coeliac disease. *Gut.* 2018 Apr;67(4):644-653.
30. Hussein S, Gindin T, Lagana SM, et al. Clonal T cell receptor gene rearrangements in coeliac disease: implications for diagnosing refractory coeliac disease. *J Clin Pathol.* 2018 Apr 27. pii: jclinpath-2018-205023.
31. Rubio-Tapia A, Malamut G, Verbeek WH, et al. Creation of a model to predict survival in patients with refractory coeliac disease using a multinational registry. *Aliment Pharmacol Ther.* 2016;44(7):704-14
32. Goerres MS, Meijer JW, Wahab PJ, et al. Azathioprine and prednisone combination therapy in refractory coeliac disease. *Aliment Pharmacol Ther.* 2003;18:487-94.
33. Hoffmann M, Vogelsang H, Kletter K, et al. 18F-fluoro-deoxy-glucose positron emission tomography (18F-FDG-PET) for assessment of enteropathy-type T cell lymphoma. *Gut* 2003;52:347-51.
34. Malamut G, Chandesris O, Verkarre V, et al. Enteropathy associated T cell lymphoma in celiac disease: A large retrospective study. *Dig Liver Dis.* 2013;45:377-84.
35. Gale J, Simmonds PD, Mead GM, et al. Enteropathy-type intestinal T-cell lymphoma: clinical features and treatment of 31 patients in a single center. *J Clin Oncol* 2000;18:795-803.

36. Al-Toma A, Goerres MS, Meijer JW, et al. Human leukocyte antigen-DQ2 homozygosity and the development of refractory celiac disease and enteropathy-associated T-cell lymphoma. *Clin Gastroenterol Hepatol* 2006;4:315-9.
37. Verkarre V, Romana SP, Cellier C, et al. Recurrent partial trisomy 1q22-q44 in clonal intraepithelial lymphocytes in refractory celiac sprue. *Gastroenterology* 2003;125:40-6.
38. Ettersperger J, Montcuquet N, Malamut G, et al. Interleukin-15-Dependent T-Cell-like Innate Intraepithelial Lymphocytes Develop in the Intestine and Transform into Lymphomas in Celiac Disease. *Immunity*. 2016 20;45(3):610-625.
39. Holmes GK, Prior P, Lane MR, et al. Malignancy in coeliac disease--effect of a gluten free diet. *Gut* 1989;30:333-8.
40. Mention JJ, Ben Ahmed M, Begue B, et al. Interleukin 15: a key to disrupted intraepithelial lymphocyte homeostasis and lymphomagenesis in celiac disease. *Gastroenterology* 2003;125:730-45.
41. Foxman EF, Iwasaki A. Genome-virome interactions: examining the role of common viral infections in complex disease. *Nat Rev Microbiol*. 2011;(4):254-64.
42. Malamut G, El Machhour R, Montcuquet N, et al. IL-15 triggers an antiapoptotic pathway in human intraepithelial lymphocytes that is a potential new target in celiac disease-associated inflammation and lymphomagenesis. *The Journal of clinical investigation* 2010;120:2131-43.
43. Mukewar SS, Sharma A, Rubio-Tapia A, et al. Open-Capsule Budesonide for Refractory Celiac Disease. *Am J Gastroenterol*. 2017;112(6):959-967.
44. Dray X, Joly F, Lavergne-Slove A, et al. A severe but reversible refractory sprue. *Gut* 2006;55:1210-1.

45. Al-Toma A, Goerres MS, Meijer JW, et al. Cladribine therapy in refractory celiac disease with aberrant T cells. *Clin Gastroenterol Hepatol* 2006;4:1322-7
46. Al-Toma A, Visser OJ, van Roessel HM, et al. Autologous hematopoietic stem cell transplantation in refractory celiac disease with aberrant T-cells. *Blood*. 2007;109(5):2243-9.
47. Tack GJ, Wondergem MJ, Al-Toma A, et al. Auto-SCT in refractory celiac disease type II patients unresponsive to cladribine therapy. *Bone marrow transplantation* 2011;46(6):840-6.
48. Cellier C, Bouma, G, van Gils T, et al. AMG 714 (anti-IL-15 Mab) halts the progression of aberrant intraepithelial lymphocytes in refractory celiac disease type II (RCDII): a phase 2A randomized, doubleblind, placebo-controlled study evaluating AMG714 in adult patients with RCDII/pre-EATL. *DDW* 2018
49. Refractory Celiac disease. Malamut G, Meresse B, Cellier C, Cerf-Bensussan N, *Seminar in Immunopathology* 2012; 34(4):601-13.

Legends

Figure 1: Diagnostic features of RCDI and RCDII: immunohistochemistry, Multiplex PCR and Flow Cytometry

Figure 2: Investigation of enteropathy with villous atrophy refractory to gluten free diet.

A) Immunohistochemistry.

Courtesy of Dr. Virginie Verkarre, MD, Paris, France.

B) Multiplex PCR.

Courtesy of Elizabeth Macintyre, MD, PHD, Paris, France.

C) Flow cytometry.

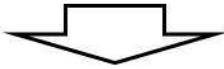
Courtesy of Nadine Cerf-Bensussan, MD, PHD, Paris, France and Nicolas Guegan, Paris, France.

Nonresponsive celiac disease

- Check:
- Gluten consumption
 - Immunogenic peptides excretion
 - Celiac Ab at diagnosis
 - HLA DQ2/DQ8
 - Anti-AIE75KD Ab
 - Treatment

Repeat Upper Endoscopy/Enteroscopy

- Intestinal Biopsy
 Immunohistochemistry (IHC)
 Multiplex PCR
 Isolation & FACs



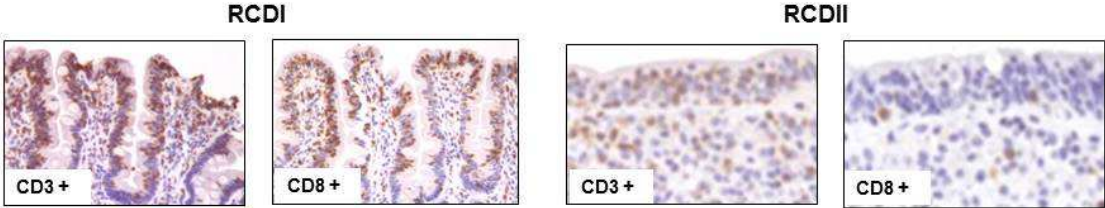
Bad observance of Gluten free diet

- Other causes of villous atrophy:**
- Autoimmune enteropathy
 - Common variable immunodeficiency
 - Tropical sprue
 - Whipple
 - Others causes: sartans...

Refractory celiac disease

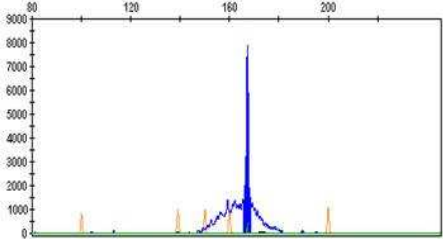
	IHC	PCR	FACs
RCDI	iCD3+ CD8- IEL < 50%	Polyclonal TCR	sCD3- CD8- IEL < 25%
RCDII	iCD3+ CD8- IEL > 50%	Clonal TCR	sCD3- CD8- IEL > 25%

Immunohistochemistry



Multiplex PCR

RCDII: clonal rearrangement of TCR γ



Flow cytometry

