

**Animal Science**

**SHORT COMMUNICATION**

**Ovarian hydrobursitis in slaughtered female camels (*Camelus dromedarius*) in Southeast Algeria**

**Mohammed Hocine Benaissa<sup>1,2\*</sup>, Bernard Faye<sup>3,4</sup> and Rachid Kaidi<sup>5</sup>**

<sup>1</sup>Higher National Veterinary School, PB 161 Hacène Badi, EL Harrach, Algiers, Algeria

<sup>2</sup>Scientific and Technical Research Centre for Arid Areas (CRSTRA), Biophysical Station, PB 30240, Nezla, Touggourt, Algeria

<sup>3</sup>Camel project UTF/SAU/044/SAU, Al-Kharj Agriculture project, Saudi Arabia

<sup>4</sup>UMR SELMET, Centre de Coopération Internationale en recherche agronomique pour le développement (CIRAD-ES), Montpellier, France

<sup>5</sup>Institute of Veterinary Sciences, LBRA, University of Blida 1, PB 270, Soumaa, Blida, Algeria

**Abstract**

The aims of the present study were to investigate the prevalence of ovarian hydrobursitis, and its pathologic and histopathologic characteristics in slaughtered female camels. The reproductive tracts of 740 female camels were collected and examined from January 2011 to February 2013, in two abattoirs from southeast Algeria. Ovarian hydrobursitis was observed in 32 reproductive tracts (4.32%); unilaterally (n=17) or bilaterally (n=15). The frequency of right side and left side ovarian hydrobursitis was not significantly different. It was associated with peri-uterine adhesion, pyometra, and paraovarian cysts. The affection was observed in some pregnant cases. Microscopic examination revealed diffuse edema, capillary congestion, infiltration, and heavy infiltration of mononuclear cellular, cystic dilatation of multi-acinal structures, desquamation and hyperplasia of the epithelial lining, tiny hemorrhages, and a large number of hemosiderin-laden macrophages. In conclusion, this study has identified the prevalence and the main anatomical and histopathological features the ovarian hydrobursitis. This syndrome is a serious problem affecting the fertility in dromedary camel in Algeria.

*Key words:* Dromedary camel, Ovarian hydrobursitis, Histopathology, Algeria

**Introduction**

Most of the 315,000 camels (source FAOstat, 2013) living in Algeria are raised on a free-range basis (called *Hmil*), roaming freely in search of food (Adamou, 2008; Benaissa et al., 2012). Camels have a low rate of reproduction compared to other farm animals, due to delayed puberty, delayed postpartum estrus and a Short reproduction season. The contribution of reproductive diseases in lowering the reproductive efficiency in this species is largely unknown. Ovarian hydrobursitis is responsible for large number of long standing infertility problems in dromedary camels characterized by adhesion,

fluid accumulation and encapsulation of the ovary (Tibary and Anouassi, 2001; Ali et al., 2011a). This syndrome is manifested by early embryonic death, abortion, repeat breeding, and refuses mating (Ali et al., 2011a,b).

However, the etio-pathogenesis of this syndrome is not well documented (Tibary and Anouassi, 2001; Ali et al., 2011b; Al-Sultan et al., 2013), and therefore histopathological examination is recommended. Histopathology is a reliable technique to assess the degree of their alteration and for evaluating changes that might occur in the ovarian bursa like inflammation, degeneration and neoplasia. As camel husbandry in the Saharan region of Algeria is principally nomadic with a very extensive system, the abattoirs are a convenient source for studying pathological lesions of camel reproductive organs. There is paucity of information on reproductive disorders of camels in southeast of Algeria. The objectives of the current study were to (1) record the incidence of ovarian hydrobursitis in Algeria,

---

Received 19 December 2013; Revised 30 July 2014; Accepted 02 August 2014; Published Online 16 September 2014

\*Corresponding Author

Mohammed Hocine Benaissa  
Higher National Veterinary School, PB 161 Hacène Badi, EL  
Harrach, Algiers, Algeria

Email: ben.medhocine@gmail.com

(2) clarify the gross and histopathological changes associated with ovarian hydrobursitis.

## **Materials and Methods**

### **Examination at slaughterhouse**

A total of 740 genital tracts of Arabian adult female camels were examined in two abattoirs from southeast Algeria, between January 2011 and February 2013. Post-mortem examination of the reproductive tracts was carried out and examined for the existence of ovarian hydrobursitis, its location (right and/or left) and relation to the surrounding structures or organs. Pathological examinations were performed using visual inspection to determine the bursal dimensions (length × width), character and amount of the bursal fluid, status of the ipsilateral ovary and fallopian tube (free or adhered) and presence of accompanying affections in the genital tract.

### **Histopathological examination**

Specimens from bursa showing gross abnormalities were prepared for histopathological examination according to Drury and Wallington (1986). They were immediately fixed in 10% neutral buffered formalin, then dehydrated in ascending grades of ethanol alcohols, cleared in xylol, casted and processed in paraffin, sectioned at 4–5 µm and stained with hematoxylin and eosin (H&E).

### **Statistical analysis**

Data were presented in percentages and the analysis was conducted using SPSS software package (SPSS. IBM Corp Ver. 20.0). Differences between the frequency of bilateral and unilateral affection as well as between the left and right sided affection were evaluated by Chi-square test. The level of significance was set at  $P < 0.05$ .

## **Results**

### **Incidence and clinical findings**

Ovarian hydrobursitis was observed in 32 out of 740 reproductive tracts examined (4.3%). Unilateral cases were observed at frequencies

17/32 cases (53.1%), and bilateral cases at 15/32 cases, (46.9%). The incidence of bilateral and unilateral ovarian hydrobursitis was not significantly different, (Figure 1A, B). Also the difference between the incidence of right and left side affection was not statistically significant. The affection was associated with peri-uterine adhesion (n = 6), pyometra (n = 2), and paraovarian cysts (n = 2).

The size of the affected bursa ranged between 4.5 x 6.5 cm to a maximum of 39.5 x 38 cm, The accumulation had different colors, namely the transparent (n = 10), yellowish (n = 15), brownish (n = 12), or dark (Figure 1D). The consistencies of contents varied from watery to highly viscous to almost gelatinous. This fluid had an amount of between 1.9 to 2390 ml. The results also revealed that from the 47 affected ovaries, 34 (72.3%) ovaries were encapsulated and freely movable, while 13 (27.7%) were adhered to the bursal membrane. Pregnancy was detected in 2 cases (6.2%, Figure 1C) of the affected females.

### **Histopathological findings**

The ovarian bursa was characterized by degeneration and vacuolation of the mucosal epithelial cells accompanied with perivascular mononuclear cellular infiltration. They contained diffuse edema and formation of cyst-like cavities that were variable in size, irregular in shape, lined by simple cuboidal cells, and filled with homogenous fluid (Figure 2A, D). Massive hyperplasia of the mucosal epithelial cells associated with heavy infiltration of inflammatory cells was also observed in some specimens (Figure 2A). Focal aggregation of immune cells was also observed in many specimens (Figure 2F). Microscopic examination showed hyperplasia of the epithelial lining with desquamated epithelial cells. In addition, a large number of hemosiderin-laden macrophages accompanied by capillary congestion and extra-vascular erythrocytes were identified in some cases (Figure 2A, B, and D).

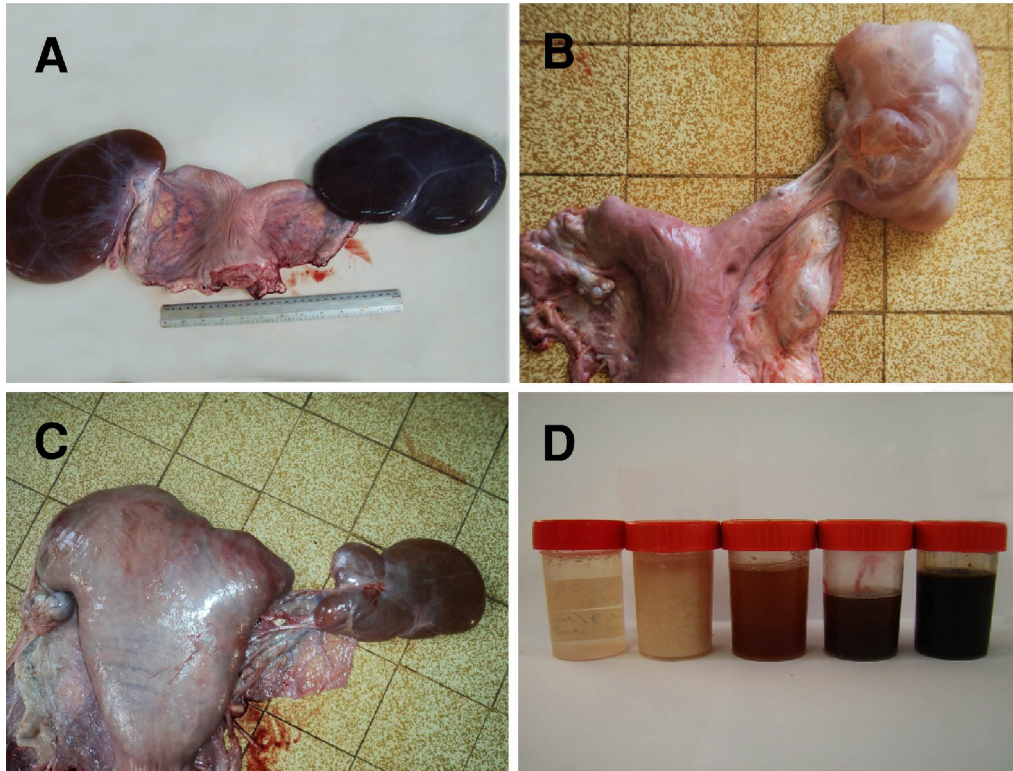


Figure 1. Ovarian hydrobursitis in female camels. A, bilateral ovarian hydrobursitis; B, unilateral ovarian hydrobursitis; C, ovarian hydrobursitis in pregnant female; D, different fluids in the bursa.

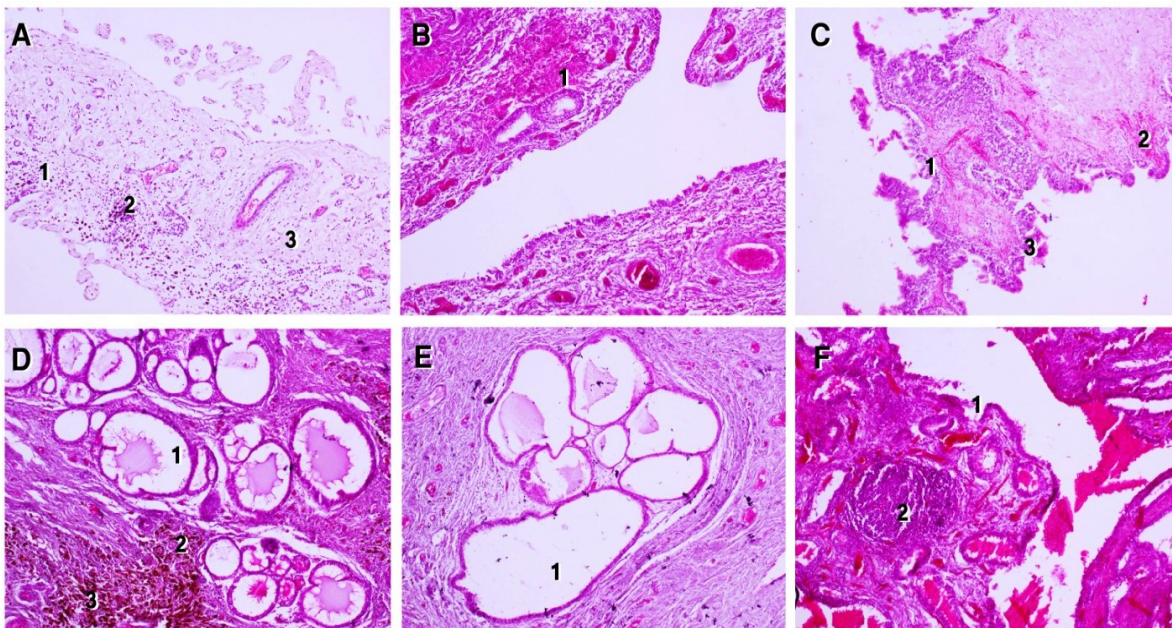


Figure 2. Histopathology of affected ovarian bursae in female camels: A. Hyperplasia of the cellular lining (1), inflammatory cellular infiltration (2), edema (3), X100; B. Tiny hemorrhage (2), X100; C. Degeneration and vacuolation of the mucosal epithelial cells (1), capillary congestion (2) and proliferation of inner cubodial cells, X100; D. Cystic dilatation of multi-acinal structures (1), heavy infiltration of inflammatory cells (2) and hemosiderinladenm acrophages (3). X100; E. Cystic dilatation of multi-acinal structures (1); F. Degeneration and vacuolation of the mucosal epithelial cells (1), focal aggregation of mononuclear cells (2). Stained with H&E.

## Discussion

The prevalence of the syndrome in our study (4.3%) was approximately similar to the 6.5% reported by Ali et al. (2011a). Previous slaughterhouse surveys showed a wide range of prevalence rates of ovarian hydrobursitis varying from 1.95% (Al-Afaleq et al., 2012) to 16% (Ali et al., 1992). However, in field investigations and among infertile cases the incidence of the syndrome was 16.5% in Saudi Arabia (Ali et al., 2011b) and 15.2% in Somalia (Nur, 1984). In UAE, the studies of El-Khouly et al. (1990), Tibary and Anouassi (2001) and Quershi and Al-Jabouri (2009) have shown hydrobursitis incidences of 13.9, 9.8% and 2.25%, respectively. Tibary and Anouassi (1997) reported that the incidence of this disorder was relatively higher in animals with a background of reproductive failure.

Our results agree with the study of El Khouly et al. (1990) and Tibary and Anouassi (2001), which have shown that bilateral and unilateral incidences were approximately equal. However, our results do not agree with the studies of Shalash and Nawito (1963) and Al-Eknaah et al. (2012) in which they found that ovarian hydrobursitis were unilateral in 87% and 85% of cases and bilateral in 13% and 15%, respectively. The results provided by Al-Eknaah and Ali (2001) were also different from our results; they showed that 62% of affected cases were unilateral and 38% were bilateral. In addition, the results of Ali (2010) were not consistent with the present results, because he found that all of the ovarian hydrobursitis were unilateral in slaughtered animals, however, the same study showed that the differences between the incidence of bilateral and unilateral affection were not significantly different in infertile female camels examined clinically.

Our results revealed no statistically significant difference between the rate of ovarian hydrobursitis in the right and left sides. These findings are not consistent with studies reporting that the left side was more affected than the right side. (Tibary and Anouassi, 2001; Ali et al., 2011a).

Regarding the association of bursal affection with peri-uterine adhesion, pyometra and paraovarian cysts, observed in our study, Ali et al. (2011a) reported that ovarian hydrobursitis was associated with purulent endometritis, adhesions of the uterus and vagina, closed cervix and pyometra, vaginal adhesion and pyometra, and enlargement of the fallopian tube. Tibary and Anouassi (2001) stated that in some cases, the hydrobursitis was associated to salpingitis which

could suggest the involvement of infection or an acute inflammatory process with occlusion of the oviduct.

Our results indicated that the affected ovaries might remain active. This was because a significant percentage of active ovaries (about 72.3%) were observed in the affected samples, were CLs, as well as follicles, found on the ovaries, in support of previous works finding that the ovary of the affected side was functionally active (Ali et al., 2011a). Ovulation would have occurred but without successful fertilization. It is probable that the oocyte gets washed into the bursal fluid and does not get to the oviduct. In addition, some cases of pregnancy were observed in samples with one affected ovary, and this might indicate that the non-affected ovary could function normally even the other ovary was affected, in accordance with Tibary and Anouassi (1997). Reproductive life can be saved in the case of unilateral affections by surgical removal of the affected bursa and ovary (Tibary and Anouassi, 2001).

The general microscopic pattern observed in the present study was similar to previous observations of the same species. Ovarian bursa showed degenerated and vacuolated mucosal epithelial cells accompanied with perivascular mononuclear cellular infiltration (Ali et al., 2011a). In many cases, the ovarian hydrobursitis appeared to be associated with other abnormalities such as pyometra and peri-uterine adhesion. In the present context, Ali et al. (2011a) stated that an infectious agent may contribute in the etiology of this syndrome. Concurrent chronic genital inflammations were found to be closely related to the histopathological lesions detected in the affected female camels. Inflammation is usually considered as a one of the biological response of vascular tissues to both external and internal stimuli (Ferrero-Miliani et al., 2007). An example of the inflammation process resulting of the response of immune system was the focal aggregation of immune cells observed in some specimens (Figure 2F).

Hemosiderin has been appeared in many samples, and according to McGavin et al. (2007); hemosiderin may be related to phagocytosis of red blood cells and hemoglobin. Besides, several factors might cause the hyperplasia that observed in our histopathological examination, for example, chronic inflammatory response, hormonal dysfunctions or compensation for damage or disease (McGavin et al., 2007). The tiny hemorrhage could be attributed, according to Ali

et al. (2011a), to the twist of the distended and pedunculated bursa leading to escape of blood from congested veins. Considering the multi-acinal structures, still there was no explanation for the development of these structures in the ovarian bursa (Baba and Catoi, 2007; Ali et al., 2011a).

### Conclusion

The “ovarian hydrobursitis” syndrome is an important and serious reproductive constraint in dromedary camel. It is known that the etiology of this abnormality is so complex, and hence the association of other lesions in one animal suggested that the predisposing factor is the anatomic position of both ovary and ovarian bursa, or a sequel to other lesions. However, the present study remains only a ground for further investigations, as it does not provide full answers to all questions regarding the etiopathogeny of the ovarian hydrobursitis in female camels. Further researches are required to form more complete understanding of the topic, and to resolve a number of related questions.

### Acknowledgments

We thank Prof. Amara Abdelkader Department of anatomy, National Veterinary School, Sid Thabet, Tunisia, for help with histopathological diagnosis and his scientific supports. We are also grateful to Dr. Halis Youcef, Mr. A. Boukhelkhel for helpful comments on earlier versions of this manuscript.

### References

- Adamou, A. 2008. Camel livestock in Algeria: What type for what future? *Sécheresse* 19:253-260.
- Al-Afaleq, A. I., A. A. Hegazy, M. F. Hussein and A. M. Al-Dughaym. 2012. Pathological disorders of the female reproductive system in slaughtered camels (*Camelus dromedarius*) in Saudi Arabia. *Comp. Clin. Pathol.* 21:245-251.
- Al-Eknah, M. M and A. M. A. Ali. 2001. Infundibular cyst jeopardize reproduction in female camels (*Camelus dromedarius*). *Emir. J. Agric. Sci.* 13:52-56.
- Al-Eknah, M. M., R. O. Ramadan, A. I. Almubarak, F. Al-Mohsen, M. Al-Salman and A. M. Ali. 2012. Verification of ovarian hydro-bursitis syndrome in the dromedary camels and its surgical ablation. *Proceedings of the ICAR Satellite Meeting on Camelid Reproduction - Vancouver, Canada.* p.42-46.
- Ali, A. M. A., S. M. El-Sanousi, M. M. AIEknah, A. A. Gameel, E. A. Dafalla, Y. M. Homeida and Y. M. Radwan. 1992. Studies on the infundibular cysts of the uterine tube in camel (*Camelus dromedarius*). *Rev. Elev. Med. Vet. Pays Trop.* 45:243-253.
- Ali, A. M. H. 2010. Observations on the topography of the reproductive tract of the Arabian female camel. *J. Agric. Vet. Sci. Qassim Univ.* 3:33-41.
- Ali, A., E. E. Mehana, A. F. Ahmed, O. El-Tookhy, A. Al-Sobayil and A. Al-Hawas. 2011a. Ovarian hydrobursitis in female camels (*Camelus dromedarius*): clinical findings, histopathology and fertility after unilateral surgical ablation. *Theriogenol.* 76:492-499.
- Ali, A., F. A. Al-Sobayil, M. Tharwat and K. M. Hassanein. 2011b. Ovarian hydrobursitis in female camels (*Camelus dromedaries*): biochemical, bacterial and protozoal evaluation. *Theriogenol.* 75:734-741.
- Al-Sultan, A., M. Al-Eknah and A. Al-Dougym. 2013. Detection of *Escherichia coli* associated with ovarian hydro-bursitis syndrome in camels harbouring extended-spectrum beta-lactamases (ESBL) TEM gene," <http://molecularhub.org/resources/697>.
- Arthur, G. H and A. R. El Tigani. 1990. Camel production in Saudi Arabia. In: *Proceedings of the workshop 'Is it Possible to Improve the Reproductive Performance of the Camel?'* Paris, France. pp.149-160.
- Baba, A. I. and C. Catoi. 2007. *Comparative oncology*, 1st edition. In: A. I. Baba and C. Catoi (Eds.), *The Publishing House of the Romanian Academy.*
- Benaissa, M. H., R. Mayouf, B. Hamad, M. Saidi, A. Mehdaoui and M. Belhamra. 2012. Husbandry practices of camel herders in the region of El-Oued (southeast of Algeria). In: *Proceeding of the 3rd Conference of the ISOCARD (Challenges facing the camelids in a changing world and climate).* pp.163-164
- Drury, R. and E. Wallington. 1986. *Carlton's histological technique.* 4<sup>th</sup> Ed. Oxford Univ. Press, N Y, Toronto.

- EI Khouly, A. A., A. El Nasr, A. Ontabli and F. A. Gadir. 1990. Some pathologic affections of camel ovaries in U.A.E. *Zagazig Vet.* 18:210-217.
- FAOstat, 2013. Food and Agriculture Organization, Official statistics ([http://faostat3.fao.org/home/index\\_fr.html?l\\_ocale=fr](http://faostat3.fao.org/home/index_fr.html?l_ocale=fr)).
- Ferrero-Miliani, L., O. H. Nielsen, P. S. Andersen and S.E. Girardin. 2007. Chronic inflammation: importance of NOD2 and NALP3 in interleukin-1beta generation. *Clin Exp. Immunol.* 147:227-35.
- McGavin, M. D. and J. F. Zachary. 2007. *Pathologic Basis of Veterinary Disease*. 4<sup>th</sup> Ed. Mosby Elsevier.
- Nur, H. M. 1984. Some reproductive aspects and breeding patterns of the Somali camel (*Camelus dromedarius*). In: M. A. Hussein (Ed.). pp.91-110. *Camel Pastoralism in Somalia. Proceedings from Workshop in Baydhabo, Mogadishu, Somali Academy of Science and Arts (Camel form Working paper, 7)*.
- Quershi, Z. I. and A. Al-jabouri. 2009. Clinical prevalence of reproductive disorders in dromedary camel under field conditions, Djerba, Tunisia March 12-14 th ISOCARD Conference. 136. (Abstr.).
- Sghiri, A. 1987. Evaluation des performances de reproduction d'un troupeau camelin a Laayoune (*Camelus dromedarius*). These de Doctorat Veterinaire de l'Institut Agronomique et Veterinaire Hassan II, Rabat, Maroc.
- Shalash, M. R. and N. Nawito. 1963. Some aspects of sterility in the female camel. *Deutsche Tierarztliche Wochenschrift.* 70:522-524.
- SPSS. IBM Corp. Released 2011. *IBM SPSS Statistics for Windows, Version 20.0*. Armonk, NY: IBM Corp.
- Tibary, A. and A. Anouassi. 1997. *Theriogenology in camelidae: anatomy, physiology, pathology and artificial breeding*. Veterinary Research Centre. Abu Dhabi (United Arab Emirates).
- Tibary, A. and A. Anouassi. 2001. Retrospective study on an unusual form of ovario-bursal pathology in the camel (*Camelus dromedarius*). *Theriogenol.* 56:415-424.