



CEST MRI to contrast chondrosarcoma tumors: two contrasts in one acquisition

Leslie Mazuel, Roxane Autissier, Eric Maubert, A. Voissiere, Valérie Weber-Haddad, Gérard You, S. Besse, J.-M. Bonny, Elisabeth Miot-Noirault, C. Peyrode, et al.

► To cite this version:

Leslie Mazuel, Roxane Autissier, Eric Maubert, A. Voissiere, Valérie Weber-Haddad, et al.. CEST MRI to contrast chondrosarcoma tumors: two contrasts in one acquisition. 13. European Molecular Imaging Meeting, Mar 2018, San Sebastián, Spain. hal-02733597

HAL Id: hal-02733597

<https://hal.inrae.fr/hal-02733597>

Submitted on 2 Jun 2020

HAL is a multi-disciplinary open access archive for the deposit and dissemination of scientific research documents, whether they are published or not. The documents may come from teaching and research institutions in France or abroad, or from public or private research centers.

L'archive ouverte pluridisciplinaire **HAL**, est destinée au dépôt et à la diffusion de documents scientifiques de niveau recherche, publiés ou non, émanant des établissements d'enseignement et de recherche français ou étrangers, des laboratoires publics ou privés.

CEST MRI to contrast chondrosarcoma tumors: two contrasts in one acquisition

L. Mazuel^{1, 2}, R. Autissier^{1, 2}, E. Maubert¹, A. Voissière¹, V. Weber¹, Y. Gérard¹, S. Besse¹, J. M. Bonny², E. Miot-Noirault¹, C. Peyrode¹, G. Pages²

¹ INSERM, UMR1240, Clermont-ferrand, France

²AgroResonance, UR370 QuaPA-INRA, F-63122 Saint-Genès-Champanelle, France

Introduction:

Chondrosarcoma is a malignant cartilage tumor and represents the second most common primary malignant solid tumor of bone. It accounts for approximately 25% of all bone sarcomas (Bertoni et al. 2002). Poorly vascularized and rich in proteoglycans (PG), chondrosarcomas are considered to be chemo- and radio-resistant with efficient treatment usually limited to surgical resection with large disease-free margins. If the hypoxic and proteoglycan status of the tumor can be assessed by TEP imaging and scintigraphy, it requires however 2 separated exams.

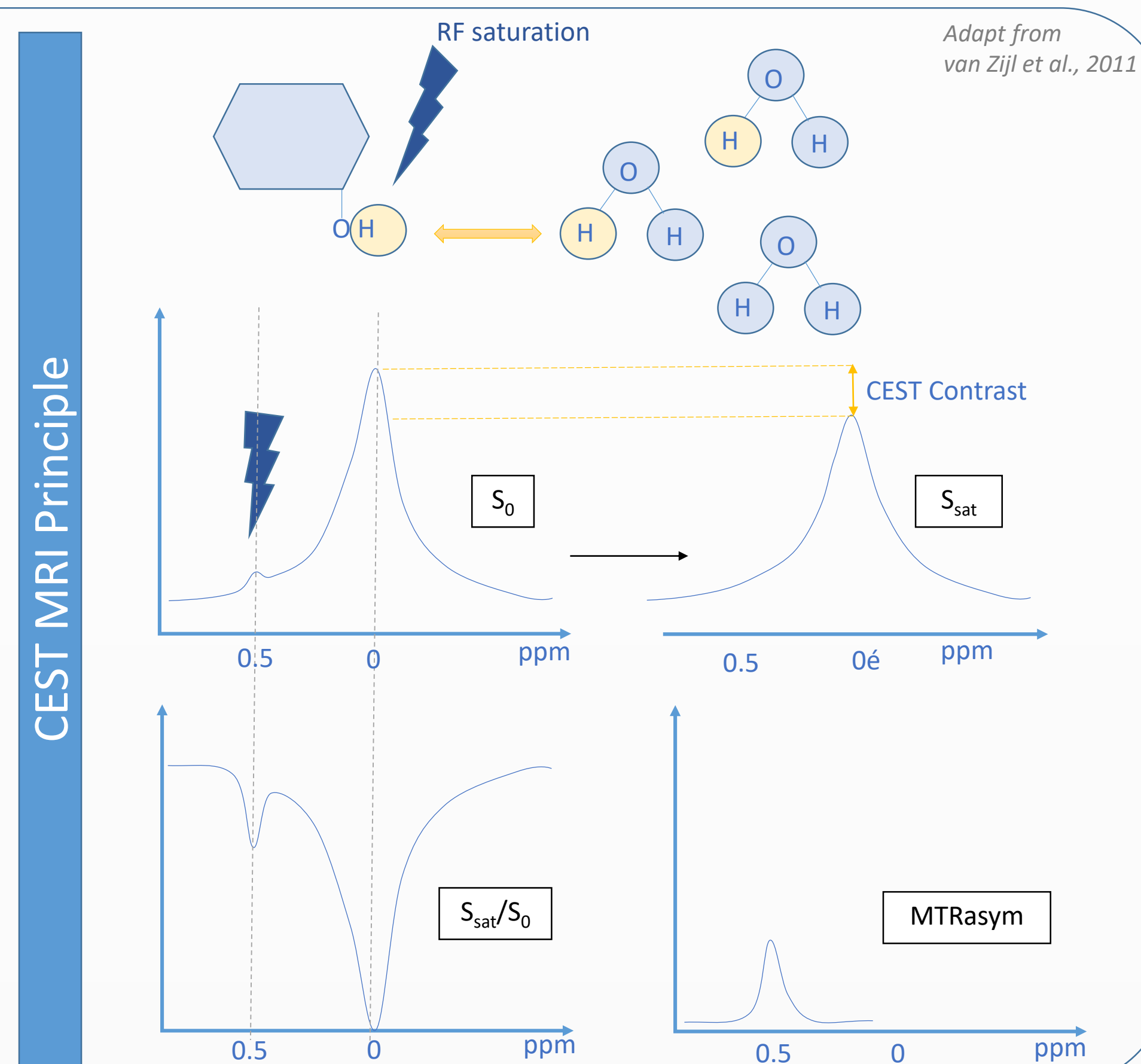
In this context we propose to develop an MRI strategy based on Chemical Exchange Saturation Transfer (CEST) to simultaneously co-register both hypoxia (pH) and PGs content in vivo.

Materials and methods:

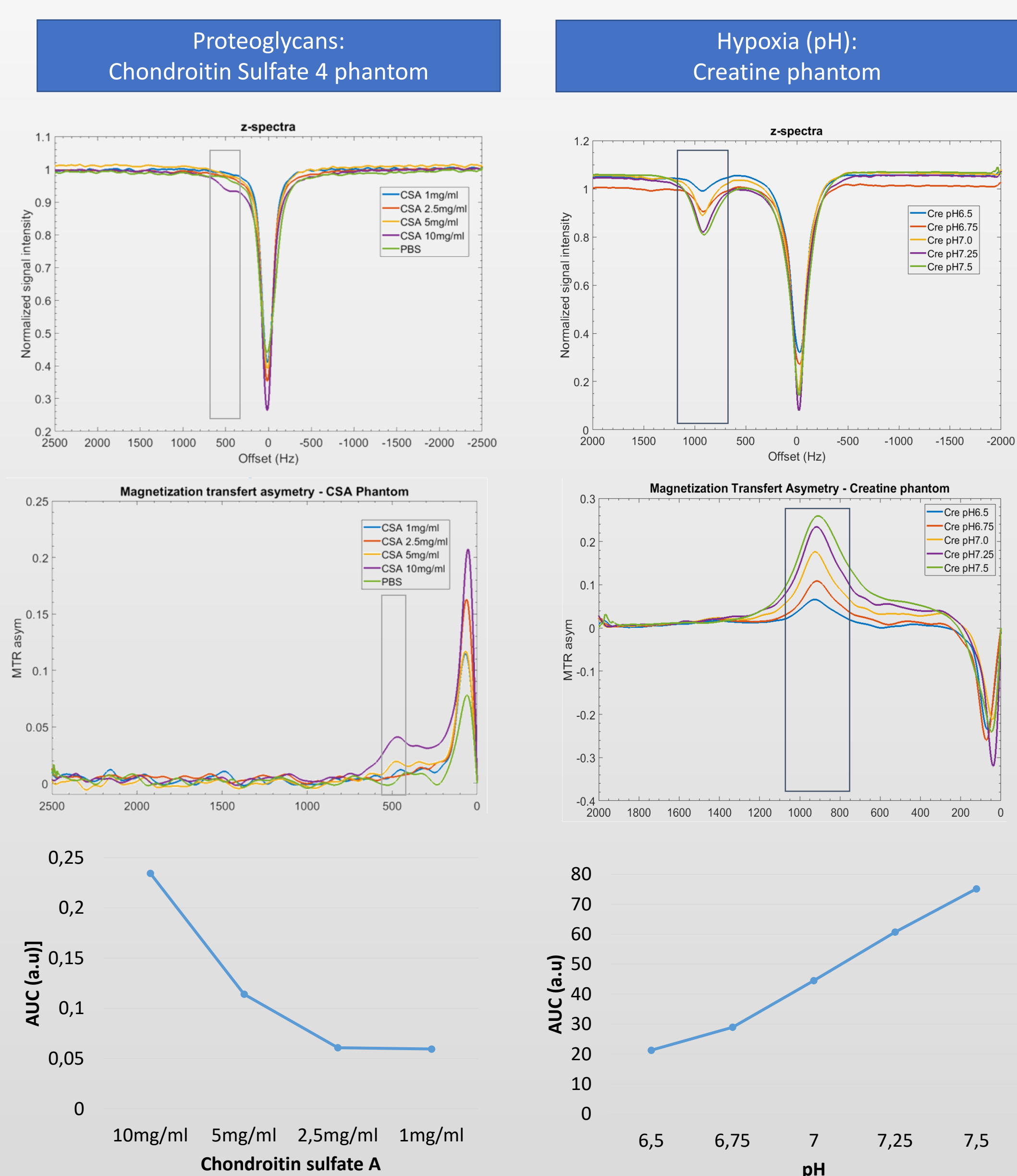
In vitro phantom: The work hypotheses were tested in phantoms containing chondroitin sulfate A (CSA) (1, 2.5, 5, 10 20, 40mM) or creatine (pH 6.5, 6.75, 7.0, 7.25, 7.5) to validate PGs and pH imaging, respectively.

In vivo model of chondrosarcoma: Nude NMRI mice (n=6) aged 4–5 weeks old were implanted with human chondrosarcoma HEMC-SS xenograft (3×10^6 cells in 50 μ L PBS) in para tibial position. After 8 weeks growth xenograft were characterized in terms of proteoglycan content and hypoxia by CEST MRI. *In vivo* imaging was performed on anesthetized mice (1.5% isoflurane in air/O₂ 70/30, v/v, mixture).

MRI protocol: MRI images were acquired at 11.7 T using a 40-mm quadratic volume coil. DWI was first performed to localize the tumor, then WASSR ($B_1=0, 1\mu$ T for 1.5s, $\Delta\omega_{sat}=\pm 1000$ Hz in 20Hz steps) and CEST Z-spectra ($B_1=1.5\mu$ T for 4s, $\Delta\omega_{sat}=\pm 3000$ Hz in 50Hz steps) were acquired based on a RARE protocol. Data were analyzed using an in-house program written in Matlab®R2017a. After correction for B0 inhomogeneity, the CEST maps were generated.



Results in vitro :

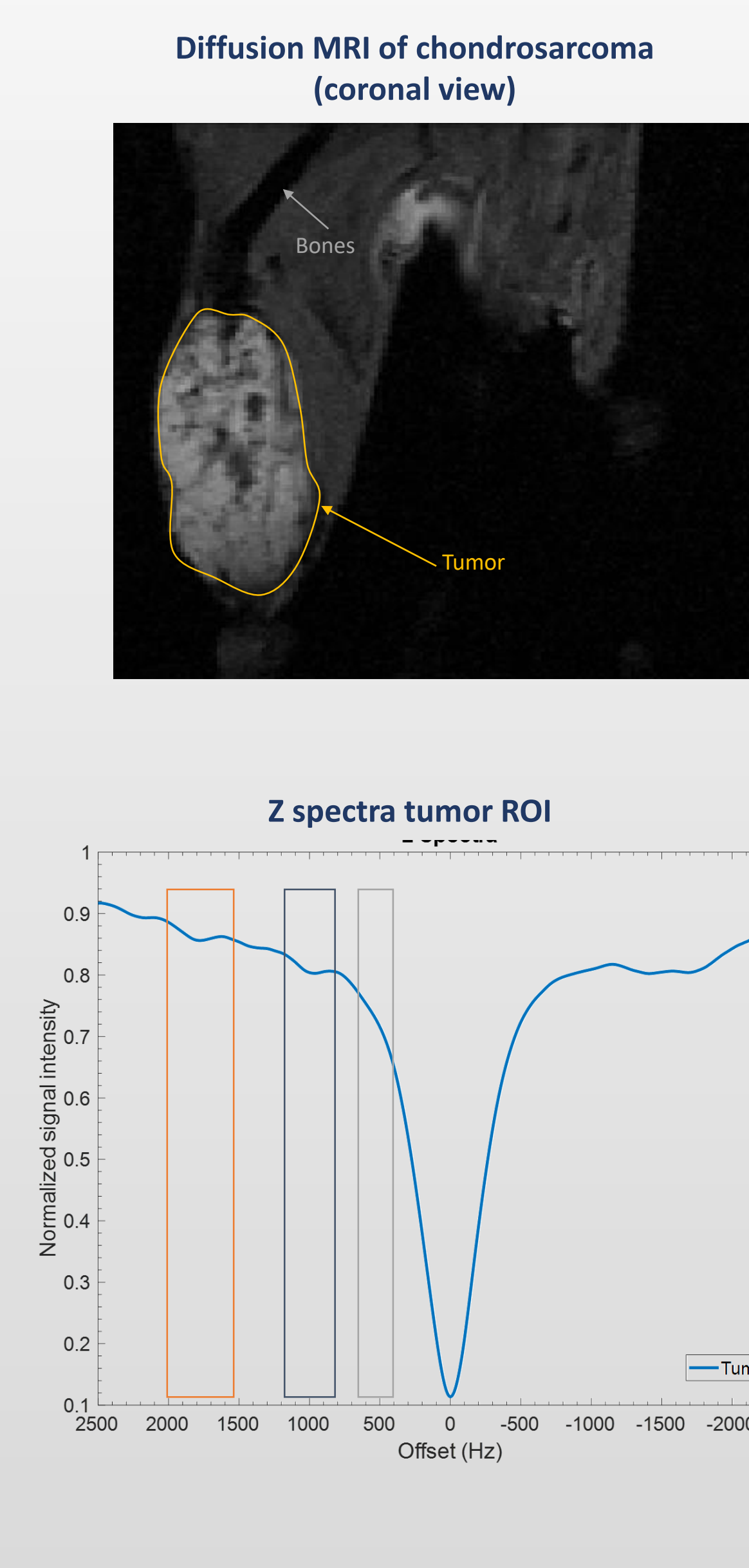


Variations in PG concentration and in pH were observed *in vitro* by CEST MRI by monitoring the magnetization transfer ratio asymmetry at 450 (-OH) and 1000Hz (-NH), respectively.

Discussion – Conclusion

CEST MRI can be used as a new strategy for non-invasive assessment of chondrosarcoma. Indeed, **CEST MRI offers the possibility to image in the same exam the 2 main characteristics of this tumor: pH and PG content.** CEST MRI allows identifying and **differentiating zones of hypoxia *in-vivo***. In the next step, comparison with other MRI techniques such as ²³Na MRI (PGs contain) and ³¹P MRS (pH) as well as nuclear imaging such as ¹⁸F-MISO and ^{99m}Tc-NTP15.5 will be done in order to validate the procedure.

Results in vivo :



In vivo results showed an asymmetry at 500Hz in the chondrosarcoma. **This asymmetry is expected as during the pathology development the PG concentration increases.** *In vivo*, we also observed changes in asymmetry at 1000Hz (amine group) and 1800Hz (amide group) inside the chondrosarcoma. These variations are associated **with acidosis in the hypoxic status** within chondrosarcoma

Contact: leslie.mazuel@uca.fr

Acquisitions were performed at AgroResonance, an entity of IVIA multimodal platform.