



**HAL**  
open science

## **CEST MRI to contrast chondrosarcoma tumors: two contrasts in one acquisition**

Leslie Mazuel, A. Voissiere, Valérie Weber, Yvain Gerard, Sophie Besse, J.-M. Bonny, Elisabeth Miot-Noirault, C. Peyrode, Guilhem Pages

### ► **To cite this version:**

Leslie Mazuel, A. Voissiere, Valérie Weber, Yvain Gerard, Sophie Besse, et al.. CEST MRI to contrast chondrosarcoma tumors: two contrasts in one acquisition. ISMRM 2018, Jun 2018, Paris, France. 2018. hal-02736532

**HAL Id: hal-02736532**

**<https://hal.inrae.fr/hal-02736532v1>**

Submitted on 2 Jun 2020

**HAL** is a multi-disciplinary open access archive for the deposit and dissemination of scientific research documents, whether they are published or not. The documents may come from teaching and research institutions in France or abroad, or from public or private research centers.

L'archive ouverte pluridisciplinaire **HAL**, est destinée au dépôt et à la diffusion de documents scientifiques de niveau recherche, publiés ou non, émanant des établissements d'enseignement et de recherche français ou étrangers, des laboratoires publics ou privés.



JOINT ANNUAL MEETING  
ISMRM–ESMRMB  
16–21 June 2018

SMRT 27<sup>th</sup> Annual Meeting 15–18 June 2018  
[www.smrt.org](http://www.smrt.org)

Paris Expo Porte de Versailles  
Paris, France

# Declaration of Financial Interests or Relationships

Speaker Name: Leslie MAZUEL

I have no financial interests or relationships to disclose with regard to the subject matter of this presentation.

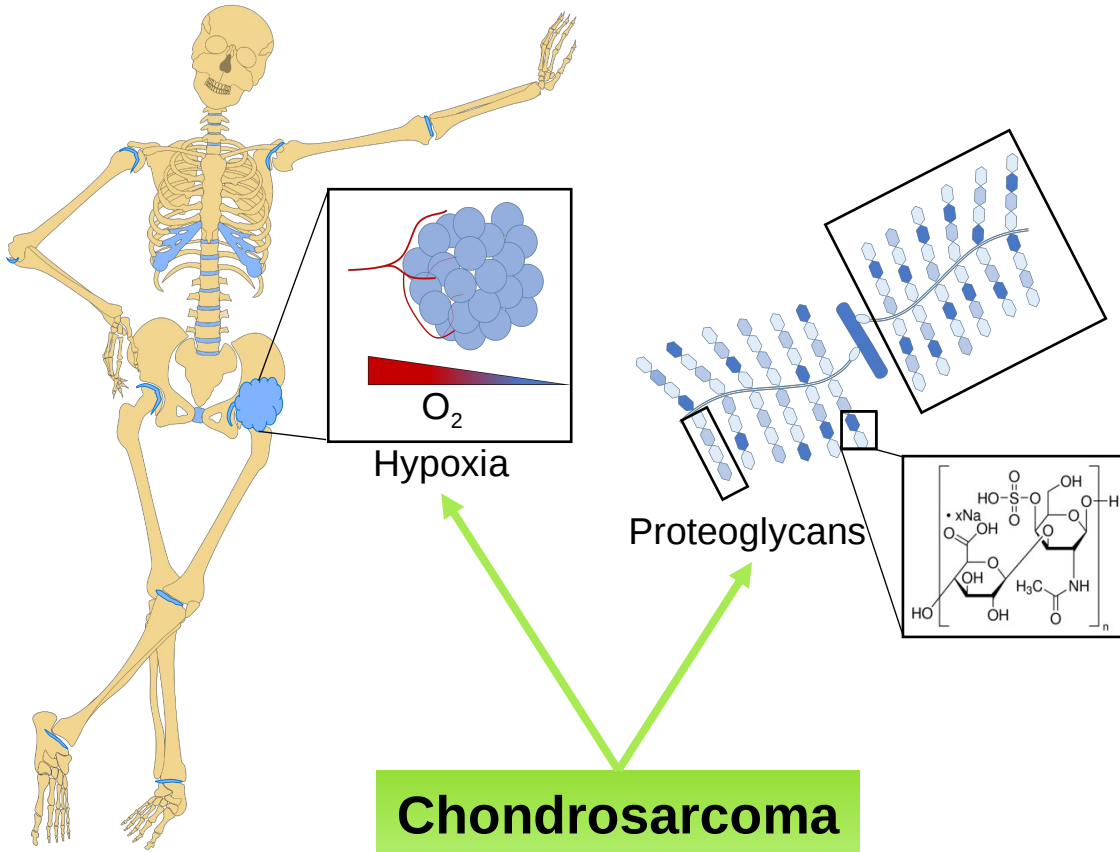
# CEST MRI to contrast chondrosarcoma tumors: two contrasts in one acquisition

L. Mazuel<sup>1,2</sup>, R. Autissier<sup>1,2</sup>, E. Maubert<sup>1</sup>, V. Weber<sup>1</sup>, J. M. Bonny<sup>2</sup>, E. Miot-Noirault<sup>1</sup>, C. Peyrode<sup>1</sup>, G. Pages<sup>2</sup>

<sup>1</sup> INSERM, UMR1240, Clermont-ferrand, France

<sup>2</sup>AgroResonance, UR370 QuaPA-INRA, F-63122 Saint-Genès-Champanelle, France

# Pathological Context



- **Malignant cartilage tumor**
- **2<sup>nd</sup> bone cancer**
- **Diagnostic by imaging**

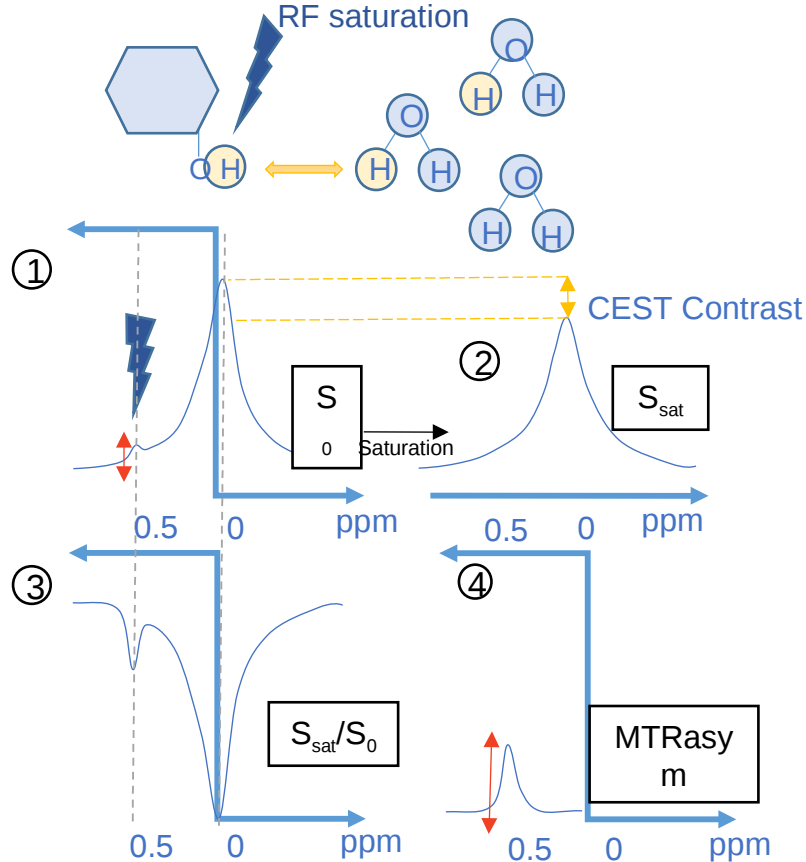


- no specific method

- 2 mains characteristics :
  - Hypoxia

**Could be used to develop a new imaging strategy?**

# CEST MRI principle



Functions

Frequency

Hydroxyl (OH)

250 - 750 Hz

Amines (NH<sub>2</sub>)

800 - 1400 Hz

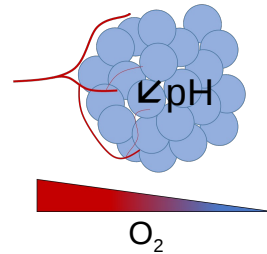
Amides (NH)

1500 - 2100 Hz

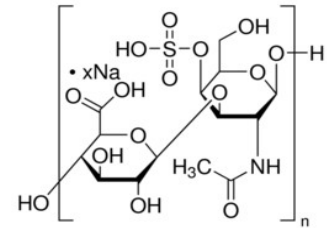
APT CEST

GAG CEST

**Hypoxia**



**Proteoglycan**



**CEST-MRI should be able to simultaneously image both properties**

# In vivo study – Experimental design

## H-EMC-SS Model

3M cells H-EMC-SS  
Implanted orthotopically (tibia)

Human Chondrosarcoma

7 weeks



## Swarm Model

Rat Chondrosarcoma

Swarm tumor implanted sub-cutaneously

2 weeks

**CEST MRI**

PET

$^{18}\text{F}$ -MISO

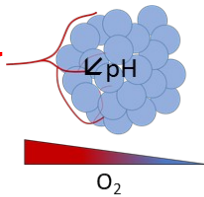
SPECT

$^{99\text{m}}\text{Tc}$ -NTP 15-5

MRI

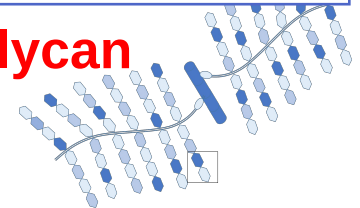
$^{23}\text{Na}$

**Hypoxia**



**Proteoglycans**

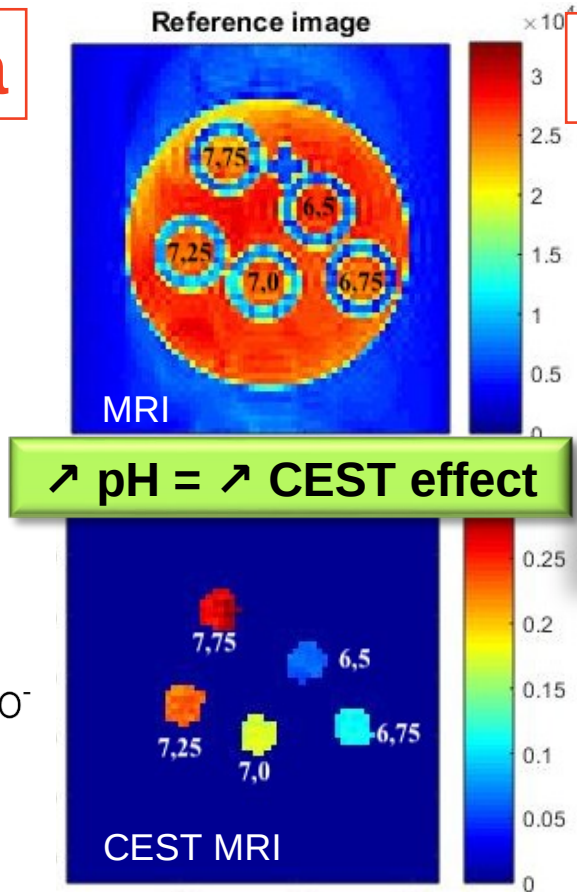
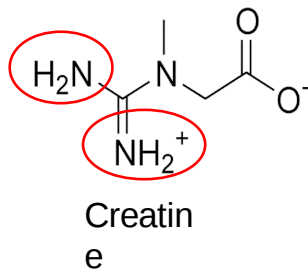
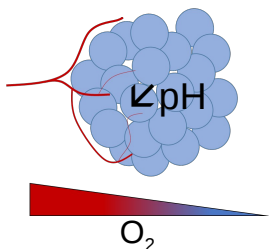
**S**



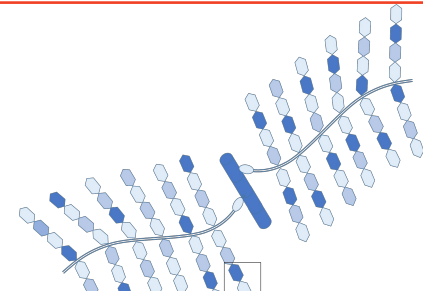
Reference imaging

# CEST MRI *in vitro*

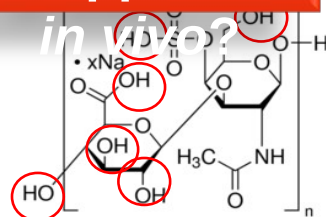
## Hypoxia



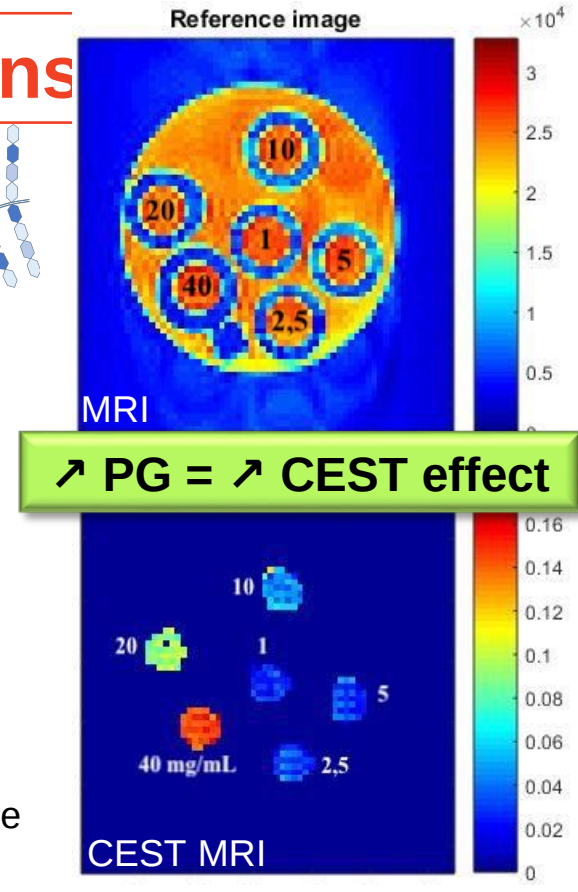
## Proteoglycans



## What happens *in vitro*?



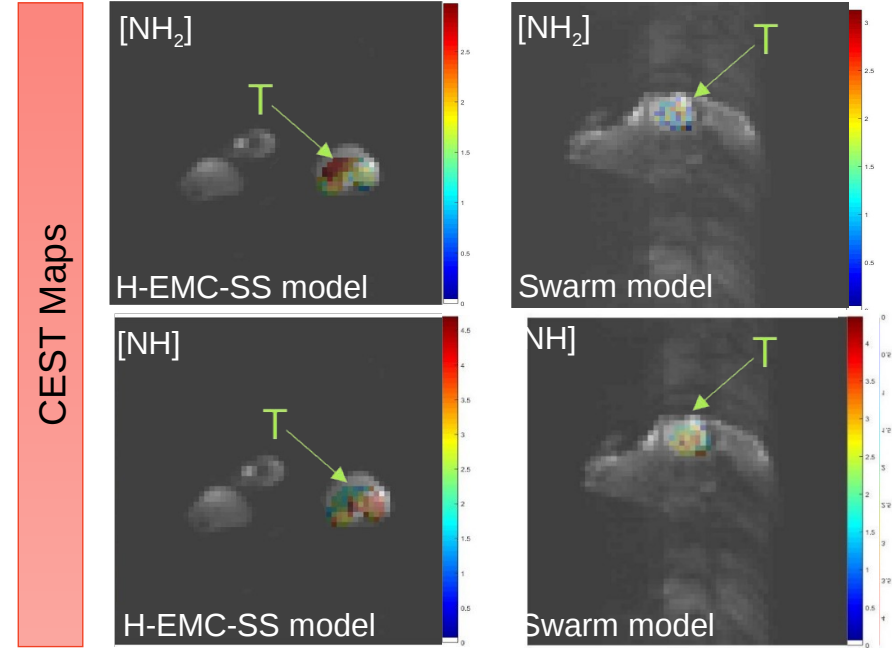
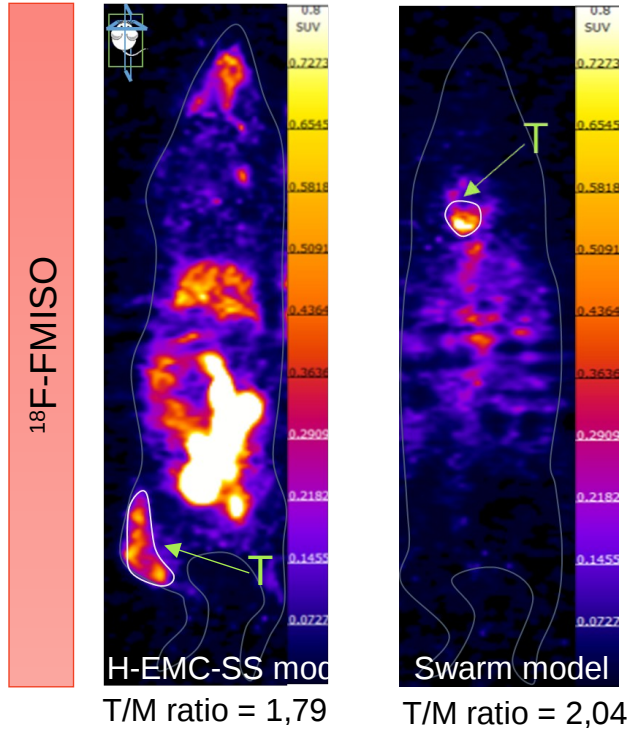
Chondroitin 4 sulfate



# PET

VS

# CEST MRI



The two models are hypoxic

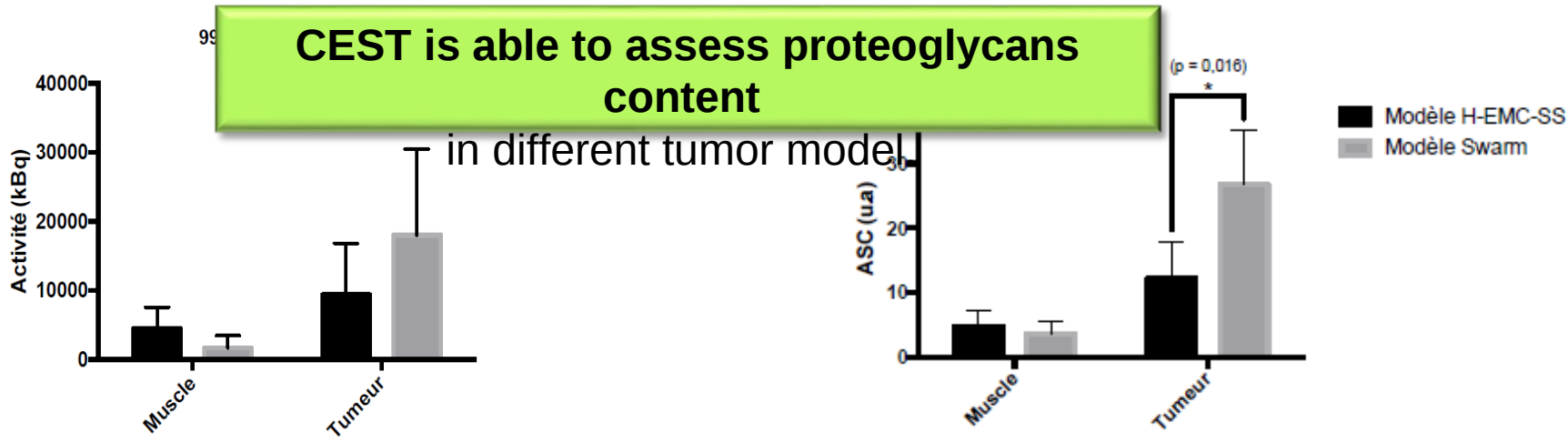
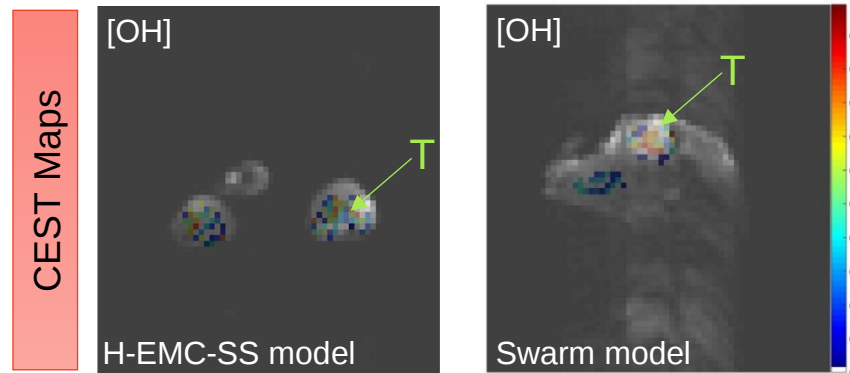
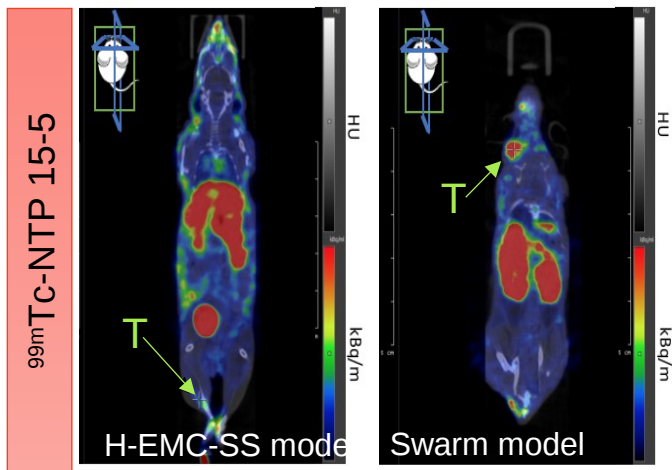
Difference in CEST effect observed in the two different models => difference in pH



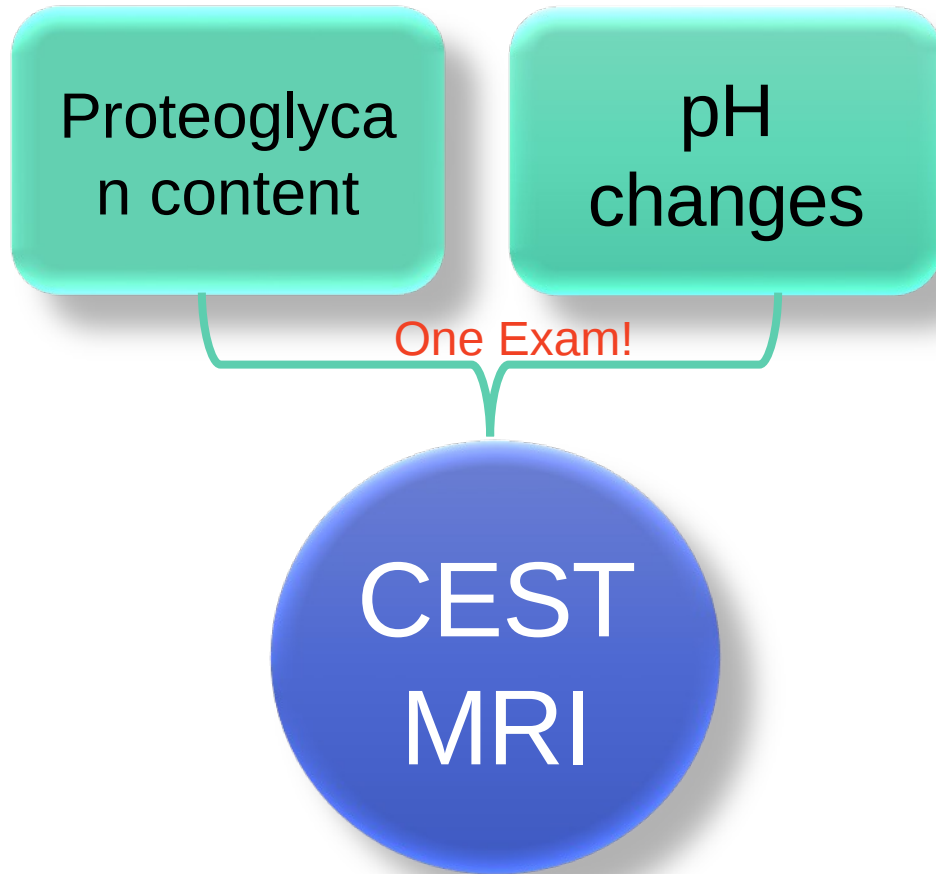
# SPECT

VS

# CEST MRI



# Conclusion - Perspectives



New diagnostic tool  
for  
chondrosarcoma

Therapeutic efficiency  
=> prognostic tool?

The text 'New diagnostic tool for chondrosarcoma' is enclosed in a red-bordered box and tilted. A blue arrow points from the bottom of this box to the text 'Therapeutic efficiency => prognostic tool?'.