



**HAL**  
open science

## Husbandry interventions in suckling piglets, painful consequences and mitigation

Armelle Prunier, N. Devillers, M.S. Herskin, D.A. A Sandercock, A.R.L. R L Sinclair, Céline Tallet, E. von Borell

► **To cite this version:**

Armelle Prunier, N. Devillers, M.S. Herskin, D.A. A Sandercock, A.R.L. R L Sinclair, et al.. Husbandry interventions in suckling piglets, painful consequences and mitigation. The suckling and weaned piglet, Wageningen Academic Publishers, pp.107-138, 2020, 978-90-8686-343-3. 10.3920/978-90-8686-894-0\_4 . hal-02949533

**HAL Id: hal-02949533**

**<https://hal.inrae.fr/hal-02949533v1>**

Submitted on 25 Sep 2020

**HAL** is a multi-disciplinary open access archive for the deposit and dissemination of scientific research documents, whether they are published or not. The documents may come from teaching and research institutions in France or abroad, or from public or private research centers.

L'archive ouverte pluridisciplinaire **HAL**, est destinée au dépôt et à la diffusion de documents scientifiques de niveau recherche, publiés ou non, émanant des établissements d'enseignement et de recherche français ou étrangers, des laboratoires publics ou privés.



Distributed under a Creative Commons Attribution 4.0 International License

## 4. Husbandry interventions in suckling piglets, painful consequences and mitigation

A. Prunier<sup>1\*</sup>, N. Devillers<sup>2</sup>, M.S. Herskin<sup>3</sup>, D.A. Sandercock<sup>4</sup>, A.R.L. Sinclair<sup>4</sup>, C. Tallet<sup>1</sup> and E. von Borell<sup>5</sup>

<sup>1</sup>PEGASE, INRAE, Institut Agro, 35590 Saint Gilles, France; <sup>2</sup>Agriculture and Agri-Food Canada, Sherbrooke Research and Development Centre, 2000 College Street, Sherbrooke, QC, J1M 0C8, Canada; <sup>3</sup>Department of Animal Science, AU Foulum, Aarhus University, Blichers allé 20, 8830 Tjele, Denmark; <sup>4</sup>SRUC, West Mains Road, Edinburgh, EH9 3JG, United Kingdom; <sup>5</sup>Institute of Agricultural and Nutritional Sciences, Martin-Luther-University Halle-Wittenberg, 06108 Halle (Saale), Germany; [armelle.prunier@inrae.fr](mailto:armelle.prunier@inrae.fr)

### Abstract

During their first days of postnatal life, piglets reared for meat production are often subjected to numerous husbandry practices that cause injury of sensitive tissues and hence are potential sources of pain. The intensity and duration of the pain engendered depend on the nature and magnitude of tissue damage. Each of these practices is carried out for specific reasons, such as preventing boar taint (castration), reducing the risk of tail biting (tail docking), limiting lesions on siblings and the sow's teats (tooth resection), improving health (injections) or identifying animals (ear tagging or notching). This chapter will discuss the rationale and methods used, the evidence of pain during and shortly after the procedure, the long-term pain consequences, the consequences for health and human-animal relationships, the current options for pain mitigation and the pros and cons of avoiding these practices completely. Solutions are emerging to minimise the industry's dependence on these practices and, when still considered necessary, to enable selection of the least painful option and best mitigate any residual pain. A better knowledge of the affective component of the pain involved in the practices as well as the establishment of standard and validated protocols of pain evaluation are needed in order to move forward and determine the best solutions from an animal welfare perspective and feasibility by farmers.

**Keywords:** behaviour, castration, stress, tail docking, tooth resection

### 4.1 Introduction

Numerous husbandry practices are routinely applied to very young piglets. They comprise surgical castration in males and tail docking, teeth clipping, injections for iron supply or vaccination, and sometimes ear notching, tagging or tattooing in both sexes (Figure 4.1). All these interventions induce a damage of sensitive tissues and hence are potential sources of acute and, for some of them, persistent or even chronic pain. These procedures are done prophylactically to avoid later problems with boar taint or limit the risks of tail biting or outbreaks of diseases, and thus arguments for the procedures are often based on



Figure 4.1. Image a piglet of 25 days of age that underwent tail docking and tattooing the day after birth and surgical castration at 5 days of age. Photo by Armelle Prunier.

utilitarian ethics. In addition, insensitivity to pain in very young animals has historically been used as an argument to carry out painful procedures at this early life stage. However, the weight of scientific evidence now shows that very young piglets, similarly to neonates from other mammalian species, are able to experience pain (EFSA, 2017) even though there may be variations with age in sensitivity to noxious stimuli (Kells *et al.*, 2019).

By definition, pain has sensory and emotional components that are both necessary to diagnose pain (IASP, 2019). Inference about the presence of the emotional component of pain in animals presents significant difficulties because they cannot directly communicate what they feel. One approach is based on the observation of spontaneous animal behaviours in response to potential sources of pain (see reviews by Prunier *et al.*, 2013; Sneddon *et al.*, 2014; Weary *et al.*, 2006), with the limitation that reasons other than pain can often explain the observed changes. Other valuable approaches are based on assessing motivation (Weary *et al.*, 2006, 2017). In recent years, paradigms involving learning originally developed in human psychology, such as conditioned place aversion (Prus *et al.*, 2009), have been used successfully to draw inference about the negative emotional impact of tissue damaging procedures such as disbudding in calves (Adcock and Tucker, 2020). In addition, cognitive bias testing, examining an animal's motivation to perform a task and the tendency to interpret ambiguous information as positive or negative, has been used to draw inference about more long-term changes in affective states of animals after exposing them to tissue damaging management procedures (Neave *et al.*, 2013).

Pain is detrimental to the welfare of pigs, it is therefore essential to determine precisely the consequences of the various husbandry interventions applied. In addition, knowledge about possibilities to suppress these interventions or, when unavoidable, about the least

painful intervention available when several possibilities exist for the same purpose (e.g. clipping and grinding for tooth resection) are greatly needed. Finally, if a painful procedure cannot be avoided, the possibilities to mitigate the pain using an analgesic or anaesthetic treatment should be clarified. This knowledge will allow producers to apply to pig production the '3S' approach accounting for 'Suppress, Substitute and Soothe' developed by Guatteo *et al.* (2012) that parallels the '3R' approach 'Reduction, Refinement and Replacement' developed in the context of animal experimentation. In the present chapter, we examine successively surgical castration, tooth resection, tail docking and other painful husbandry practises and discuss why and how these practices are performed, what is the evidence of pain on a short and long term basis, what are the possibilities to mitigate this pain and what are the pros and cons of avoiding these practices.

## 4.2 Surgical castration of piglets

### 4.2.1 Why and how this practice is performed

Across the world, most male piglets still undergo surgical castration. For example, nowadays in China nearly all pigs are surgically castrated (Xue *et al.*, 2019), and in 2015 in the EU-24 61% of male piglets were surgically castrated (De Briyne *et al.*, 2016). The main reasons are rearing less aggressive animals, avoiding pregnancy if males are housed with females and, more importantly, avoiding boar taint (e.g. unpleasant odours and flavours of entire male pig meat) (EFSA, 2004). Surgical castration of male piglets is performed during the first days or weeks after birth. It is a rapid process that may take less than 30 seconds, including the time for catching the animal, if no pain mitigation is performed. Piglets are restrained during surgery to minimize movements (Figure 4.2). One or two incisions of about 2 cm are made through the scrotum and surrounding tissues are trimmed to free each testicle. Thereafter, each testis is extracted and removed

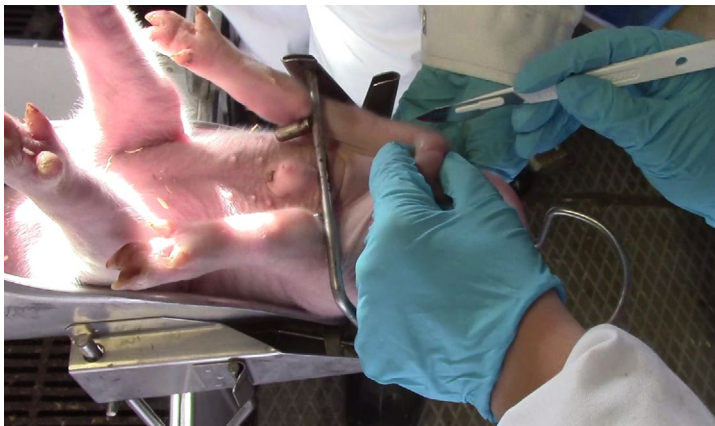

Figure 4.2. Image of a piglet restrained for surgical castration. Photo by Mathilde Coutant.

by tearing the tissues or by cutting the spermatic cord (*funiculus spermaticus*) with a scalpel or an emasculator that clamps and crimps the cord to limit bleeding. All tissues that are damaged during surgical castration are highly innervated (EFSA, 2004), hence, surgical castration is painful. To mitigate this pain, a treatment can be performed (see below). In order to limit the risk of infection, an antiseptic treatment can be applied on the skin before surgery and/or on the wound after castration. In addition, an antibiotic can be injected. A recent survey in Europe reported that antibiotics are regularly, but not systematically, used and that there are differences in the frequency of their administration between and within countries (Castrum consortium, 2016).

#### **4.2.2 Evidence of pain during and in the hours and days after surgical castration**

A large number of experiments have been devoted to the assessment of pain in piglets that have undergone surgical castration. They gave rise to several literature reviews (Ison *et al.*, 2016; Prunier *et al.*, 2006, 2020; Rault *et al.*, 2011; Sutherland, 2015; Von Borell *et al.*, 2009) showing that during surgery and shortly after, castration induces severe pain. This is illustrated by changes in the electrical activity of the brain (e.g. a decrease in the absolute theta power during surgery that is less marked in piglets if local anaesthesia is performed (Haga and Ranheim, 2005)), in the activation of the neuroendocrine systems linked with the stress response (e.g. increased plasma catecholamines, cortisol, and adrenocorticotrophic hormone (ACTH) (Prunier *et al.*, 2005, 2006; Carroll *et al.*, 2006)), and in numerous behavioural changes occurring during surgery (e.g. more defensive movements and high-pitched vocalizations) and the following hours (more isolation, lack of behavioural activity while awake, and rump scratching (Hay *et al.*, 2003; Marchant-Forde *et al.*, 2009; Marx *et al.*, 2003)).

However, the longer-lasting effects of castration on pig welfare in the days following surgery remain uncertain because very few studies investigated these effects and they used very different protocols. For instance, only one study (Marsalek *et al.*, 2011) out of the four (Carroll *et al.*, 2006; Marchant-Forde *et al.*, 2009; Sutherland *et al.*, 2012) measuring plasma cortisol concentrations at 24 and/or 48 hours after surgery, observed an increase in castrated males. In a study involving 28 castrated and 56 non-castrated male piglets, Hay *et al.* (2003) found that castrated piglets were more frequently desynchronized (activity different from that of most littermates) on the 1<sup>st</sup> day after castration, scratched their rump more frequently on the soil until the 4<sup>th</sup> night after castration, and were huddling (lying with at least three legs tucked under the body), wagging their tail, kneeling, and walking more frequently until the 4<sup>th</sup> day after castration. The effect of castration on some behaviours (e.g. desynchronization or being awake but inactive) was sometimes opposite from one day to the next suggesting the existence of rebound effects and making results difficult to interpret when animals are not observed at regular time intervals. In another study with observations ending on the 3<sup>rd</sup> day after castration, the only differences found were less dog sitting on the 3<sup>rd</sup> day and more isolation (no contact with the sows and littermates) from the 1<sup>st</sup> to the 3<sup>rd</sup> day in castrates (Llamas Moya *et al.*, 2008). In four other studies ending on the 1<sup>st</sup> day after castration, more rump scratching and tail wagging (Courboulay *et al.*, 2010), or more combined abnormal behaviours (sum of spasms, rump

#### 4. Husbandry interventions in suckling piglets, painful consequences and mitigation

scratching, stiffness, huddling, and prostration (Hansson *et al.*, 2011), and sum of spasms, rump scratching, stiffness, trembling and tail wagging (Viscardi and Turner, 2018a,b) were depicted in castrated males on the day after castration. These abnormal behaviours were attenuated by an analgesic treatment in three out of these four studies. Contrarily, some authors failed to demonstrate any influence of surgical castration on behaviour on the day after castration (Yun *et al.*, 2019) or from the 1<sup>st</sup> until the 4<sup>th</sup> day after castration (Kluivers-Poodt *et al.*, 2013). Therefore, it is likely that piglets without appropriate pain relief experience pain in the days following surgery, but that the pain intensity decreases and its signs become harder to observe with time.

In summary, if the behavioural and physiological signs of pain during surgical castration and shortly after are very clear, they are not well demonstrated from the day after surgery. It should be remembered that the number of studies decreases as the time interval from surgery increases and that it is difficult to demonstrate the existence of pain in pigs by observing only their spontaneous behaviours. For example, using a model of post-operative pain inflicted on pigs at about 7 weeks of age, Castel *et al.* (2014) demonstrated hyperalgesia around the wound until 7 days after surgery with a test based on the withdrawal reaction to pressure. On the other hand, an increase in spontaneous behaviours potentially related to pain (e.g. restlessness, isolation, moving away when approached and vocalization) was seen at 1 and 3 hours post-surgery but not later on in the same study (Castel *et al.*, 2014).

##### 4.2.3 Mitigation of pain due to surgical castration

Taking into account the duration of the pain induced by castration, mitigating pain during the procedure itself should be combined with the use of an analgesic having a prolonged effect for at least one day. As it is performed on farm, the method needs to be cheap, easy to run, and without risk for people and animals' health. In addition, it should respect the national regulations that (a) restrict the use of drugs on animals reared for human consumption in order to limit residues in food, and (b) may allow the use of these drugs only by veterinarians.

Two surveys performed in 2015 (De Briyne *et al.*, 2016) and 2016 (Castrum consortium, 2016) in Europe showed that approximately half of the surgically-castrated pigs received a treatment to mitigate pain, and that this treatment varies between and within countries. General anaesthesia by inhalation of CO<sub>2</sub>/O<sub>2</sub> (e.g. in the Netherlands) or isoflurane (Switzerland), or by injection of ketamine (e.g. in Germany) is one option. Sometimes, sedation with azaperone is performed, either alone or in combination with general anaesthesia. Local anaesthesia using lidocaine or procaine injected subcutaneously (e.g. in Hungary), intratesticularly (e.g. in Sweden and Denmark), or both subcutaneously and intratesticularly (e.g. in Norway), is another option. A prolonged analgesia with a non-steroidal anti-inflammatory drug (NSAID) such as flunixin (e.g. in Austria), meloxicam (e.g. in France), or ketoprofen (e.g. in Denmark), is often performed either alone (e.g. in France) or in combination with a local (e.g. in Sweden and Denmark) or general (e.g. in the Netherlands) anaesthesia. Less often, metamizole (also called dipyrone), a non-opioid

pyrazolone derivative, is used for analgesia (e.g. in Slovenia). Very rarely, butorphanol, an opioid derivative, is used (in Switzerland).

General anaesthesia suppresses activity of the central nervous system and results in unconsciousness and loss of sensation. Therefore, pain is mitigated during the surgery and until the pig wakes up. In the case of CO<sub>2</sub>/O<sub>2</sub> anaesthesia, piglets are placed in boxes or in a specific device and inhale a mixture of CO<sub>2</sub>/O<sub>2</sub> for at least 30 seconds, leading to unconsciousness for approximately 1 minute while castration is performed, and piglets are then placed back into the home pen where they can rapidly recover (Gerritzen *et al.*, 2008). Using isoflurane requires more expensive and advanced equipment. Piglets are placed in a specific device and inhale the gas for approximately 90 seconds, until they lose consciousness and are castrated (Walker *et al.*, 2004). Recovery from anaesthesia takes about the same time as after CO<sub>2</sub>/O<sub>2</sub> and piglets can be rapidly moved back to their home pen. In optimized conditions, duration and depth of anaesthesia are satisfactory with both gases (Gerritzen *et al.*, 2008; Walker *et al.*, 2004). However, the use of CO<sub>2</sub>/O<sub>2</sub> is questionable since it is strongly disliked by the animals and the safety margin between anaesthesia and death is narrow (O'Connor *et al.*, 2014). A survey on the use of isoflurane in Switzerland indicated that 14% of the piglets were insufficiently anaesthetized (Enz *et al.*, 2013b). The authors also reported more bleeding after castration and thus recommended the use of an emasculator. With the narcotic drug ketamine and/or the neuroleptic drug azaperone, duration and depth of anaesthesia are much less satisfactory. Furthermore, the long sleep period (up to several hours) after ketamine administration reduces the suckling time and therefore increases the risk of potentially fatal hypothermia in piglets (Enz *et al.*, 2013a).

Local anaesthesia blocks transmission of certain nerve impulses between a targeted part of the body and the central nervous system, causing loss of pain sensation in the targeted body part. The most painful part of the castration has been shown to be the tearing and cutting of the spermatic cord (Taylor and Weary, 2000). To reduce this pain, an injection directly into the spermatic cord (intrafunicular injection) or indirectly into the testicles is efficient (Haga and Ranheim, 2005). Therefore, the most common routes of injection of a local anaesthetic are intratesticular, subcutaneous, and intrafunicular, or a combination of those. Two local anaesthetics are commonly used, procaine and lidocaine, the second having a faster onset and longer duration of action. When used properly, local anaesthesia with lidocaine alleviates, but does not fully remove, pain during surgical castration (e.g. Hansson *et al.*, 2011; Kluivers-Poodt *et al.*, 2012; Marx *et al.*, 2003). Local anaesthesia with procaine has only been examined in a few non-peer reviewed studies, but seems less efficient (Courboulay *et al.*, 2018; Hofmann *et al.*, 2019). Some pain due to the local anaesthesia itself is suspected, though its intensity is lower than that due to surgical castration, as suggested by a lower EEG response to lidocaine injected either in the testes or in the spermatic cord than to cutting the spermatic cord (Haga and Ranheim, 2005). In addition, when pigs received an intra-testicular injection of lidocaine, a first increase in cortisol and ACTH was observed but it was of lower amplitude than the second increase due to surgical castration, and of much lower amplitude than the increase observed in surgically castrated pigs receiving no pain treatment (non-peer reviewed study: Prunier *et al.*, 2002).

#### 4. Husbandry interventions in suckling piglets, painful consequences and mitigation

The NSAIDs are inhibitors of cyclooxygenase enzymes that are central to the production of prostaglandins. They act on pain essentially at the peripheral level by reducing inflammation (e.g. meloxicam) or at both peripheral and central levels (e.g. ketoprofen). Numerous studies were conducted to determine their effectiveness in mitigating castration-related pain in pigs (Dzikamunhenga *et al.*, 2014; O'Connor *et al.*, 2014; Schoos *et al.*, 2019). Many of these studies used plasma cortisol as an indirect pain indicator which is questionable if it is not associated with behavioural indicators of pain (Dzikamunhenga *et al.*, 2014). A reduction in castration-induced behaviours (e.g. prostration, trembling, tail movements, rump scratching, head low or isolation) was depicted in the first hours after surgical castration in piglets receiving meloxicam before surgery in several studies (Keita *et al.*, 2010; Kluivers-Poodt *et al.*, 2013; Langhoff *et al.*, 2009; Tenbergen *et al.*, 2014) but not in all (Hansson *et al.*, 2011; Reiner *et al.*, 2012; Viscardi and Turner, 2018b), and an effect was still present the day after castration only in one study (Hansson *et al.*, 2011) but not in the others (Kluivers-Poodt *et al.*, 2013; Reiner *et al.*, 2012; Viscardi and Turner, 2018b). Fewer studies have investigated the effectiveness of ketoprofen and flunixin. No positive effect on behaviour of a pretreatment with flunixin was observed by Reiner *et al.* (2012), contrary to findings of Langhoff *et al.* (2009) who observed less tail wagging and less position changes in the hours following castration in piglets receiving flunixin. Only a reduction in tail wagging, usually considered as an indicator of castration-related pain, was depicted the day after surgery by Courboulay *et al.* (2010), whereas no effect was depicted by Viscardi and Turner (2018b).

Butorphanol inhibits pain at the central level and should be effective to relieve acute pain even during surgery. Positive effects on behaviour during and shortly after surgical castration were observed by Courboulay *et al.* (2015), but use of this drug was discarded by Viscardi and Turner (2018a) and Hug *et al.* (2018) due to unacceptable side effects (e.g. vomiting, trembling, leg paddling). Metamizole inhibits pain both at the peripheral and central levels, but no clear effects on behaviour were observed despite an attenuation in the post-castration increase in cortisol (Langhoff *et al.*, 2009).

Due to a lack of standardization in the protocols of pain evaluation, it is very difficult to compare the efficacy of the various treatments proposed to mitigate pain from surgical castration and hence to make precise recommendations (Dzikamunhenga *et al.*, 2014; O'Connor *et al.*, 2014). However, due to limited safety margins, handling stress, efficacy and practicability, some methods such as local or isoflurane-inhalation anaesthesia combined with an analgesic pre-emptive treatment (e.g. meloxicam) may be more appropriate in terms of effectiveness, risks, and drawbacks compared to CO<sub>2</sub>/O<sub>2</sub> inhalation or ketamine/azaperone-injection anaesthesia. Finally, even if these multimodal methods mitigate pain, the stress and pain due to surgical castration are not fully eliminated.

#### 4.2.4 Long term consequences of surgical castration

Investigations into potential long-term neuropathic pain due to surgical castration are currently lacking in pigs. While castration is primarily associated with soft tissue injury, it does involve complete transection of the testicular nerves. These nerves innervate many structures within the testes and scrotum and contain thousands of somatosensory



neurons, and a significant proportion of these are primary nociceptive afferent neurons responsible for the detection and conduction of pain signals (Woolf and Ma, 2007). One of the consequences of castration-associated nerve resection is the development of traumatic neuromas in the regenerating proximal part of the severed testicular nerves. Traumatic neuromas are formed by multiple sprouting axons whose growth is directed towards the distal part of the severed nerve. These sprouting axons proliferate to form a disorganised bundle of neurons, Schwann cells and connective tissue, that can be circumscribed by fibrous tissues or widely dispersed within the extra-endoneural environment (Foltan *et al.*, 2008). In humans, traumatic neuromas can be associated with episodic and, in some cases, persistent pain (Rajput *et al.*, 2012). Neuroanatomical studies in horses demonstrated the presence of traumatic neuromas in the remnant testicular nerves at the site of castration (Bengtsson *et al.*, 2019). These authors proposed that inguinal pain, unexplained hind limb lameness, back pain, and behavioural issues in geldings may be attributable to painful traumatic neuromas, developed as a consequence of crushing and severing the testicular nerves during castration. Evidence of the presence of traumatic neuroma development in the testicular nerves at the site of castration has yet to be confirmed in pigs.

Health issues such as wound healing, infections, spreading of diseases, reduced growth performance, mortality, and suppression of male specific behaviours related to surgical castration have been raised, although there is a very limited number of studies assessing these potential consequences. A field study by Hawkins and Strobel (2012) suggested that the use of an anti-infective wound spray may improve the course of wound healing, whereas Sutherland *et al.* (2012) reported that wound healing scores were not boosted by flunixin injected at the time of castration. The incidence of wound healing problems logically increases with age of the piglets at the time of castration (e.g. 28 vs 3 days of age; Sutherland *et al.*, 2012). They are more significant in the context of non-septic conditions during castration and when using improperly cleaned and disinfected anaesthesia equipment (e.g. inhalation gas machines shared by several farms; Aluwé *et al.*, 2016). The mortality of castrated male pigs during lactation did not seem to differ from that of females (McGlone *et al.* 1993) or intact males (Bonastre *et al.*, 2016; Kluivers-Poodt *et al.*, 2012) on experimental farms. However, on commercial farms, Morales *et al.* (2017) reported differences between castrated and intact males but that depended on piglet live weight at birth. The 25% lightest and 50% medium weight piglets had a mortality rate that doubled when castrated, whereas the 25% heaviest piglets had a slightly slower growth rate during lactation when castrated. A meta-analysis of 15 studies involving immuno-castrated and surgically castrated males confirmed that castrated pigs had a higher mortality rate than their intact littermates (Allison *et al.*, 2010). On the other hand, poorer growth performance in grower and finisher castrated pigs are more likely due to sex-specific metabolic factors (e.g. lack of testicular anabolic steroids leading to lower feed efficiency and growth potential of feed-restricted castrated males) than to chronic influences resulting from the castration procedure itself. Whereas castration may prevent some of the aggressive and male specific behaviours (e.g. mounting, penis biting) in intact boars that usually result in injuries, castrated males seem more prone to being tail bitten. Indeed, it was reported that castrates were more likely to be tail bitten than females (Kritas and Morrison, 2004; 2007; Wallgren and Lindahl, 1996), with the

#### 4. Husbandry interventions in suckling piglets, painful consequences and mitigation

risk to males increasing with the proportion of females in the pen (Kritas and Morrison, 2004). However, to the best of our knowledge, there is no comparison between intact and castrated males for the occurrence of tail biting.

In addition, surgical castration seems to modify the pigs' perception of humans. Tallet *et al.* (2013) reported that, when tested in an unfamiliar environment, 81 to 125 days-old castrated pigs spent less time than entire males of the same age in close vicinity to an unfamiliar human. These results suggest that castrated pigs might associate the stress and pain due to castration with human presence, although the ease of handling the animals did not appear to be affected by castration (Tallet *et al.*, 2013). Further investigation is needed on this aspect.

##### 4.2.5 Possible means to avoid surgical castration

In order to avoid surgical castration and its negative consequences on health and welfare of pigs, two main solutions are possible: performing a vaccination that inhibits the testicular activity or raising intact males (Bonneau and Weiler, 2019). Raising intact males is already the rule in some countries (e.g. in the UK and Ireland). For countries where surgical castration is still frequent, this solution implies rethinking the organization of the entire pig production chain, so that boar taint is minimized in live animals and carcasses are sorted and used according to their boar taint level in order to avoid rejection by markets and consumers (Parois *et al.*, 2018).

### 4.3 Tooth resection of piglets

#### 4.3.1 Why and how this practice is performed

Piglets are born with an incisor and a canine tooth present on each side of the upper and lower jaws. These eight teeth are very sharp and can easily damage sows or other piglets. They are milk teeth that are spontaneously shed between 2 and 4 months of age (Hay *et al.*, 2004). From each jaw, four additional milk incisors erupt between 2 and 35 days of age (Tucker and Widowski, 2009). With the aims of limiting lesions on other piglets or the sow's udder, avoiding disturbance of the sow nursing behaviour, and improving growth of the piglets and reducing their mortality, resection of teeth is routinely practiced in many conventional farms across the world. In the EU, this procedure must not be performed on a routine basis (EC, 2001, 2008). However, data from 2008 indicated that most pigs were routinely submitted to tooth resection in most European countries (Fredriksen *et al.*, 2009) and there is no reason to believe that the situation has changed. Similarly, most piglets from large scale farms are submitted to tooth resection in China (Yao Wen, personal communication).

Tooth resection is usually performed in the days following birth, often jointly with other procedures, such as iron injection, tail docking and sometimes castration in male piglets. Typically, all eight milk teeth are resected either with cutting pliers or an electric grinder (tooth abrasion with a stone). The proportion of the tooth removed varies from

a few percent to the whole tooth above the gum line (Fu *et al.*, 2019; Gallois *et al.*, 2005). In nearly all cases, tooth resection leads to damage of the dental pulp (Hay *et al.*, 2004; Hutter *et al.*, 1994) that is highly innervated. Therefore, pain is an expected consequence.

When tooth resection is performed, a reduction in the number and severity of skin lesions in piglets was repeatedly demonstrated whereas the effect on sow udder lesions is inconsistent (Fu *et al.*, 2019; Gallois *et al.*, 2005; Holyoake *et al.*, 2004; Lewis *et al.*, 2005a; Weary and Fraser, 1999). Regarding maternal behaviour, results are also unclear. During the first two days after farrowing, no effect of tooth resection, either by grinding or clipping, was seen on sow posture, number of postural changes or time interval between successive sucklings or between suckling and a sow posture change (Lewis *et al.*, 2005a; Prunier *et al.*, 2004). Later on, sows nursing tooth-clipped piglets terminated fewer suckling bouts on day 4 and exhibited less dog sitting (interpreted as avoidance of suckling attempts) on days 21 and 26 (Lewis *et al.*, 2005a). More recently, Fu *et al.* (2019) did not see any effect of tooth clipping on sow posture or on the percentage of time piglets spent suckling or massaging the udder, when performing regular observations between days 1 and 24 of lactation.

#### 4.3.2 Evidence of pain during and shortly after tooth resection

In 3-day old piglets, an increase in heart rate and a decrease in peripheral skin temperature were observed when the teeth were clipped to the gum line (Fu *et al.*, 2019). In 1-day old piglets, neither clipping nor grinding the teeth affected plasma concentrations of cortisol, ACTH or lactate from 2 to 180 minutes after the procedure (Prunier *et al.*, 2005). Similarly, Marchant-Forde *et al.* (2009) saw no cortisol increase in 2-3 day old piglets at 45 minutes, 4 hours, 48 hours, 1 and 2 weeks after tooth resection with either method. The amount of tooth removed in the studies by Prunier *et al.* (2005) and Marchant-Forde *et al.* (2009) was not severe, leaving several millimetres of tooth above the gum line. Squeal rate was lower during grinding compared with sham processing, whereas tooth clipping had no effect (Marchant-Forde *et al.*, 2009; Noonan *et al.*, 1994). However, the procedures undoubtedly altered both the ability to vocalize and vocalization characteristics thereby reducing the suitability of vocalizations as a pain evaluating tool during the procedure. More escape/defence movements per second were observed in processed pigs than in sham piglets regardless of the method of tooth resection (Marchant-Forde *et al.*, 2009).

In the first minutes after treatment, piglets with clipped teeth showed more teeth champing (opening and closing of the jaws, mouth empty) than sham-processed piglets (Bataille *et al.*, 2002; Lewis *et al.*, 2005b; Noonan *et al.*, 1994; Sinclair *et al.*, 2019) but the difference was less marked (Bataille *et al.*, 2002) or not significant (Lewis *et al.*, 2005b; Sinclair *et al.*, 2019) in piglets with ground teeth. However, it should be mentioned that the length of tooth removed was not directly comparable across studies: Bataille *et al.* (2002) and Sinclair *et al.* (2019) aimed to remove half and one third of each tooth respectively regardless of treatment, whereas in Lewis *et al.* (2005b) teeth were resected to the gum line during clipping but only the tips of the teeth were removed during grinding. While isolated in a behavioural test area, piglets with clipped teeth showed less wood shaving exploration than shams, and piglets with ground teeth were intermediate (Sinclair *et al.*, 2019).

#### 4. Husbandry interventions in suckling piglets, painful consequences and mitigation

During the first 10 (Bataille *et al.*, 2002) or 30 minutes (Lewis *et al.*, 2005b) after tooth resection, the only significant difference in behaviour was that processed pigs spent less time being active on a heat pad than sham-processed pigs (Lewis *et al.*, 2005b). Bataille *et al.* (2002) prolonged their observations for 12 hours looking at suckling behaviour, teat massaging and piglet postures but found no significant difference between treatments. More detailed observations by Lewis *et al.* (2005b) at 1, 4, 8, 14 and 21 days after the intervention showed some variations in the percentage of active piglets but these were minor and fluctuated with age. More recently, Fu *et al.* (2019) showed that time spent lying alone was increased whereas time spent playing and fighting was decreased in piglets with teeth clipped to the gum line compared to sham-processed piglets, with observations spread throughout lactation.

Overall, the behavioural and physiological signs of pain after tooth resection are limited. However, this is based only on a few studies and, as already stated for surgical castration, it is difficult to demonstrate the existence of pain in young pigs.

##### 4.3.3 Long term consequences of tooth resection

Neural evidence of long-term pain due to tooth resection in pigs is lacking in the scientific literature. Yet, it is widely reported that traumatic dental injury in humans and other species (e.g. monkey, cat, dog) involving loss of pulp cavity integrity and dental pulp exposure (with or without nerve injury), activation of and infiltration by inflammatory cells, and abscess formation are associated with severe dental pain (see review by Byers and Narhi, 1999). Similar features of traumatic tooth injury were reported in piglets subjected to shortening of teeth by clipping or grinding (Hay *et al.*, 2004) (Figure 4.3). It is therefore highly likely that these procedures also cause intense pain in piglets. Recent preliminary studies by Sinclair *et al.* (2018) investigating gene expression in the dental pulp of piglets whose needle teeth were shortened by either clipping or grinding showed sustained up-regulation (still evident 6 weeks after tooth injury) of the pro-inflammatory chemokine CXCL8 in exposed dental pulp with both methods. However, there was no

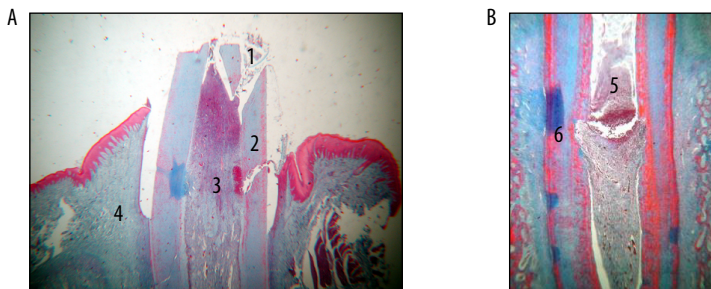


Figure 4.3. Histological axial sections of a tooth clipped at 3 days of age and collected at 7 (A left) or 28 days of age (B right). (1) Tooth pulp is opened and debris is present, (2) fracture in the dentine, (3) haemorrhage, (4) maxillary bone, (5) abscess in the tooth pulp, (6) resorption of the dentine. Staining with Masson's trichrome (magnification: 25 for A, 100 for B). Photo by G. Brunel.

difference in expression levels between the two methods. The chemokine CXCL8 is involved in a well-known pathway contributing to the development of inflammation at the site of injury (Enzerink *et al.*, 2009). Its over expression and its cognate receptor are critical in the development of neuro-inflammation and the establishment of pain (White *et al.*, 2005). Data from Sinclair *et al.* (2018) support evidence of a persistent localised inflammatory state in the tooth pulp induced by both methods of tooth resection.

The influence of tooth resection on piglet growth and mortality varies across studies with a reduction in growth (Bataille *et al.*, 2002; Weary and Fraser, 1999) and mortality (Holyoake *et al.*, 2004), no significant effect on growth and mortality (Fu *et al.*, 2019; Gallois *et al.*, 2005; Lewis *et al.*, 2005b) or an increase in growth (Holyoake *et al.*, 2004) in piglets with resected teeth.

#### **4.3.4 Possible means to avoid tooth resection**

Not performing tooth resection could lead to lesions on the sow mammary glands; however, tooth resection should not be favoured because it is associated with persistent dental pain in piglets due to damage to the dental pulp. The only clear positive effect of tooth resection on piglet welfare is a reduction in the number of skin lesions. The lesions on piglets can occur during fights between littermates or by rubbing and hitting each other when at the mammary glands trying to obtain milk. Therefore, a high litter size, especially when greater than the number of functional teats, and insufficient milk production are very important risk factors for skin lesions. Avoiding excessive litter size by cross-fostering piglets or by choosing less prolific genetic lines, as well as early detection and treatment of milk failure are good means to avoid tooth shortening.

## **4.4 Tail docking**

### **4.4.1 Why and how this practice is performed**

Even though not fully effective, tail docking of piglets reduces the risk of tail biting (D'Eath *et al.*, 2016; Lahrmann *et al.*, 2017; Thodberg *et al.*, 2018). For this reason, tail docking is commonly practiced in many farms across the world. As with tooth resection, this procedure must not be performed on a routine basis in the EU (2001/93/EC, 2001, 2008/120/EC, 2008). However, recent data indicate that pigs are routinely submitted to tail docking in most European countries (De Briyne *et al.*, 2018). Similarly, most piglets from large scale farms in China are submitted to tail docking (Yao Wen, personal communication).

Tail docking is performed with scalpels, scissors, wire cutters or by hot iron cauterization (Figure 4.4). In most cases, no anaesthetic nor analgesic treatments are performed to reduce the pain associated with this procedure. The proportion of the tail that is docked is variable: from only the tip to  $\frac{3}{4}$  of the tail, or even more. Histological observations from Simonsen *et al.* (1991) showed the existence of peripheral nerves to the tip of tails in 1-day old piglets. Furthermore, the presence of A-delta and C-fibre sensory neurons

#### 4. Husbandry interventions in suckling piglets, painful consequences and mitigation



Figure 4.4. Image of a piglet during tail docking with a hot iron apparatus. Photo Liat Romme Thomsen.

was recently demonstrated using transmission electron microscopy (TEM) in dorsal and ventral tail caudal nerves in 3-day-old piglets (Carr *et al.*, 2015), confirming that tail docking can most definitely cause pain.

##### 4.4.2 Evidence of pain during and shortly after tail docking

An electroencephalographic (EEG) approach was developed to evaluate pain during tail docking (Kells *et al.*, 2017a, 2019). Indeed, changes in the EEG spectra under light anaesthesia could reliably indicate pain during surgical castration in horses (Murrell *et al.*, 2003), sheep (Johnson *et al.*, 2005) and pigs (Haga and Ranheim, 2005). Changes in the EEG median frequency (F50) and 95% spectral edge frequency (F95), both indices of nociception, were reported in lightly anaesthetised piglets undergoing tail docking (Kells *et al.*, 2017a, 2019). When comparing pigs tail-docked at various ages and using different methods, these last authors concluded that tail docking within the first days following birth may be less painful than docking during the second or third week of postnatal life, and that tail docking using clippers may be more painful than using a cautery iron.

Pain during tail docking was also demonstrated by behavioural observations. During the procedure, more defence movements and attempts to escape were observed in docked than in sham-docked pigs (Courboulay *et al.*, 2015; Herskin *et al.*, 2016; Marchant-Forde *et al.*, 2009; Prunier *et al.*, 2001; Tallet *et al.*, 2019). However, no effects of the severity (25, 50 or 75% of the tails left) of docking on these vigorous startling movements of the body and of one or more limbs (= jerks) were found (Herskin *et al.*, 2016). During tail docking, the number and rate of high-pitched vocalizations (including screams and squeals) as well as their loudness were higher in pigs docked using cutting pliers or hot iron cautery than in sham-docked pigs (Backus and McGlone, 2018; Courboulay *et al.*, 2015; Herskin *et al.*, 2016; Marchant-Forde *et al.*, 2009; Prunier *et al.*, 2001; Tallet *et al.*, 2019). In their study, Di Giminiani *et al.* (2017b) found no difference in the call rate, the maximum, or the mean frequency of the calls but demonstrated higher mean call energy and loudness in docked than in sham-docked pigs and a lower peak to peak pressure level in docked

than in sham-docked pigs, with a stronger effect using cold than hot iron cautery. The percentage of piglets squealing during docking increased with the severity (25 to 75% of the tail removed) of docking (Herskin *et al.*, 2016). A few experiments demonstrated that some of the behaviours induced by tail docking were reduced by an analgesic treatment (see section on Mitigation of pain related to tail docking).

In the minutes after tail docking, while piglets were isolated in a cart, tails were more often immobile and ears more perpendicular to the head and moving in docked than in sham-docked pigs (Tallet *et al.*, 2019). During the same period, grunts and high-pitched vocalizations (Noonan *et al.*, 1994), rapid tail movements (= tail wagging) (Noonan *et al.*, 1994; Prunier *et al.*, 2001) and having the tail pressed against the body (Prunier *et al.*, 2001) were more frequent in docked than in sham-docked pigs. In the following minutes and hours, some behavioural differences were depicted: more tail trembling and less ample tail movements (Courboulay *et al.*, 2015), more scooting plus huddling and tail jammed between legs (Backus and McGlone, 2018), more lying (Tallet *et al.*, 2019) and more lying in the heated creep area (Herskin *et al.*, 2016) being observed in docked than in sham-docked pigs. On the day after docking (Courboulay *et al.*, 2015) and during the three (Fu *et al.*, 2019) or four following weeks (Tallet *et al.*, 2019), some differences were still depicted. There were more tail trembling and less ample tail movements (Courboulay *et al.*, 2015), a preference for lying in the heated creep area, more time lying alone and less time fighting/playing (Fu *et al.*, 2019), the tail was more often immobile and in an horizontal position (Tallet *et al.*, 2019), and piglets displayed more behavioural reaction to tail touching (e.g. escape, vocalization, aggression; Tallet *et al.*, 2019) in docked than in sham-docked pigs.

In 1-day old piglets, docking by hot iron cautery did not influence plasma concentrations of cortisol, ACTH or lactate from 2 to 180 minutes after the procedure (Prunier *et al.*, 2005). However, in a more recent experiment using a larger number of 2- or 5-day old piglets that were sampled once, 30 minutes after treatment, there was an increase in plasma cortisol in docked (hot iron) compared to sham-handled piglets (Courboulay *et al.*, 2015). When piglets were docked at 6 days of age, there was also an increase in plasma cortisol 60 minutes after docking with pliers but not with hot iron cautery (Sutherland *et al.*, 2008), suggesting again that cautery may be less painful than clipping. In piglets docked with pliers at a younger age (3 days) the duration of the increase in plasma cortisol seemed shorter since the difference with sham-docked piglets was present at 30 but not at 60 minutes after treatment (Sutherland *et al.*, 2011).

Overall, the literature provides clear indications that tail docking elicits pain in piglets. Procedural pain seems more acute with cold cutting than with hot iron cautery and may increase with the age of piglets at docking. After surgery, behavioural alterations are of low or moderate amplitude but seem to persist for several days.

#### **4.4.3 Mitigation of pain related to tail docking**

At present, neither analgesia nor anaesthesia are used routinely to alleviate the pain caused by tail docking. In addition, as reviewed by Sutherland (2015) there is limited

#### 4. Husbandry interventions in suckling piglets, painful consequences and mitigation

research regarding effective pain mitigation strategies for piglets. Treatment with a NSAID such as meloxicam, when administered alone, has been unsuccessful in reducing the procedural pain of tail docking, as shown by its lack of effect at reducing the intensity of the vocalizations (Courboulay *et al.*, 2015) or the presence of sudden jerks (Herskin *et al.*, 2016). Injecting a local anaesthetic at the base of the tail before surgery should be more efficient. Indeed, subcutaneous injection of lidocaine 15 minutes before tail docking reduced the behavioural responses during the procedure, hence decreasing the percentage of piglets squealing or showing jerking movements (Herskin *et al.*, 2016).

Neither meloxicam nor local anaesthesia were efficient in mitigating post-procedural pain as shown by a lack of effect on the post-procedural behaviour (Courboulay *et al.*, 2015; Herskin *et al.*, 2016). Performing a subcutaneous injection of lidocaine at the base of the tail immediately before docking or applying lidocaine topically on the tail-docked wound were both ineffective in alleviating the post-procedural pain (Sutherland *et al.*, 2011). More recently, Viscardi and Turner (2019) showed that an intramuscular injection, 20 minutes before surgery, of the opioid buprenorphine alone or in combination with meloxicam led to a lower occurrence of specific behaviours typically seen after tail docking, and to a lower grimace score after docking. Even though not fully efficient, solutions exist to alleviate the acute pain due to tail docking in piglets. However, these solutions are not simple and are probably not feasible in commercial farms (e.g. lidocaine at the base of the tail) or would likely not be allowed for use in animals raised for human consumption (e.g. buprenorphine).

##### 4.4.4 Long term consequences of tail docking

As for castration, tail docking may induce long-term neuropathic pain because it involves complete transection of nerves. Even though limited, some data on the subject are available in pigs. First, the existence of traumatic neuroma (random proliferation of regenerating axons and glial support cells, Figure 4.5) development was demonstrated in pigs slaughtered one to several months after neonatal tail amputation (Done *et al.*, 2003; Kells *et al.*, 2017b; Sandercock *et al.*, 2016; Simonsen *et al.*, 1991). The method of docking, e.g. clipping vs cautery, does not seem to affect the neuroma formation (Kells *et al.*, 2017b). Such neuromas are known to be sources of pain due to spontaneous discharges of nociceptive neurones or to hypersensitivity to normal light tactile stimuli (Foltan *et al.*, 2008). The existence of tail hypersensitivity after docking has been questioned in pigs (Di Giminiani *et al.*, 2017a,b). In a pioneer study, Sandercock *et al.* (2011) explored tail nociceptive sensitivity of pigs submitted to docking with surgical cutters during the first week after birth by measuring the behavioural response to mechanical and/or cold stimulation. They compared docked and sham-docked pigs 7 weeks after the treatment and did not detect any significant differences between the two groups. Similar results were obtained with pigs docked (one or two thirds of the tail removed) during the first postnatal week by hot iron cautery and stimulated at the tip of the remaining part of the tail at approximately 17 weeks of age (Di Giminiani *et al.*, 2017b). In an experimental model of tail biting, amputation of the tail (one or two thirds of the tail removed) was performed at 9 or 17 weeks of age and docked animals exhibited signs of mechanical hypersensitivity at the tail tip at 1, 8 and 16 weeks after surgery, regardless of the severity



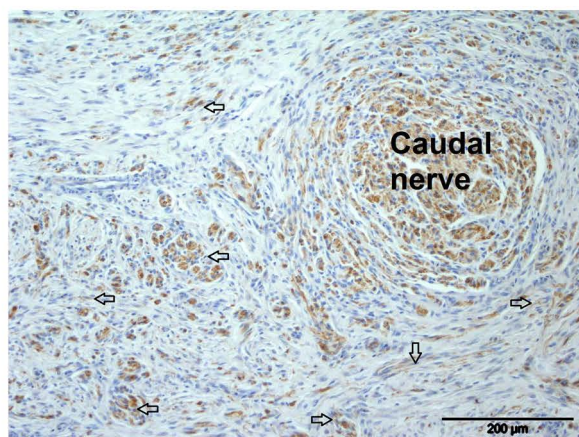


Figure 4.5. Immunohistological image of a caudal nerve traumatic neuroma in the proximal stump of an 8 week-old pig tail docked at 3 days of age. Image shows transverse section of caudal nerve traumatic neuroma characterized by widespread axonal proliferation and dispersion (indicated by arrow heads) in the deep dermis (S100 neural marker immuno-staining;  $\times 10$ ). Photo by Dale Sandercock.

of docking (Di Giminiani *et al.*, 2017a). Therefore, it would appear that older pigs may be more prone to develop hypersensitivity when the tail is amputated. However, the existence of hypersensitivity cannot be fully excluded in pigs docked at an earlier age because the lack of a detected difference is not proof of the lack of an existing effect given the methodological difficulties.

Using a molecular approach, Sandercock *et al.* (2019) revealed significant and sustained changes 4 months after tail amputation in 185 inflammatory and neuropathic pain-associated genes. Tail amputation was performed at 3 (similar to usual tail docking) or 63 (a surgical model of tail biting in growing pigs) days of age. Gene ontology (GO) enrichment of gene expression clusters led to the identification of gene family members of ion channels (e.g. voltage-gated potassium channels) and receptors (e.g. GABA receptors) that were significantly down-regulated in both tail amputation groups. From these results, it was proposed that the broader functional consequences of the down-regulation of these key pain neuromediators serve to increase and maintain peripheral neuronal excitability after tail amputation injury (Sandercock *et al.*, 2019). This proposal is supported by histological evidence of traumatic neuroma after tail docking (Done *et al.*, 2003; Herskin *et al.*, 2015; Sandercock *et al.*, 2016; Simonsen *et al.*, 1991) and by the presence of long-term mechanical sensitization in tail stumps from tail-amputated pigs (Di Giminiani *et al.*, 2017a).

Similarly to castration, tail docking leads to procedural pain and stress. Therefore, it could have negative consequences on the pig-human relationship. Indeed, two weeks after birth, it takes more time for docked piglets to interact with an unfamiliar human in an individual test than for undocked piglets (Tallet *et al.*, 2019). This is a sign of increased fearfulness of humans. Preliminary results suggest that the differences disappear after weaning (Tallet and Prunier, unpublished data).

##### 4.4.5 Possible means to avoid tail docking

As previously stated, the reason for tail docking is to reduce the risk of tail biting, which may occur during the post-weaning or fattening periods and which has strong detrimental consequences for the welfare and performance of pigs. Therefore, tail docking could be avoided only if the risk of tail biting is so low that episodes of tail biting are scarce and, when occurring, can be rapidly overcome by the farmers. This is possible even in modern pig housing, as shown by examples in Finland, Norway, Sweden and Switzerland, where the percentage of tail-docked pigs is extremely low (<3%, De Briyne *et al.*, 2018). Favourable conditions to avoid tail docking have been reviewed in several papers (e.g. D'Eath *et al.*, 2016; Schroöder-Petersen and Simonsen, 2001; Valros and Heinonen, 2015). Among key points are proper enrichment material, appropriate space allowance, early detection and mitigation of biting episodes and good health of the herd. Even though the environment in which pigs are performing tail biting is of major importance, the pre-weaning conditions should also be optimized to limit undernutrition, social stress due to competition and cross-fostering (Prunier *et al.*, 2019).

#### 4.5 Other painful husbandry practices

Beyond castration, tooth resection and tail docking, piglets are often submitted to several practices within routine management that are potentially painful and that can have detrimental consequences for their welfare. Some procedures, such as umbilical cord care or splay-legged piglet management, imply restraint in movement but are not invasive and thus do not represent a challenge in terms of pain. However, any handling can be stressful to piglets and can impact future human-animal relationship (Chapter 11, Marchant-Forde *et al.*, 2020). Beyond handling, identification methods are practices that involve invasive actions on the piglets. Different types of identification methods can be used, such as ear tattooing, ear tagging, ear notching or microchips implant injection. Another common type of invasive practice is injection via various routes (intramuscular, intraperitoneal, subcutaneous) and for different purposes, such as iron supplementation, vaccination, antibiotic treatment or any other medical treatment. Finally, euthanasia can also be considered as a potentially painful procedure if the technique used does not lead to immediate death or loss of consciousness. However, due to space limitations, euthanasia will not be discussed here.

##### 4.5.1 Evidence of pain during and shortly after the procedures

Identification methods are widely used and sometimes requested for biosecurity or traceability reasons. The most common methods of identification are ear notching, tagging or tattooing which involve the injury of innervated tissue and, hence, are potentially painful. In Australia, a survey in commercial farms showed that ear notching was the most used technique for identification of weaner pigs (Hernandez-Jover *et al.*, 2008).

Ear notching requires removal of several small parts of the auricle and is undoubtedly painful, as shown by the piglets' reaction during the procedure when compared to sham-

processed piglets. Indeed, the number and intensity of vocalisations (Leslie *et al.* 2010; Marchant-Forde *et al.* 2009, 2014), the number of escape attempts (Marchant-Forde *et al.*, 2009) or the frequency of piglets demonstrating head withdrawal (Lomax *et al.*, 2018) were higher in notched piglets. After the procedure, ear-notched piglets also perform more grunts, head shaking and ear scratching, and spend less time standing and more time awake but inactive for up to 3 hours when compared to controls, thereby suggesting the presence of pain (Leslie *et al.*, 2010; Marchant-Forde *et al.*, 2009; 2014; Noonan *et al.*, 1994). Ear tagging is less damaging than ear notching because it involves a single puncture of the auricle; therefore, it should be less painful. Indeed, ear tagging triggers behavioural responses, vocalizations and defence movements, but the response is less marked than during ear notching (Leslie *et al.*, 2010; Marchant-Forde *et al.*, 2009). This lower response of ear tagging may also be related to a shorter procedure duration. Plasma cortisol concentrations 4 hours after notching or ear tagging did not differ when compared to sham-processed piglets (Marchant-Forde *et al.*, 2009), but it was probably too late to measure the cortisol response to pain. Indeed, an increase in plasma cortisol was seen 30 and 60 minutes after performing ear notching (Numberger *et al.*, 2016). Yet, no comparison was done at this time between the two techniques. When observed over 3 hours after the procedure, head shaking and ear scratching were expressed more often after ear tagging than after ear notching (Leslie *et al.*, 2010), which could be explained by the presence of a foreign body in the ear instead of by a more intense pain. During the same 3-hour period, ear-tagged piglets stood less and spent more time awake but inactive and in isolation than sham-processed piglets (Leslie *et al.*, 2010). No differences between ear-tagged and ear-notched piglets were depicted for these behaviours (Leslie *et al.*, 2010). The healing process evaluated until 14 days after the procedure was better following ear tagging than ear notching (Marchant-Forde *et al.*, 2009). Tattooing is less used than ear notching or tagging and studies on its welfare consequences are scarce. One very important flaw of tattooing is its low readability after a few months (Barbieri *et al.*, 2012; Gosalvez *et al.*, 2007). Only one study reported on the behaviour of piglets within 5 minutes of the procedure in comparison to other identification methods (Barbieri *et al.*, 2012). Tattooed pigs displayed similarly low frequencies of head shaking or ear scratching than pigs receiving an intraperitoneal implant, being much lower than in pigs receiving an electronic ear tag (Barbieri *et al.*, 2012).

New identification techniques using microchip implants of various size (from 1.4 × 8 mm to 4 × 32 mm) allowing wireless RFID identification have been tested (Barbieri *et al.*, 2012; Bergqvist *et al.*, 2015; Leslie *et al.*, 2010). These implants can be injected subcutaneously at the auricle base or intraperitoneally. During the 5 minutes after injecting an electronic ear implant, piglets did not show increased frequencies of head shaking or ear scratching when compared to piglets receiving an electronic ear tag (Barbieri *et al.*, 2012). Auricle based implants also lead to less ear lesions than ear tags (Bergqvist *et al.*, 2015). Piglets injected intraperitoneally with an electronic implant spent less time standing and more time isolated and awake but inactive during the 3 hours following the procedure compared with sham-treated piglets, hence suggesting the presence of post-procedural pain (Leslie *et al.*, 2010). Piglets are often submitted to subcutaneous or intramuscular injections for health care as preventive measures (e.g. iron treatment or vaccinations) or to treat a disease. More rarely, injections can be performed for pain mitigation (see previous

#### 4. Husbandry interventions in suckling piglets, painful consequences and mitigation

section on castration). In either case, the level of tissue damage is low so that the expected pain is mild. There are few studies examining pain responses of piglets to injections. Beyond the studies on microchip implants previously discussed, Marchant-Forde *et al.* (2009, 2014) compared intramuscular injection of iron to oral administration and sham-processing of piglets and no differences were observed in behavioural responses that are indicative of pain during the procedure.

In a few studies, authors tried to compare the response to ear notching or ear tagging with that to tail docking. When correcting for the duration of the procedure, tail-docked piglets exhibited more vocalizations during the procedure than ear-notched piglets (Noonan *et al.*, 1994). Such a difference was also observed in the minute following return of the piglets to the home pen. The increase in cortisol concentrations 30 and 60 minutes after the procedure was similar for pigs submitted to tail docking and to ear tagging (Numberger *et al.*, 2016). Interestingly, ear notching, tail docking and tooth resection have also been studied in combination (Marchant-Forde *et al.*, 2014; Noonan *et al.*, 1994; Torrey *et al.*, 2009; Van Beirendonck *et al.*, 2011a) because they are often carried out at the same age and time in commercial piggeries. From these studies, it is clear that piglets submitted to combined procedures exhibit similar behavioural responses as reported for each site of intervention separately (ear, teeth and tail) but it is unclear if the intensity of their pain response is higher or lower than when procedures are conducted separately.

It is evident that identification methods can induce acute pain due to the focal injury of innervated tissue and, in addition, discomfort when an external foreign body is attached (e.g. ear tag). The intensity and duration of the induced pain is difficult to evaluate and, even more so, to compare between identification methods due to an insufficient number of studies, especially in the hours and first day after identification procedures are applied, and also due to a lack of common protocols to evaluate pain. However, from the existing literature, it seems that ear tagging is preferable to ear notching and that, from a welfare perspective, a subcutaneous implant would be even better.

##### 4.5.2 Mitigation of pain related to the procedures

Several methods can be used to alleviate pain during and after these procedures are performed using general or local anaesthesia, or analgesia (Dzikamunhenga *et al.*, 2014). In the case of routine injections (e.g. vaccination), the level of pain is suspected to be low so that pain alleviation is not required. In the case of identification methods where the level of pain is probably moderate, pain alleviation would be useful but general anaesthesia is probably excessive except if other painful interventions are performed simultaneously. One study looked at the use of 100% CO<sub>2</sub> anaesthesia during combined procedures including tail docking, tooth resection, ear tagging and iron injection in 7-day old piglets and concluded that pain sensation is only delayed until after the procedure (Van Beirendonck *et al.*, 2011b). For identification at the ear level, several ways to mitigate pain were tested, such as local anaesthesia (Lomax *et al.*, 2018), injection of a NSAID (Numberger *et al.*, 2016; Übel *et al.*, 2015) or administration of sucrose (Rand *et al.*, 2002). During the procedure, local anaesthesia using either a topical vapocoolant spray which reduces ear temperature to below 10 °C, or an anaesthetic such as lidocaine infiltrated

in the edge of the ear, were effective in reducing the response of piglets to ear notching (Lomax *et al.*, 2018). The use of a vapocoolant spray was also efficient in reducing pain from ear tagging and ear notching in calves (Lomax *et al.*, 2017). The vapocoolant spray has the further advantage of being non-invasive. Unfortunately, longer-term pain was not assessed in these studies. Eutectic mixture of local anaesthetics (EMLA) cream was proven efficient for local non-invasive anaesthesia in rabbits undergoing ear tattooing (Keating *et al.*, 2012), but this method has not been reported in piglets yet. Intramuscular injection of meloxicam 30 minutes before ear tagging was effective in reducing the blood cortisol increase after ear tagging of 3-day old piglets (Numberger *et al.*, 2016). However, this method requires manipulating piglets twice and performing an injection that may cause further stress. Finally, behaviour of piglets receiving an oral administration of a 12% sucrose solution just before the procedure was similar to that of piglets receiving a placebo (Rand *et al.*, 2002).

To conclude, some non-invasive and effective options are available to reduce the pain caused by tissue-damaging identification procedures. The vapocoolant spray has the advantage of a 2 second application time and instantaneous effect while EMLA has to be applied 20 minutes before the procedure, hence requiring a second manipulation of the piglets. For post-procedural pain, intramuscular NSAID administration seems to be effective but involves additional handling.

#### **4.5.3 Long term consequences of the procedures**

Most of the studies previously cited have focussed on the short-term consequences of identification methods, and long-term consequences are generally not considered. Only one study looked at the presence of lesions on ears with tags at slaughter and reported an incidence of 23.4% visible wounds at the ear tag site (Bergqvist *et al.*, 2015). Several studies have looked at the impact of handling and human attitudes towards piglets on later human-animal relationships. For example, Sommavilla *et al.* (2011) showed that an aversive attitude of the caregiver during lactation significantly increases the reactivity of piglets towards humans at weaning and adversely affects their behaviour with penmates for the first two or three days after weaning, with more escape attempts, more fighting and less resting. Indeed, piglets are able to remember aversive or gentle handling for several weeks (Brajon *et al.*, 2015b) or even months (Hemsworth and Barnett 1992) and can discriminate between handlers depending on their previous experience with them (Brajon *et al.*, 2015a).

#### **4.5.4 Possible means to avoid the procedures**

Since injections are often related to health care and medical treatment of piglets, the cost of not applying sanitary prevention procedures or treating sick piglets may largely offset their negative impact in terms of pain. Furthermore, even with a potentially painful injection such as anaesthetic injection into the testis, the benefits of anaesthesia during castration would definitely outweigh the costs of the pain related to the injection when compared to subjecting piglets to castration without anaesthesia (Haga and Ranheim, 2005). Considering identification methods, regulations vary between countries and

regions (Madec *et al.*, 2001; Schembri *et al.*, 2007). If identifications are an obligation for traceability purposes, piglets in commercial settings may not be identified at a young age, and slap tattooing would occur just before departure to the slaughter plant. However, individual identification on farm still remains a good practice for health and breeding management. Considering the pain incurred by ear-tagging or ear-notching, microchip injection would represent a good alternative.

## 4.6 Conclusions

The present chapter clearly shows that husbandry practices are sources of pain for piglets. The sensory component of pain was demonstrated by EEG changes at the brain level, spontaneous behaviours to avoid tissue damage (avoidance and defensive reactions) when the procedure is being applied, the induction of pain mediators in neural pathways of pain, and the existence of hyperalgesia in nociceptive tests later on. The emotional component is less documented; however, vocalizations during the procedure, some general behavioural changes after the procedure (e.g. isolation or being awake but inactive), and the later deterioration of the animal's confidence in humans can be considered as evidence of a negative affective state. To the best of our knowledge, no studies have used motivational or cognitive bias tests in pigs that have undergone husbandry practices. Therefore, such methods of assessing the emotional component of pain in response to painful management procedures need to be developed in pigs.

Possibilities to reduce the welfare consequences of painful husbandry practices exist for most of them either by choosing the less painful option or by treating animals with analgesics or anaesthetics. In most cases, adequate pain mitigation requires a multimodal approach involving the provision of anaesthesia (local or general) for procedural pain, and analgesics (e.g. NSAIDs) for post-procedural pain. Stopping most of these practices is also possible but at the cost of modifying rearing conditions (e.g. housing for tail docking), choosing different genetic lines or changing the selection goals (e.g. less prolific lines for tooth resection) and even adapting the whole production chain (e.g. testing boar taint in slaughterhouses). Nevertheless, in order to choose with certainty the least harmful practice or the best protocol for pain mitigation that comply with the legislation on animal production for human consumption, we must develop practical, reliable and validated methods of pain assessment that take into account the sensory and emotional facets.

## References

- Adcock, S.J.J. and Tucker, C.B., 2020. Conditioned place preference reveals ongoing pain in calves 3 weeks after disbudding. *Scientific Reports* 10: 3849. <https://doi.org/10.1038/s41598-020-60260-7>

- Allison, J., Pearce, M., Brock, F. and Crane, J., 2010. A comparison of mortality (animal withdrawal) rates in male fattening pigs reared using either physical castration or vaccination with Improvac® as the method to reduce boar taint. In: D'Allaire, S. and Friendship, R. (eds.) 21<sup>st</sup> IPVS Congress, Vancouver, Canada. IPVS, pp. 1139.
- Aluwe, M., Degezelle, I., Depuydt, L., Fremaut, D., Van den Broeke, A. and Millet, S., 2016. Immunocastrated male pigs: effect of 4 v. 6 weeks time post second injection on performance, carcass quality and meat quality. *Animal* 10: 1466-1473. <https://doi.org/10.1017/s1751731116000434>
- Backus, B.L. and McGlone, J.J., 2018. Evaluating environmental enrichment as a method to alleviate pain after castration and tail docking in pigs. *Applied Animal Behaviour Science* 204: 37-42. <https://doi.org/10.1016/j.applanim.2018.04.009>
- Barbieri, S., Minero, M., Barattiero, D., Cantafora, A.F.A. and Crimella, C., 2012. Recognised-by-law versus other identification systems in pigs: piglets discomfort evaluation and performance testing. *Italian Journal of Animal Science* 11: 190-195. <https://doi.org/10.4081/ijas.2012.e35>
- Bataille, G., Rugraff, Y., Meunier-Salaün, M.C., Bregeon, A. and Prunier, A., 2002. Conséquences comportementales, zootechniques et physiologiques de l'épointage des dents chez le porcelet. (Influence of tooth resection on behaviour, performance and physiology of piglets). *Journées de la Recherche Porcine* 34: 203-209. <http://www.journees-recherche-porcine.com/texte/2002/02txtBienetre/BE0201.pdf>.
- Bengtsdotter, E.A., Ekman, S. and Andersen, P.H., 2019. Neuromas at the castration site in geldings. *Acta Veterinaria Scandinavica* 61: 43. <https://doi.org/10.1186/s13028-019-0479-8>
- Bergqvist, A.-S., Forsberg, F., Eliasson, C. and Wallenbeck, A., 2015. Individual identification of pigs during rearing and at slaughter using microchips. *Livestock Science* 180: 233-236. <https://doi.org/10.1016/j.livsci.2015.06.025>
- Bonastre, C., Mitjana, O., Tejedor, M.T., Calavia, M., Yuste, A.G., Ubeda, J.L. and Falceto, M.V., 2016. Acute physiological responses to castration-related pain in piglets: the effect of two local anesthetics with or without meloxicam. *Animal* 10: 1474-1481. <https://doi.org/10.1017/s1751731116000586>
- Bonneau, M. and Weiler, U., 2019. Pros and cons of alternatives to piglet castration: welfare, boar taint, and other meat quality traits. *Animals* 9: 884. <https://doi.org/10.3390/ani9110884>
- Brajon, S., Laforest, J.P., Bergeron, R., Tallet, C. and Devillers, N., 2015a. The perception of humans by piglets: recognition of familiar handlers and generalisation to unfamiliar humans. *Animal Cognition* 18: 1299-1316. <https://doi.org/10.1007/s10071-015-0900-2>
- Brajon, S., Laforest, J.P., Bergeron, R., Tallet, C., Hotzel, M.J. and Devillers, N., 2015b. Persistency of the piglet's reactivity to the handler following a previous positive or negative experience. *Applied Animal Behaviour Science* 162: 9-19. <https://doi.org/10.1016/j.applanim.2014.11.009>
- Byers, M.R. and Narhi, M.V.O., 1999. Dental injury models: experimental tools for understanding neuroinflammatory interactions and polymodal nociceptor functions. *Critical Reviews in Oral Biology and Medicine* 10: 4-39. <https://doi.org/10.1177/10454411990100010101>
- Carr, R.W., Coe, J.E., Forsch, E., Schmelz, M. and Sandercock, D.A., 2015. Structural and functional characterisation of peripheral axons in the caudal nerves of neonatal pigs: preliminary data. In: 9<sup>th</sup> Congress of the European Pain Federation (EFIC), 2-5 September 2015, Vienna, Austria.
- Carroll, J.A., Berg, E.L., Strauch, T.A., Roberts, M.P. and Kattesh, H.G., 2006. Hormonal profiles, behavioral responses, and short-term growth performance after castration of pigs at three, six, nine, or twelve days of age. *Journal of Animal Science* 84: 1271-1278. <https://doi.org/10.2527/2006.8451271x>

#### 4. Husbandry interventions in suckling piglets, painful consequences and mitigation

- Castel, D., Willentz, E., Doron, O., Brenner, O. and Meilin, S., 2014. Characterization of a porcine model of post-operative pain. *European Journal of Pain* 18: 496-505. <https://doi.org/10.1002/j.1532-2149.2013.00399.x>
- Castrum consortium, 2016. Pig castration: methods of anaesthesia and analgesia for all pigs and other alternatives for pigs used in traditional products, Luxembourg. <https://doi.org/10.2875/057159>
- Courboulay, V., Gillardeau, M., Meunier-Salaün, M.C. and Prunier, A., 2015. La prise en charge de la douleur lors de la caudectomie et de la castration des porcelets. (Pain relief at piglet tail docking and castration.) *Journées Recherche Porcine* 47: 235-240.
- Courboulay, V., Hémonic, A. and Prunier, A., 2018. Evaluation des différentes méthodes de prise en charge de la douleur lors de la castration. (Assessing the different methods of pain management during castration.) *Journées Recherche Porcine* 50: 305-310. <http://www.journees-recherche-porcine.com/texte/2018/bienetre/b05.pdf>.
- Courboulay, V., Hémonic, A., Gadonna, M. and Prunier, A., 2010. Castration avec anesthésie locale ou traitement anti-inflammatoire: quel impact sur la douleur des porcelets et quelles conséquences sur le travail en élevage? (Effect of local anaesthesia or anti-inflammatory treatment on pain associated with piglet castration and on labour demand.) *Journées de la Recherche Porcine en France* 42: 27-33. <http://www.journees-recherche-porcine.com/texte/2010/conduite/C5.pdf>.
- De Briyne, N., Berg, C., Blaha, T. and Temple, D., 2016. Pig castration: will the EU manage to ban pig castration by 2018? *Porcine Health Management* 2: 29. <https://doi.org/10.1186/s40813-016-0046-x>
- De Briyne, N., Berg, C., Blaha, T., Palzer, A. and Temple, D., 2018. Phasing out pig tail docking in the EU – present state, challenges and possibilities. *Porcine Health Management* 4: 27. <https://doi.org/10.1186/s40813-018-0103-8>
- D'Eath, R.B., Niemi, J.K., Ahmadi, B.V., Rutherford, K.M.D., Ison, S.H., Turner, S.P., Anker, H.T., Jensen, T., Busch, M.E., Jensen, K.K., Lawrence, A.B. and Sandoe, P., 2016. Why are most EU pigs tail docked? Economic and ethical analysis of four pig housing and management scenarios in the light of EU legislation and animal welfare outcomes. *Animal* 10: 687-699. <https://doi.org/10.1017/s1751731115002098>
- Di Giminiani, P., Edwards, S.A., Malcolm, E.M., Leach, M.C., Herskin, M.S. and Sandercock, D.A., 2017a. Characterization of short- and long-term mechanical sensitisation following surgical tail amputation in pigs. *Scientific Reports* 7: 4827. <https://doi.org/10.1038/s41598-017-05404-y>
- Di Giminiani, P., Nasirahmadi, A., Malcolm, E.M., Leach, M.C. and Edwards, S.A., 2017b. Docking piglet tails: how much does it hurt and for how long? *Physiology and Behavior* 182: 69-76. <https://doi.org/10.1016/j.physbeh.2017.09.028>
- Done, S.H., Guise, J. and Chennells, D., 2003. Tail biting and tail docking in pigs. In: *Proceedings of the Pig Veterinary Society Meeting, Burleigh Court, Loughborough, UK, 14-15 November 2002.*, pp. 136-154.
- Dzikamunhenga, R.S., Anthony, R., Coetzee, J., Gould, S., Johnson, A., Karriker, L., McKean, J., Millman, S.T., Niekamp, S.R. and O'Connor, A.M., 2014. Pain management in the neonatal piglet during routine management procedures. Part 1: a systematic review of randomized and non-randomized intervention studies. *Animal Health Research Reviews* 15: 14-38. <https://doi.org/10.1017/s1466252314000061>



- EFSA, 2004. Scientific Report of the Scientific Panel for Animal Health and Welfare on a request from the Commission related to welfare aspects of the castration of Piglets. EFSA Journal 91: 1-18. Available at: <https://tinyurl.com/y824syms>.
- EFSA, 2017. Animal welfare aspects in respect of the slaughter or killing of pregnant livestock animals (cattle, pigs, sheep, goats, horses). EFSA Journal 15: e04782. 10.2903/j.efsa.2017.4782. <https://doi.org/10.2903/j.efsa.2017.4782>
- Enz, A., Schüpbach-Regula, G., Bettschart, R., Fuschini, E., Bürgi, E. and Sidler, X., 2013a. Erfahrungen zur Schmerzausschaltung bei der Ferkelkastration in der Schweiz Teil 2: Injektionsanästhesie. (Experiences with piglet castration using injectable anesthetic drugs in Switzerland.) Schweizer Archiv Fur Tierheilkunde 12: 661-668. <https://doi.org/10.1024/0036-7281/a000531>
- Enz, A., Schüpbach-Regula, G., Bettschart, R., Fuschini, E., Bürgi, E. and Sidler, X., 2013b. Erfahrungen zur Schmerzausschaltung bei der Ferkelkastration in der Schweiz. Teil 1: Inhalationsanästhesie. (Experiences with piglet castration underinhalational anaesthesia in Switzerland.) Schweizer Archiv Fur Tierheilkunde 12: 651-660. <https://doi.org/10.1024/0036-7281/a000530>
- Enzerink, A., Salmenpera, P., Kankuri, E. and Vaheri, A., 2009. Clustering of fibroblasts induces proinflammatory chemokine secretion promoting leukocyte migration. Molecular Immunology 46: 1787-1795. <https://doi.org/10.1016/j.molimm.2009.01.018>
- European Commission, 2001. Commission Directive 2001/93/EC of 9 November 2001 amending Directive 91/630/EEC laying down minimum standards for the protection of pigs. Official Journal of the European Communities L 316: 36-38. Available at: <https://tinyurl.com/r2ep2cc>.
- European Commission, 2008. Council Directive 2008/120/EC of 18 December 2008 laying down minimum standards for the protection of pigs. Official Journal of the European Communities L 47: 5-13. Available at: <https://tinyurl.com/y4kns95x>.
- Foltan, R., Klima, K., Spackova, J. and Sedy, J., 2008. Mechanism of traumatic neuroma development. Medical Hypotheses 71: 572-576. <https://doi.org/10.1016/j.mehy.2008.05.010>
- Fredriksen, B., Font i Furnols, M., Lundström, K., Migdal, W., Prunier, A., Tuytens, F.A.M. and Bonneau, M., 2009. Practice on castration of piglets in Europe. Animal 3: 1480-1487. <https://doi.org/10.1017/S1751731109004674>
- Fu, L.L., Zhou, B., Li, H.Z., Liang, T.T., Chu, Q.P., Schinckel, A.P., Li, Y. and Xu, F.L., 2019. Effects of tail docking and/or teeth clipping on behavior, lesions, and physiological indicators of sows and their piglets. Animal Science Journal 90: 1320-1332. <https://doi.org/10.1111/asj.13275>
- Gallois, M., Cozler, Y.L. and Prunier, A., 2005. Influence of tooth resection in piglets on welfare and performance. Preventive Veterinary Medicine 69: 13-23. <https://doi.org/10.1016/j.prevetmed.2004.12.008>
- Gerritzen, M.A., Kluivers-Poodt, M., Reimert, H.G.M., Hindle, V. and Lambooj, E., 2008. Castration of piglets under CO<sub>2</sub>-gas anaesthesia. Animal 2: 1666-1673. <https://doi.org/10.1017/s1751731108002887>
- Gosalvez, L.F., Santamarina, C., Averos, X., Hernandez-Jover, M., Caja, G. and Babot, D., 2007. Traceability of extensively produced Iberian pigs using visual and electronic identification devices from farm to slaughter. Journal of Animal Science 85: 2746-2752. <https://doi.org/10.2527/jas.2007-0173>

#### 4. Husbandry interventions in suckling piglets, painful consequences and mitigation

- Guatteo, R., Levionnois, O., Fournier, D., Guémené, D., Latouche, K., Leterrier, C., Mormède, P., Prunier, A., Servière, J., Terlouw, C. and Le Neindre, P., 2012. Minimising pain in farm animals: the 3S approach – ‘suppress, substitute, soothe’. *Animal* 6: 1261-1274. <https://doi.org/10.1017/S1751731112000262>
- Haga, H.A. and Ranheim, B., 2005. Castration of piglets: the analgesic effects of intratesticular and intrafunicular lidocaine injection. *Veterinary Anaesthesia and Analgesia* 32: 1-9. <https://doi.org/10.1111/j.1467-2995.2004.00225.x>
- Hansson, M., Lundeheim, N., Nyman, G. and Johansson, G., 2011. Effect of local anaesthesia and/or analgesia on pain responses induced by piglet castration. *Acta Veterinaria Scandinavica* 53: 34. <https://doi.org/10.1186/1751-0147-53-34>
- Hawkins, P.G. and Strobel, M., 2012. Barrier wound spray with pain relief for the health and welfare of baby pigs. 43<sup>rd</sup> AASV Annual Meeting, Denver, CO, USA. IPVS, pp. 1139.
- Hay, M., Rue, J., Sansac, C., Brunel, G. and Prunier, A., 2004. Long-term detrimental effects of tooth clipping or grinding in piglets: a histological approach. *Animal Welfare* 13: 23-32.
- Hay, M., Vulin, A., Génin, S., Sales, P. and Prunier, A., 2003. Assessment of pain induced by castration in piglets: behavioral and physiological responses over the subsequent 5 days. *Applied Animal Behaviour Science* 82: 201-218. [https://doi.org/10.1016/S0168-1591\(03\)00059-5](https://doi.org/10.1016/S0168-1591(03)00059-5)
- Hemsworth, P.H. and Barnett, J.L., 1992. The effects of early contact with humans on the subsequent level of fear of humans in pigs. *Applied Animal Behaviour Science* 35: 83-90. [http://dx.doi.org/10.1016/0168-1591\(92\)90018-7](http://dx.doi.org/10.1016/0168-1591(92)90018-7)
- Hernandez-Jover, M., Schembri, N., Toribio, J.A.L.M.L. and Holyoake, P.K., 2008. Biosecurity risks associated with current identification practices of producers trading live pigs at livestock sales. *Animal* 2: 1692-1699. <https://doi.org/10.1017/s1751731108003066>
- Herskin, M.S., Di Giminiani, P. and Thodberg, K., 2016. Effects of administration of a local anaesthetic and/or an NSAID and of docking length on the behaviour of piglets during 5 h after tail docking. *Research in Veterinary Science* 108: 60-67. <https://doi.org/10.1016/j.rvsc.2016.08.001>
- Herskin, M.S., Thodberg, K. and Jensen, H.E., 2015. Effects of tail docking and docking length on neuroanatomical changes in healed tail tips of pigs. *Animal* 9: 677-681. <https://doi.org/10.1017/S1751731114002857>
- Hofmann, K., Rauh, A., Harlizius, J., Weiss, C., Scholz, T., Schulze-Horsel, T., Escribano, D., Ritzmann, M. and Zols, S., 2019. Pain and distress responses of suckling piglets to injection and castration under local anaesthesia with procaine and lidocaine Part 1: cortisol, chromogranin A, wound healing, weights, losses. *Tieraerztliche Praxis Ausgabe Grosstiere Nutztiere* 47: 87-96. <https://doi.org/10.1055/a-0861-9640>
- Holyoake, P.K., Broek, D.J. and Callinan, A.P.L., 2004. The effects of reducing the length of canine teeth in sucking pigs by clipping or grinding. *Australian Veterinary Journal* 82: 574-576. <https://doi.org/10.1111/j.1751-0813.2004.tb11207.x>
- Hug, P.J., Cap, V.H., Honegger, J., Schupbach-Regula, G., Schwarz, A. and Bettschart-Wolfensberger, R., 2018. Optimization of analgesia for piglet castration under isoflurane anaesthesia with parenteral butorphanol, meloxicam or intratesticular lidocaine. *Schweizer Archiv Fur Tierheilkunde* 160: 461-467. <https://doi.org/10.17236/sat00169>
- Hutter, S., Heinritzi, K., Reich, E. and Ehret, W., 1994. Efficacité de différentes méthodes de résection des dents chez le porcelet non sevré. (The effect of different methods of tooth resection in piglets.) *Revue de Médecine Vétérinaire* 145: 205-213.

- IASP, 2019. International Association for the Study of Pain. IASP Terminology. Available at: <https://tinyurl.com/w4e6qcw>.
- Ison, S.H., Clutton, R.E., Di Giminiani, P. and Rutherford, K.M.D., 2016. A review of pain assessment in pigs. *Frontiers in Veterinary Science* 3: 108. <https://doi.org/10.3389/fvets.2016.00108>
- Johnson, C.B., Stafford, K.J., Sylvester, S.P., Ward, R.N., Mitchinson, S. and Mellor, D.J., 2005. Effects of age on the electroencephalographic response to castration in lambs anaesthetised using halothane in oxygen. *New Zealand Veterinary Journal* 53: 433-437. <https://doi.org/10.1080/00480169.2005.36589>
- Keating, S.C.J., Thomas, A.A., Flecknell, P.A. and Leach, M.C., 2012. Evaluation of EMLA cream for preventing pain during tattooing of rabbits: changes in physiological, behavioural and facial expression responses. *PLoS ONE* 7: 44437. <https://doi.org/10.1371/journal.pone.0044437>
- Keita, A., Pagot, E., Prunier, A. and Guidarini, C., 2010. Pre-emptive meloxicam for postoperative analgesia in piglets undergoing surgical castration. *Veterinary Anaesthesia and Analgesia* 37: 367-374. <https://doi.org/10.1111/j.1467-2995.2010.00546.x>
- Kells, N.J., Beausoleil, N.J., Chambers, J.P., Sutherland, M.A., Morrison, R.S. and Johnson, C.B., 2017a. Electroencephalographic responses of anaesthetized pigs (*Sus scrofa*) to tail docking using clippers or cautery iron performed at 2 or 20 days of age. *Veterinary Anaesthesia and Analgesia* 44: 1156-1165. <https://doi.org/10.1016/j.vaa.2017.02.003>
- Kells, N.J., Beausoleil, N.J., Johnson, C.B., Sutherland, M.A., Morrison, R.S. and Roe, W., 2017b. Comparison of neural histomorphology in tail tips from pigs docked using clippers or cautery iron. *Animal* 11: 1222-1227. <https://doi.org/10.1017/s1751731116002500>
- Kells, N.J., Beausoleil, N.J., Sutherland, M.A. and Johnson, C.B., 2019. Post-natal development of EEG responses to noxious stimulation in pigs (*Sus scrofa*) aged 1-15 days. *Animal Welfare* 28: 317-329. <https://doi.org/10.7120/09627286.28.3.317>
- Kluyvers-Poodt, M., Houx, B.B., Robben, S.R.M., Koop, G., Lambooi, E. and Hellebrekers, L.J., 2012. Effects of a local anaesthetic and NSAID in castration of piglets, on the acute pain responses, growth and mortality. *Animal* 6: 1469-1475. <https://doi.org/10.1017/s1751731112000547>
- Kluyvers-Poodt, M., Zonderland, J.J., Verbraak, J., Lambooi, E. and Hellebrekers, L.J., 2013. Pain behaviour after castration of piglets; effect of pain relief with lidocaine and/or meloxicam. *Animal* 7: 1158-1162. <https://doi.org/10.1017/S1751731113000086>
- Kritas, S.K. and Morrison, R.B., 2004. An observational study on tail biting in commercial grower-finisher barns. *Journal of Swine Health and Production* 12: 17-22. <https://www.aasv.org/shap/issues/v12n1/v12n1p17.pdf>.
- Kritas, S.K. and Morrison, R.B., 2007. Relationships between tail biting in pigs and disease lesions and condemnations at slaughter. *Veterinary Record* 160: 149-152. <https://doi.org/10.1136/vr.160.5.149>
- Lahrman, H.P., Busch, M.E., D'Eath, R.B., Forkman, B. and Hansen, C.F., 2017. More tail lesions among undocked than tail docked pigs in a conventional herd. *Animal* 11: 1825-1831. <https://doi.org/10.1017/s1751731117000490>
- Langhoff, R., Zols, S., Barz, A., Palzer, A., Ritzmann, M. and Heinritz, K., 2009. Investigation about the use of analgesics for the reduction of castration-induced pain in suckling piglets. *Berliner Und Munchener Tierarztliche Wochenschrift* 122: 325-332. <https://doi.org/10.2376/0005-9366-122-325>

#### 4. Husbandry interventions in suckling piglets, painful consequences and mitigation

- Leslie, E., Hernandez-Jover, M., Newman, R. and Holyoake, P., 2010. Assessment of acute pain experienced by piglets from ear tagging, ear notching and intraperitoneal injectable transponders. *Applied Animal Behaviour Science* 127: 86-95. <https://doi.org/10.1016/j.applanim.2010.09.006>
- Lewis, E., Boyle, L.A., Brophy, P., O'Doherty, J.V. and Lynch, P.B., 2005a. The effect of two piglet teeth resection procedures on the welfare of sows in farrowing crates. Part 2. *Applied Animal Behaviour Science* 90: 251-264. <https://doi.org/10.1016/j.applanim.2004.08.007>
- Lewis, E., Boyle, L.A., Lynch, P.B., Brophy, P. and O'Doherty, J.V., 2005b. The effect of two teeth resection procedures on the welfare of piglets in farrowing crates. Part 1. *Applied Animal Behaviour Science* 90: 233-249. <https://doi.org/10.1016/j.applanim.2004.08.022>
- Llamas Moya, S.L., Boyle, L.A., Lynch, P.B. and Arkins, S., 2008. Effect of surgical castration on the behavioural and acute phase responses of 5-day-old piglets. *Applied Animal Behaviour Science* 111: 133-145. <https://doi.org/10.1016/j.applanim.2007.05.019>
- Lomax, S., Hall, E., Oehlers, L. and White, P., 2018. Topical vapocoolant spray reduces nociceptive response to ear notching in neonatal piglets. *Veterinary Anaesthesia and Analgesia* 45: 366-373. <https://doi.org/10.1016/j.vaa.2016.08.012>
- Lomax, S., Witenden, E., Windsor, P. and White, P., 2017. Effect of topical vapocoolant spray on perioperative pain response of unweaned calves to ear tagging and ear notching. *Veterinary Anaesthesia and Analgesia* 44: 163-172. <https://doi.org/10.1111/vaa.12384>
- Madec, F., Geers, R., Vasseur, P., Kjeldsen, N. and Blaha, T., 2001. Traceability in the pig production chain. *Revue Scientifique et Technique de l'Office International des Epizooties* 20: 523-537. <https://doi.org/10.20506/rst.20.2.1290>
- Marchant-Forde, J.N., Duttlinger, A.W., Richert, B.T. and Johnson, J.S., 2020. Stressors and weaned pig welfare: impact and mitigation. In: Farmer, C. (ed.) *The suckling and weaned piglet*. Wageningen Academic Publishers, Wageningen, the Netherlands, pp. 277-295.
- Marchant-Forde, J.N., Lay, D.C., Jr., McMunn, K.A., Cheng, H.W., Pajor, E.A. and Marchant-Forde, R.M., 2009. Postnatal piglet husbandry practices and well-being: the effects of alternative techniques delivered separately. *Journal of Animal Science* 87: 1479-1492. <https://doi.org/10.2527/jas.2008-1080>
- Marchant-Forde, J.N., Lay, D.C., Jr., McMunn, K.A., Cheng, H.W., Pajor, E.A. and Marchant-Forde, R.M., 2014. Postnatal piglet husbandry practices and well-being: the effects of alternative techniques delivered in combination. *Journal of Animal Science* 92: 1150-1160. <https://doi.org/10.2527/jas.2013-6929>
- Marsalek, P., Svoboda, M., Smutna, M., Blahova, J. and Vecerek, V., 2011. Neopterin and biopterin as biomarkers of immune system activation associated with castration in piglets. *Journal of Animal Science* 89: 1758-1762. <https://doi.org/10.2527/jas.2010-3157>
- Marx, G., Horn, T., Thielebein, J., Knubel, B. and von Borell, E., 2003. Analysis of pain-related vocalization in young pigs. *Journal of Sound and Vibration* 266: 687-698. [https://doi.org/10.1016/s0022-460x\(03\)00594-7](https://doi.org/10.1016/s0022-460x(03)00594-7)
- McGlone, J.J., Nicholson, R.I., Hellman, J.M. and Herzog, D.N., 1993. The development of pain in young pigs associated with castration and attempts to prevent castration-induced behavioral changes. *Journal of Animal Science* 71: 1441-1446.
- Morales, J., Dereu, A., Manso, A., de Frutos, L., Pineiro, C., Manzanilla, E.G. and Wuyts, N., 2017. Surgical castration with pain relief affects the health and productive performance of pigs in the suckling period. *Porcine Health Management* 3. <https://doi.org/10.1186/s40813-017-0066-1>

- Murrell, J.C., Johnson, C.B., White, K.L., Taylor, P.M., Haberham, Z.L. and Waterman-Pearson, A.E., 2003. Changes in the EEG during castration in horses and ponies anaesthetized with halothane. *Veterinary Anaesthesia and Analgesia* 30: 138-146. <https://doi.org/10.1046/j.1467-2995.2003.00138.x>
- Neave, H.W., Daros, R.R., Costa, J.H.C., von Keyserlingk, M.A.G. and Weary, D.M., 2013. Pain and pessimism: dairy calves exhibit negative judgement bias following hot-iron disbudding. *PLoS ONE* 8: 80556. <https://doi.org/10.1371/journal.pone.0080556>
- Noonan, G.J., Rand, J.S., Priest, J., Ainscow, J. and Blackshaw, J.K., 1994. Behavioural observations of piglets undergoing tail docking, teeth clipping and ear notching. *Applied Animal Behaviour Science* 39: 203-213. [https://doi.org/10.1016/0168-1591\(94\)90156-2](https://doi.org/10.1016/0168-1591(94)90156-2)
- Numberger, J., Ritzmann, M., Übel, N., Eddicks, M., Reese, S. and Zöls, S., 2016. Ear tagging in piglets: the cortisol response with and without analgesia in comparison with castration and tail docking. *Animal* 10: 1864-1870. <https://doi.org/10.1017/s1751731116000811>
- O'Connor, A., Anthony, R., Bergamasco, L., Coetzee, J., Gould, S., Johnson, A.K., Karriker, L.A., Marchant-Forde, J.N., Martineau, G.S., McKean, J., Millman, S.T., Niekamp, S., Pajor, E.A., Rutherford, K., Sprague, M., Sutherland, M., von Borell, E. and Dzikamunhenga, R.S., 2014. Pain management in the neonatal piglet during routine management procedures. Part 2: grading the quality of evidence and the strength of recommendations. *Animal Health Research Reviews* 15: 39-62. <https://doi.org/10.1017/s1466252314000073>
- Parois, S., Bonneau, M., Chevillon, P., Larzul, C., Quiniou, N., Robic, A. and Prunier, A., 2018. Odeurs indésirables de la viande de porcs mâles non castrés: problèmes et solutions potentielles. (Boar taint in the meat of entire male pigs: the problems and the potential solutions.) *INRA Productions Animales* 31: 23-35. <https://doi.org/10.20870/productions-animales.2018.31.1.2206>
- Prunier, A., Averos, X., Dimitrov, I., Edwards, S.A., Hillmann, E., Holinger, M., Ilieski, V., Leming, R., Tallet, C., Turner, S.P., Zupan, M. and Camerlink, I., 2019. Review: Early life predisposing factors for biting in pigs. *Animal* 14: 570-587. <https://doi.org/10.1017/S1751731119001940>
- Prunier, A., Bataille, G., Meunier-Salaun, M.C., Bregeon, A. and Rugraff, Y., 2001. Conséquences comportementales, zootechniques et physiologiques de la caudectomie réalisée avec ou sans 'insensibilisation' locale chez le porcelet. (Influence of tail docking, with or without a cold analgesic spray, on the behaviour, performance and physiology of piglets.) *Journées de la Recherche Porcine en France* 33: 313-318. <http://www.journees-recherche-porcine.com/texte/2001/01txtBienetre/B0103.pdf>
- Prunier, A., Bonneau, M., Von Borell, E.H., Cinotti, S., Gunn, M., Frediksen, B., Giersing, M., Morton, D.B., Tuytens, F.A.M. and Velarde, A., 2006. A review of the welfare consequences of surgical castration in piglets and the evaluation of non-surgical methods. *Animal Welfare* 15: 277-289. <https://doi.org/10.1017/S1751731109004728>
- Prunier, A., Gallois, M., Klouyten, A. and Le Cozler, Y., 2004. Effets de l'épointage des dents sur les performances, les lésions cutanées et le comportement des truies et des porcelets. (Influence of tooth resection on performance, skin lesions and behaviour of sows and piglets.) *Journées de la Recherche Porcine* 36: 379-388. <http://www.journees-recherche-porcine.com/texte/2004/04txtBienetre/02be.pdf>
- Prunier, A., Hay, M. and Servière, J., 2002. Evaluation et prévention de la douleur induite par les interventions de conenance chez le porcelet. *Journées de la Recherche Porcine* 34: 257-268. <http://www.journees-recherche-porcine.com/texte/2002/02txtBienetre/BE0201.pdf>

#### 4. Husbandry interventions in suckling piglets, painful consequences and mitigation

- Prunier, A., Mounier, A.M. and Hay, M., 2005. Effects of castration, tooth resection, or tail docking on plasma metabolites and stress hormones in young pigs. *Journal of Animal Science* 83: 216-222. <https://doi.org/10.2527/2005.831216x>
- Prunier, A., Mounier, L., Le Neindre, P., Leterrier, C., Mormède, P., Paulmier, V., Prunet, P., Terlouw, C. and Guatteo, R., 2013. Identifying and monitoring pain in farm animals: a review. *Animal* 7: 998-1010. <https://doi.org/10.1017/S1751731112002406>
- Prunier, A., Tallet, C. and Sandercock, D., 2020. Evidence of pain in piglets subjected to invasive management procedures. In: Edwards, S. (ed.) *Understanding the behaviour and improving the welfare of pigs*. Burleigh Dodds Science Publishing, Cambridge, UK.
- Prus, A.J., James, J.R. and Rosecrans, J.A., 2009. Conditioned place preference. In: Buccafusco, J.J. (ed.) *Methods of behavior analysis in neuroscience*. 2<sup>nd</sup> edition. CRC Press, Boca Raton, FL, USA, pp. 59-76.
- Rajput, K., Reddy, S. and Shankar, H., 2012. Painful neuromas. *Clinical Journal of Pain* 28: 639-645. <https://doi.org/10.1097/AJP.0b013e31823d30a2>
- Rand, J.S., Noonan, G.J., Priest, J., Ainscow, J. and Blackshaw, J.K., 2002. Oral administration of a 12% sucrose solution did not decrease behavioural indicators of distress in piglets undergoing tail docking, teeth clipping and ear notching. *Animal Welfare* 11: 395-404.
- Rault, J.-L., Lay, D.C., Jr. and Marchant-Forde, J.N., 2011. Castration induced pain in pigs and other livestock. *Applied Animal Behaviour Science* 135: 214-225. <https://doi.org/10.1016/j.applanim.2011.10.017>
- Reiner, G., Schollasch, F., Hillen, S., Willems, H., Piechotta, M. and Failing, K., 2012. Effects of meloxicam and flunixin on pain, stress and discomfort in male piglets during and after surgical castration. *Berliner und Munchener Tierarztliche Wochenschrift* 125: 305-314. <https://doi.org/10.2376/0005-9366-125-305>
- Sandercock, D.A., Barnett, M.W., Coe, J.E., Downing, A.C., Nirmal, A.J., Di Giminiani, P., Edwards, S.A. and Freeman, T.C., 2019. Transcriptomics analysis of porcine caudal dorsal root ganglia in tail amputated pigs shows long-term effects on many pain-associated genes. *Frontiers in Veterinary Science* 6: 314. <https://doi.org/10.3389/fvets.2019.00314>
- Sandercock, D.A., Gibson, I.F., Rutherford, K.M.D., Donald, R.D., Lawrence, A.B., Brash, H.M., Scott, E.M. and Nolan, A.M., 2011. The impact of prenatal stress on basal nociception and evoked responses to tail-docking and inflammatory challenge in juvenile pigs. *Physiology and Behavior* 104: 728-737. <https://doi.org/10.1016/j.physbeh.2011.07.018>
- Sandercock, D.A., Smith, S.H., Di Giminiani, P. and Edwards, S.A., 2016. Histopathological characterization of tail injury and traumatic neuroma development after tail docking in piglets. *Journal of Comparative Pathology* 155: 40-49. <https://doi.org/10.1016/j.jcpa.2016.05.003>
- Schembri, N., Toribio, J.A., Sithole, F. and Holyoake, P.K., 2007. Review of identification and traceability legislation for pigs in Australia. *Australian Veterinary Journal* 85: 255-260. <https://doi.org/10.1111/j.1751-0813.2007.00175.x>
- Schoos, A., Devreese, M. and Maes, D.G.D., 2019. Use of non-steroidal anti-inflammatory drugs in porcine health management. *Veterinary Record* 185: 172. <https://doi.org/10.1136/vr.105170>
- Schroöder-Petersen, D. and Simonsen, H., 2001. Tail biting in pigs. *Veterinary Journal* 162: 196-210. <https://doi.org/10.1053/tvj.2001.0605>
- Simonsen, H.B., Klinken, L. and Bindseil, E., 1991. Histopathology of intact and docked pigtails. *British Veterinary Journal* 147: 407-412. [https://doi.org/10.1016/0007-1935\(91\)90082-X](https://doi.org/10.1016/0007-1935(91)90082-X)

- Sinclair, A., D'Eath, R., Brunton, P., Prunier, A. and Sandercock, D., 2018. Long-term effects of piglet tooth resection on molecular markers of inflammation and pain in tooth pulp. In: UFAW Animal Welfare Conference, Newcastle, UK, pp. 14.
- Sinclair, A.R.L., Tallet, C., Renouard, A., Brunton, P.J., D'Eath, R.B., Sandercock, D.A. and Prunier, A., 2019. Behaviour of piglets before and after tooth clipping, grinding or sham-grinding in the absence of social influences. In: 53<sup>rd</sup> Congress of the International Society for Applied Ethology (ISAE), Bergen, Norway. Wageningen Academic Publishers, Wageningen, the Netherlands, pp. 328.
- Sneddon, L.U., Elwood, R.W., Adamo, S.A. and Leach, M.C., 2014. Defining and assessing animal pain. *Animal Behaviour* 97: 201-212. <https://doi.org/10.1016/j.anbehav.2014.09.007>
- Sommavilla, R., Hötzel, M.J. and Dalla Costa, O.A., 2011. Piglets' weaning behavioural response is influenced by quality of human-animal interactions during suckling. *Animal* 5: 1426-1431. <https://doi.org/10.1017/S1751731111000358>
- Sutherland, M.A., 2015. Welfare implications of invasive piglet husbandry procedures, methods of alleviation and alternatives: a review. *New Zealand Veterinary Journal* 63: 52-57. <https://doi.org/10.1080/00480169.2014.961990>
- Sutherland, M.A., Bryer, P.J., Krebs, N. and McGlone, J.J., 2008. Tail docking in pigs: acute physiological and behavioural responses. *Animal* 2: 292-297. 10.1017/s1751731107001450
- Sutherland, M.A., Davis, B.L. and McGlone, J.J., 2011. The effect of local or general anesthesia on the physiology and behavior of tail docked pigs. *Animal* 5: 1237-1246. <https://doi.org/10.1017/s175173111100019x>
- Sutherland, M.A., Davis, B.L., Brooks, T.A. and Coetzee, J.F., 2012. The physiological and behavioral response of pigs castrated with and without anesthesia or analgesia. *Journal of Animal Science* 90: 2211-2221. <https://doi.org/10.2527/jas2011-4260>
- Tallet, C., Brilloüet, A., Meunier-Salaün, M.-C., Paulmier, V., Guérin, C. and Prunier, A., 2013. Effects of neonatal castration on social behaviour, human-animal relationship and feeding activity in finishing pigs reared in a conventional or an enriched housing. *Applied Animal Behaviour Science* 145: 70-83. <https://doi.org/10.1016/j.applanim.2013.03.001>
- Tallet, C., Rakotomahandry, M., Herlemont, S. and Prunier, A., 2019. Evidence of pain, stress, and fear of humans during tail docking and the next four weeks in piglets (*Sus scrofa domestica*). *Frontiers in Veterinary Science* 6: 462. <https://doi.org/10.3389/fvets.2019.00462>
- Taylor, A.A. and Weary, D.M., 2000. Vocal responses of piglets to castration: identifying procedural sources of pain. *Applied Animal Behaviour Science* 70: 17-26. [https://doi.org/10.1016/S0168-1591\(00\)00143-X](https://doi.org/10.1016/S0168-1591(00)00143-X)
- Tenbergen, R., Friendship, R., Cassar, G., Amezcua, M.R. and Haley, D., 2014. Investigation of the use of meloxicam for reducing pain associated with castration and tail docking and improving performance in piglets. *Journal of Swine Health and Production* 22: 64-70. <https://www.aasp.org/shap/issues/v22n2/v22n2p64.pdf>
- Thodberg, K., Herskin, M.S., Jensen, T. and Jensen, K.H., 2018. The effect of docking length on the risk of tail biting, tail-directed behaviour, aggression and activity level of growing pigs kept under commercial conditions. *Animal* 12: 2609-2618. 10.1017/s1751731118000563
- Torrey, S., Devillers, N., Lessard, M., Farmer, C. and Widowski, T., 2009. Effect of age on the behavioral and physiological responses of piglets to tail docking and ear notching. *Journal of Animal Science* 87: 1778-1786. <https://doi.org/10.2527/jas.2008-1354>

#### 4. Husbandry interventions in suckling piglets, painful consequences and mitigation

- Tucker, A.L. and Widowski, T.M., 2009. Normal profiles for deciduous dental eruption in domestic piglets: effect of sow, litter, and piglet characteristics. *Journal of Animal Science* 87: 2274-2281. <https://doi.org/10.2527/jas.2008-1498>
- Übel, N., Zöls, S., Otten, W., Sauter-Louis, C., Heinritzi, K., Ritzmann, M. and Eddicks, M., 2015. Impact of the simultaneous implementation of husbandry procedures on suckling piglets. *Tieraerztliche Praxis Ausgabe Grosstiere Nutztiere* 43: 359-366. <https://doi.org/10.15653/tpg-150385>
- Valros, A. and Heinonen, M., 2015. Save the pig tail. *Porcine Health Management* 1: 2. <https://porcinehealthmanagement.biomedcentral.com/track/pdf/10.1186/2055-5660-1-2>
- Van Beirendonck, S., Driessen, B. and Geers, R., 2011a. Painful standard management practices with piglets: does bundling and/or anesthesia improve animal welfare? *Journal of Anesthesia and Clinical Research in Veterinary Science* 2: 157. <https://doi.org/10.4172/2155-6148.1000157>
- Van Beirendonck, S., Driessen, B., Verbeke, G. and Geers, R., 2011b. Behavior of piglets after castration with or without carbon dioxide anesthesia. *Journal of Animal Science* 89: 3310-3317. <https://doi.org/10.2527/jas.2010-3104>
- Viscardi, A.V. and Turner, P., 2019. A multimodal approach for piglet pain management after tail docking. *Journal of Animal Science* 97: 6-6. <https://doi.org/10.1093/jas/skz122.011>
- Viscardi, A.V. and Turner, P.V., 2018a. Efficacy of buprenorphine for management of surgical castration pain in piglets. *Bmc Veterinary Research* 14: 318. <https://doi.org/10.1186/s12917-018-1643-5>
- Viscardi, A.V. and Turner, P.V., 2018b. Use of meloxicam or ketoprofen for piglet pain control following surgical castration. *Frontiers in Veterinary Science* 5: 299. <https://doi.org/10.3389/fvets.2018.00299>
- von Borell, E., Baumgartner, J., Giersing, M., Jäggin, N., Prunier, A., Tuytens, F.A.M. and Edwards, S.A., 2009. Animal welfare implications of surgical castration and its alternatives in pigs. *Animal* 3: 1488-1496. <https://doi.org/10.1017/S1751731109004728>
- Walker, B., Jaggin, N., Doherr, M. and Schatzmann, U., 2004. Inhalation anaesthesia for castration of newborn piglets: experiences with isoflurane and isoflurane/N<sub>2</sub>O. *Journal of Veterinary Medicine Series A – Physiology Pathology Clinical Medicine* 51: 150-154. <https://doi.org/10.1111/j.1439-0442.2004.00617.x>
- Wallgren, P. and Lindahl, E., 1996. The influence of tail biting on performance of fattening pigs. *Acta Veterinaria Scandinavica* 37: 453-460.
- Weary, D.M. and Fraser, D., 1999. Partial tooth-clipping of suckling pigs: effects on neonatal competition and facial injuries. *Applied Animal Behaviour Science* 65: 21-27. [https://doi.org/10.1016/s0168-1591\(99\)00052-0](https://doi.org/10.1016/s0168-1591(99)00052-0)
- Weary, D.M., Droege, P. and Braithwaite, V.A., 2017. Behavioral evidence of felt emotions: approaches, inferences, and refinements. In: Naguib, M., Podos, J., Simmons, L.W., Barrett, L., Healy, S.D. and Zuk, M. (eds.) *Advances in the study of behavior*. Academic Press, Cambridge, MA, USA, pp. 27-48. <https://doi.org/10.1016/bs.asb.2017.02.002>
- Weary, D.M., Niel, L., Flower, F.C. and Fraser, D., 2006. Identifying and preventing pain in animals. *Applied Animal Behaviour Science* 100: 64-76. <https://doi.org/10.1016/j.applanim.2006.04.013>
- White, F.A., Bhangoo, S.K. and Miller, R.J., 2005. Chemokines: integrators of pain and inflammation. *Nature Reviews Drug Discovery* 4: 834-844. <https://doi.org/10.1038/nrd1852>
- Woolf, C.J. and Ma, Q.F., 2007. Nociceptors-noxious stimulus detectors. *Neuron* 55: 353-364. <https://doi.org/10.1016/j.neuron.2007.07.016>



- Xue, Y., Zheng, W., Zhang, F., Rao, S., Peng, Z. and Yao, W., 2019. Effect of immunocastration on growth performance, gonadal development and carcass and meat quality of SuHuai female pigs. *Animal Production Science* 59: 794-800. <https://doi.org/10.1071/AN16733>
- Yun, J., Ollila, A., Valros, A., Larenza-Menzies, P., Heinonen, M., Oliviero, C. and Peltoniemi, O., 2019. Behavioural alterations in piglets after surgical castration: effects of analgesia and anaesthesia. *Research in Veterinary Science* 125: 36-42. <https://doi.org/10.1016/j.rvsc.2019.05.009>