



Cardiac magnetic resonance assessment of left ventricular dilatation in chronic severe left-sided regurgitations: comparison with standard echocardiography

T. Capron, J. Cautela, U. Scemama, C. Miola, A. Bartoli, A. Theron, J. Pinto, A. Porto, F. Collart, H. Lepidi, et al.

► To cite this version:

T. Capron, J. Cautela, U. Scemama, C. Miola, A. Bartoli, et al.. Cardiac magnetic resonance assessment of left ventricular dilatation in chronic severe left-sided regurgitations: comparison with standard echocardiography. *Diagnostic and Interventional Imaging*, 2020, 101 (10), pp.657-665. 10.1016/j.diii.2020.04.014 . hal-03156212

HAL Id: hal-03156212

<https://hal.inrae.fr/hal-03156212>

Submitted on 17 Oct 2022

HAL is a multi-disciplinary open access archive for the deposit and dissemination of scientific research documents, whether they are published or not. The documents may come from teaching and research institutions in France or abroad, or from public or private research centers.

L'archive ouverte pluridisciplinaire **HAL**, est destinée au dépôt et à la diffusion de documents scientifiques de niveau recherche, publiés ou non, émanant des établissements d'enseignement et de recherche français ou étrangers, des laboratoires publics ou privés.



Distributed under a Creative Commons Attribution - NonCommercial 4.0 International License

Cardiac magnetic resonance assessment of left ventricular dilatation in chronic severe left-sided regurgitations: comparison with standard echocardiography

Short title:

CMR left ventricular dilatation in regurgitations

Thibaut CAPRONa*, Jennifer CAUTELAb,c, Ugo SCEMAMAd, Charlène MIOLAb, Axel BARTOLIIa,e, Alexis THERONf, Johan PINTOb, Alizée PORTOf, Frédéric COLLARTf, Hubert LEPIDIg, Monique BERNARDa, Maxime GUYEa, Franck THUNYb,c, Jean-François AVIERINOSH and Alexis JACQUIERa,e

^aAix-Marseille Université, CNRS, CRMBM (Centre de Résonance Magnétique Biologique et Médicale) and Assistance Publique - Hôpitaux de Marseille, CEMEREM (Centre d'Exploration Métaboliques par Résonance Magnétique), 13385 Marseille, France

^bAix-Marseille Université, Assistance Publique - Hôpitaux de Marseille, Mediterranean university Cardio-Oncology center (Medi-CO center), Unit of Heart Failure and Valvular Heart Diseases, Department of Cardiology, Hôpital Nord, 13015 Marseille, France

^cAix-Marseille Université, Center for CardioVascular and Nutrition research (C2VN), Inserm 1263, Inra 1260, 13385 Marseille France

^dAix-Marseille Université, Assistance Publique - Hôpitaux de Marseille, Department of Radiology, Hôpital Nord, 13015 Marseille, France

^eAssistance Publique - Hôpitaux de Marseille, Department of Radiology and Cardiovascular Imaging, Hôpital Timone, 13385 Marseille, France

^fAix-Marseille Université, Assistance Publique - Hôpitaux de Marseille, Department of Cardio-thoracic surgery, Hôpital Timone, 13385 Marseille, France

^gAix-Marseille Université, Assistance Publique - Hôpitaux de Marseille, Laboratoire d'anatomie pathologique, Hôpital Timone, 13385 Marseille, France

^hAix-Marseille Université, Assistance Publique - Hôpitaux de Marseille, Department of Cardiology, Hôpital Timone, 13385 Marseille, France

***Corresponding author** thibaut.capron@ap-hm.fr

Aix-Marseille Université, UMR 7339, CNRS, Centre de Résonance Magnétique Biologique et Médicale – Centre d'Exploration Métabolique par Résonance Magnétique, Assistance Publique des Hôpitaux de Marseille, 13385 Marseille, FRANCE

Abstract

Purpose: The purpose of this study was to investigate the potential additional value of cardiac magnetic resonance (CMR) in the assessment of left ventricular (LV) dilatation and dysfunction by comparison to standard echocardiography in patients with chronic left-sided valvular regurgitation.

Materials and methods: We prospectively enrolled patients with chronic severe mitral regurgitation (MR) or aortic regurgitation (AR). They underwent standard echocardiography and CMR using aortic flow and LV-function sequences. LV dilatation or dysfunction was assessed with each technique, based on thresholds used for surgery indication. Reference regurgitation severity was defined following previously reported CMR-based regurgitant volume thresholds.

Results: A total of 71 patients with chronic severe MR ($n = 44$) or severe AR ($n = 27$) were prospectively included. There were 60 men and 11 women with a mean age of 61 ± 14 (SD) years (range: 18 - 83 years). CMR-based regurgitation severity was significantly greater in the LV dysfunction group when assessed with CMR (MR, $P = 0.011$; AR, $P = 0.006$) whereas it was not different when LV dysfunction was assessed using standard echocardiography. Among standard echocardiography and CMR volumetric indices, CMR-derived end-diastolic volume showed the best ability to predict regurgitation severity (area under the curve [AUC] = 0.78 for MR; AUC = 0.91 for AR). Diagnostic thresholds identified on receiver operating characteristics-curve analysis were lower than those of current European recommendations and closer to North-American guidelines.

Conclusion: CMR assessment of LV end-diastolic volume in chronic severe left-sided regurgitations is more reliably associated with CMR-based regurgitant volume by comparison with standard echocardiography diameter. CMR may provide useful evaluation before surgery decision for severe asymptomatic regurgitations.

Keywords: Ventricular dysfunction, left; Cardiac magnetic resonance imaging (CMR); Mitral valve insufficiency; Aortic valve insufficiency; Echocardiography

List of abbreviations

AR: aortic regurgitation

AUC: area under the curve

BP: blood pressure

BSA: body surface area

bSSFP: balanced steady-state free precession

CMR: cardiac magnetic resonance

EC: echocardiography

ECG: electrocardiogram

EDV: end-diastolic volume

EROA: effective regurgitant orifice area

ESV: end-systolic volume

LV: left ventricular

LVEF: left ventricular ejection fraction

LVESD: left ventricular end-systolic diameter

MR: mitral regurgitation

ROC: receiver operating characteristics

SD: standard deviation

Chronic primary mitral regurgitation (MR) and aortic regurgitation (AR) induce left ventricular (LV) dilatation and eccentric hypertrophy due to volume or volume plus pressure overload. It leads to subsequent dysfunction. Patients' management is based on surgical valve repair or replacement and timing of the intervention is a crucial point; it has to be performed before LV dysfunction or dilatation becomes irreversible [1]. Surgical decision is mainly based on patients' symptoms but some of them remain asymptomatic even in the presence of severe regurgitation. Consequently, early surgery is debated in asymptomatic patients in the absence of clear and consensual marker to identify best timing for surgical benefit [2,3].

Echocardiography is the reference modality for first-line assessment of valvular heart diseases [4]. Class I guidelines for surgery clinical decision in asymptomatic patients are currently based on the assessment of LV dysfunction or dilatation, measuring LV-diameter with echocardiography [5,6]. During last years, cardiac magnetic resonance (CMR) has proven great performance in the evaluation of a variety of cardiac abnormalities [7,8] and valvular heart diseases, owing to its high reproducibility [9]. Furthermore, the regurgitant volume

measured with CMR is a clinically relevant parameter. It is correlated to the benefit obtained after surgery [10,11] and is considered as a potential predictive parameter for disease evolution [12-14] with respect to echocardiographic parameters. However, in patients with severe regurgitations that are the main candidates for valvular surgery, regurgitant volume assessment with CMR and echocardiography has shown important discrepancies [10,15,16]. In this population, the use of echocardiography parameters for surgery decision making is thus questionable.

As a result, we aimed to investigate the potential additional value of CMR for clinical decision in severe chronic regurgitations. Based on literature above-cited reports, the CMR-derived regurgitant volume was used as a surrogate for clinical regurgitation severity. We compared routine echocardiography and CMR parameters for LV dilatation and dysfunction. We assumed that a more accurate evaluation of LV dilatation would have greater ability to predict clinical regurgitation severity.

The purpose of this study was to examine the performance of CMR, in comparison to echocardiography, in the assessment LV dilatation.

Material and methods

Study population

We prospectively enrolled consecutive patients with moderate-to-severe chronic primary MR or AR referred to our center for pre-surgical evaluation from February 2015 to July 2018. For inclusion, grading of MR/AR severity was based on echocardiography using effective regurgitant orifice area (EROA) ($> 30 \text{ mm}^2$ for MR and $> 20 \text{ mm}^2$ for AR) and/or regurgitant volume ($> 45 \text{ mL}$ for MR and AR). Indication for surgery was discussed in multidisciplinary concert following standard criteria from the European Society of Cardiology [6], blinded to the results of CMR. Patients with CMR contra-indications, clinical instability, irregular rhythm, known coronary artery disease, severe arterial hypertension, previous cardiac surgery and concomitant moderate to severe mitral or aortic stenosis were not included. All participants underwent clinical evaluation of symptomatic status (dyspnea graded according to New York Heart Association classification) and signs for heart failure. All but 9 participants had brain natriuretic peptide dosage in blood. Echocardiography and CMR examinations were performed in all patients before decision for surgery intervention. The study was conducted according to the Declaration of Helsinki. Ethics committee gave approval to the protocol (CPP #2015-A00587-42) and written informed consent was obtained from all participants.

Echocardiography

Echocardiography was performed according to a standardized protocol using an Epiq 7[®] imaging system (Philips Healthcare). Image acquisition, analysis and grading of regurgitation severity were performed in accordance with current recommendations [4] by four cardiologists having several years of echocardiographic imaging experience, blinded to the results of CMR. The following data were collected prospectively: EROA, regurgitant volume, etiology of the valvular damages, end-systolic (LVESD) LV diameters (Time-motion or 2D mode), end-diastolic (EDV_{EC}) / end-systolic (ESV_{EC}) LV volumes, LV ejection fraction (LVEF_{EC}) (by the Simpson biplane method) and left atrial volume according to the surface-length method. Trans-oesophageal echocardiogram was performed if necessary to clarify the degree of severity and the regurgitation mechanism. The images were stored in DICOM format (DVD ROM), and interpreted on the QLAB[®] station (Philips Healthcare).

A composite criterion for LV dilatation or dysfunction was built following current european recommendations for surgical intervention in asymptomatic patients [6]. For MR, LV dysfunction assessed by echocardiography was defined if LVEF_{EC} ≤ 60 % or LVESD ≥ 45 mm. For AR, LV dysfunction assessed by echocardiography was defined if LVEF_{EC} ≤ 50 % or LVESD ≥ 50 mm or body surface area (BSA)-indexed LVESDi ≥ 25 mm/m².

Cardiac magnetic resonance imaging

CMR images were obtained with a commercially available 1.5 T scanner (Amira[®] or Aera[®], Siemens Healthineers) with a 6-channel phased array cardiac coil. Retrospective electrocardiogram (ECG)-gating and expiratory breath-hold was used for all sequences. Cine images were acquired using balanced steady-state free precession (bSSFP) sequences in order to locate the aortic valve plane accurately. ECG-gated phase-contrast velocity encoded sequences were acquired at the level of sinotubular junction using the following parameters: TR = 20.3 ms; TE = 3.04 ms; flip angle = 30°; 29 phases/cycle; field of view = 350 x 263 mm²; pixel size = 1.8 x 1.8 mm²; slice thickness = 5.5 mm. The potential for background phase errors was reduced by placing the region of interest at isocenter of the magnet [17].

Left ventricular function was assessed using an ECG-gated cine bSSFP stack of short-axis slices covering the entire heart volume with the following parameters: TR = 31.6 ms; TE = 1.17 ms; flip angle 76°; field of view = 340 x 291 mm²; pixel size = 1.5 x 1.5 mm²; and slice thickness = 7 mm.

Aortic flow curves were analyzed by one operator blinded to the results of

echocardiography, using the image analysis software Medis suite QFlow 8.1[®] (Medis). Contours of the aorta were initially automatically detected and then manually adjusted for each phase of the cardiac cycle (Figure 1). The resulting flow curve along cardiac cycle was further corrected for background offset errors [17,18] using a stationary flow fit correction provided by the software manufacturer; pixels considered as stationary on the whole velocity-encoded image were manually selected by the operator. Regurgitant volume in AR (ARVol) was directly obtained from standard method of integrated retrograde flow [19]. In MR, regurgitant volume (MRVol) was obtained by subtraction of anterograde aortic flow to the LV stroke volume calculated from LV function analysis. This method is the most commonly used and is not affected by other concomitant valve disease [20].

LV metrics were obtained using image analysis software Medis suite QMass 8.1[®] (Medis). Epicardial and endocardial borders of left ventricle were manually drawn in end-systolic and end-diastolic phases for all slices (Figure 1). The procedure allowed for estimation of LVEF_{CMR}, BSA-indexed end-systolic and end-diastolic volumes (ESV_{CMRi}, EDV_{CMRi}) and myocardial mass. LV dilatation was defined with CMR using EDV_{CMRi} \geq 90 mL/m², based on previously reported normal values for EDV with CMR in elderly people, taking mean + 2 \times standard deviation as threshold [21].

As a result, LV dysfunction criterion as assessed by CMR was defined inspired from echocardiography using LVEF_{CMR} \leq 60 % or EDV_{CMRi} \geq 90 mL/m² for MR and LVEF_{CMR} \leq 50 % or EDV_{CMRi} \geq 90 mL/m² for AR [6].

In order to assess diagnostic performance of volumetric indices of LV dilatation, regurgitation severity was defined above a CMR-derived regurgitant volume threshold. It was based on previously reported thresholds for prediction of clinical outcomes [11-14,16]. We used MRVol \geq 60 mL for MR and ARVol \geq 40 mL for AR as reference values to identify severe regurgitations.

Statistical analysis

Statistical analysis was performed using the software GraphPad PRISM[®] 5.0a (San Diego California USA, www.graphpad.com). Quantitative variables were expressed as means, SD and ranges, qualitative variables as raw numbers, proportions and percentages. Correlation of quantitative values was determined using Pearson correlation coefficient for Gaussian-distributed variables and Spearman correlation coefficient otherwise. Statistical significance for group comparison was assessed with unpaired bilateral Student *t*-test and

additional Welch's correction accounted for variance differences between groups when statistically significant.

Receiver operating characteristics (ROC) curve analysis was used to establish diagnostic performance for each investigated volumetric parameter assessed using echocardiography (LVESD, ESV_{EC} , EDV_{EC} for MR; LVESD, ESV_{EC} , EDV_{EC} and LVESDi for AR) or CMR (ESV_{CMRi} , EDV_{CMRi}). Regurgitant severity was fixed from CMR-derived above-defined threshold and sensitivity/specificity was calculated for various threshold values of the dimensional parameter considered, thereby constructing the ROC curve. The operator assessed the optimal diagnostic threshold as the furthestmost point from identity line, unless otherwise stated. All tests were two-tailed and P values < 0.05 were considered as significant.

Results

A total of 71 patients with chronic severe MR ($n = 44$) or severe AR ($n = 27$) were prospectively included. There were 60 men and 11 women with a mean age of 61 ± 14 (SD) years (range: 18 - 83 years). Due to some missing data, the number of subjects slightly differs in the following analyses, depending on the variables of interest. Figure 1 shows the study flow chart.

Baseline characteristics of the study population are summarized in Table 1. Mean regurgitant volume for MR (MRVol) was 84 ± 30 (SD) mL (range: 30 - 163 mL) using echocardiography and 59 ± 30 (SD) mL (range: 6 - 121 mL) using CMR. For AR, mean regurgitant volume (ARVol) was 81 ± 31 (SD) mL (range: 41 - 151 mL) measured by echocardiography and was 41 ± 22 (SD) mL (range: 9 - 75 mL) using CMR. Bias between echocardiography and CMR regurgitant volumes was 26 mL for MR and 40 mL for AR. Correlation coefficient between the two measuring methods was $r = 0.32$ ($P = 0.066$) for MR and $r = 0.18$ ($P = 0.49$) for AR.

There was no statistically significant relation between clinical variables (NYHA class, heart failure signs, brain natriuretic peptide) and regurgitant volumes assessed by either echocardiography or CMR, in MR and in AR.

LV dysfunction criterion assessed by echocardiography was present in 16/36 (44 %) patients with MR and 10/23 (44 %) patients with AR. Mean regurgitant volumes assessed by CMR and echocardiography are presented in Figure 3, comparing patients with echocardiography-defined LV dysfunction (group D_{EC+}) and patients without echocardiography-defined LV dysfunction (group D_{EC-}). The mean regurgitant volumes did not

show statistically significant difference between groups in MR ($P = 0.08$ for echocardiography and $P = 0.99$ for CMR) as well as in AR ($P = 0.09$ for echocardiography and $P = 0.55$ for CMR).

The mean LV dimensional parameters measured with echocardiography (LVESD, EDV_{EC} and ESV_{EC}) and CMR (EDV_{CMR} and ESV_{CMR}) are reported in Table 2. Figure 4 presents the linear correlation assessment between CMR-derived regurgitant volume and LV dilatation. This latter parameter was assessed by echocardiography (standard LVESD) and CMR (EDV_{CMR}), in MR (top) and AR (bottom). A stronger and significant correlation was found when LV dilatation was assessed with CMR in the MR group ($r = 0.65$; $P < 0.0001$ for EDV_{CMRi} vs. $r = 0.13$; $P = 0.44$ for LVESD) as well as in the AR group ($r = 0.79$; $P < 0.0001$ for EDV_{CMRi} vs. $r = 0.33$; $P = 0.12$ for LVESD). Similar analysis with echocardiography-derived regurgitant volume as a reference also showed weaker correlations.

LV dysfunction assessed by CMR as defined above was present in 30/37 (81 %) patients with MR and in 18/23 (78 %) patients with AR. Mean regurgitant volumes assessed by CMR and echocardiography, comparing patients with CMR-defined LV dysfunction (group D_{CMR+}) and patients without CMR-defined LV dysfunction (group D_{CMR-}) are presented in Figure 5. The CMR-derived regurgitant volume was significantly larger in the D_{CMR+} group compared to the D_{CMR-} group for both sites of regurgitation (MRVol, 64 ± 29 [SD] mL vs. 34 ± 13 [SD] mL [$P=0.011$]; ARVol, 44 ± 22 [SD] mL vs. 23 ± 9 [SD] mL [$P=0.006$]). In contrast, echocardiography-derived regurgitant volume was not significantly different in these two dysfunction groups ($P = 0.33$ for mitral regurgitant volume by echocardiography; $P = 0.12$ for aortic regurgitant volume by echocardiography).

Ability of dimensional indices of LV dilatation to predict regurgitation severity is reported in Table 3 for MR and Table 4 for AR. Using CMR-derived regurgitant volume as the reference for regurgitation severity as described in the Methods section, sensitivity/sensibility was calculated for each threshold values of the studied dimensional parameter, thereby building the ROC curves presented in Figure 6. Area under ROC curve (AUC) and optimal threshold for each dimensional parameter have been subsequently derived (Tables 3 and 4).

In both regurgitation groups, indexed end-diastolic volume measured with CMR provided the largest AUC whereas LVESD showed non-significant AUC with respect to the no-discrimination line. Echocardiography-derived end-diastolic volume showed lower discrimination capabilities (AUC, 0.71 vs. 0.78 for MR, respectively; AUC, 0.86 vs. 0.91 for AR, respectively) by comparison with CMR-derived end-diastolic volume.

The thresholds identified to provide best discriminating capabilities (optimal thresholds) were EDV_{CMRi} ≥ 92 mL/m² for MR and EDV_{CMRi} ≥ 95 mL/m² for AR (Figure 6).

From ROC curve analysis for LVESD, we identified thresholds of LVESD ≥ 37 mm for MR and LVESD ≥ 40 mm or LVESDi ≥ 19 mm/m² for AR.

Direct comparison of echocardiography and CMR volumes are reported in Table 2. Regarding end-diastolic volumes, EDV_{ECi} was 17 % smaller than EDV_{CMRi} in MR (90 ± 24 [SD] vs. 108 ± 28 [SD] mL/m²) and was 11 % smaller in AR (101 ± 22 [SD] vs. 114 ± 35 [SD] mL/m²).

Discussion

In this study, we investigated additional value of CMR for the assessment of LV dysfunction or dilatation in comparison to echocardiography, in a cohort of severe chronic regurgitations. We found that LV dysfunction or dilatation assessed by CMR (using ejection fraction and indexed end-diastolic volume) well separates different severity groups for regurgitant volume, whereas current standard-based echocardiography parameters fail (using ejection fraction and LV diameter). Moreover, LV dilatation appears to be more closely related to the regurgitant volume when assessed using end-diastolic volume with CMR, which showed the best discriminatory ability for prediction of regurgitant volume severity. Finally, echocardiography dilatation thresholds identified in this work, though they have to be interpreted with caution, are much lower than current European recommendations.

This study found an important discordance between echocardiography and CMR-derived regurgitant volumes. A certain degree of discordance has been previously reported in moderate-to-severe regurgitations [10,15,16,22,23] by many groups. Such differences are attributed to geometrical assumptions made for the proximal isovelocity surface area method, temporal variability of regurgitation or indirect multifactorial formula prone to variability. In comparison to previous studies, our study is unique because it reports on a cohort of severe regurgitations only; focus on previously published data also shows greater discordance between echocardiography and CMR for severe regurgitations, whereas quantification is consistent for mild to moderate regurgitations. The discordance found in this work is thus consistent with previous studies and emphasizes pitfalls in echocardiography-assessment of severe regurgitations. Recent regurgitant volume quantification based on 3-dimensionnal echocardiography showed improved agreement with CMR [24,25].

In our cohort of patients with severe regurgitation, no correlations were found between clinical parameters and echocardiography or CMR-derived parameters. This is not surprising as

asymptomatic patients may present with severe regurgitation. Even objective clinical markers such as brain natriuretic peptide did not reflect LV remodeling in valvular heart disease [26].

CMR is the gold standard for evaluation of ventricular volumes and function [27,28]. In this study, we found systematically lower LV volumes with echocardiography than with CMR, as previously reported in MR patients [29]. Though current recommendations for LV dilatation assessment rely on LV diameter, it is highly plausible that volumes yield more sensitive and accurate information, as remodeling may not be concentric. Chuang et al. demonstrated the superiority of volumetric compared to biplane methods for quantification of ventricular volumes and function [30]. More recently, it has been shown that in patients with chronic regurgitation CMR-derived LV volumes better reflect LV remodeling than LV diameter, before [31] and after valve replacement [32].

As a result, in severe regurgitation, first-line echocardiography overestimates regurgitant volume but underestimates LV dilatation when using diameter and may misclassify LV function in MR. Based on CMR-derived regurgitant volume, which is the *primum movens* for remodeling, our results show that LV dysfunction or dilatation was more reliably assessed by CMR. It is important to notice that end-diastolic volume obtained with echocardiography also performed well in the prediction of regurgitation severity, though the AUC was lower than with CMR.

The choice for using CMR-derived regurgitant volume as a surrogate for clinical regurgitation severity relies on several important studies demonstrating that this parameter has a high predictive value for disease evolution [12-14] or for positive post-operative outcome [10,11]. In all these studies on moderate-to-severe regurgitations, ventricular volumes also showed good predictive ability though lower than CMR-derived regurgitant volume. The crucial point that we emphasize in this study is that in asymptomatic patients the surgery decision will be taken on LV diameter. Recent work in MR also found a good discriminatory ability of echocardiography-derived LV end-diastolic volume in the context of moderate correlation between echocardiography and CMR regurgitant volumes [33], which is the case in severe regurgitations. Results of our study confirm these previously published trends and we argue that CMR assessment of dilatation is especially relevant in asymptomatic severe regurgitations.

ROC curve analysis allows for identification of optimal thresholds to separate regurgitation severity in our cohort. Though they should be interpreted with caution, LVESD thresholds in our work are much lower than current European guidelines and closer to north-american guidelines. Regarding MR, Kitai et al. found a LVESD threshold of 39 mm for

maintaining post-operative LV function at 3 years [34], and Tribouilloy et al. found LVESD threshold of 40 mm for worse clinical outcome [35]. Interestingly, indexed CMR end-diastolic volume thresholds were quite uniform between MR, AR and previously established upper values in healthy elderly population [21], around 90 mL/m². Our results are a plea for lowering current thresholds, at least for screening, and using CMR-derived thresholds for LV dilatation in difficult cases.

Accurate assessment of LV dysfunction in pre-operative asymptomatic patients has fundamental importance as it directly guides the clinical surgery decision. Valve replacement or repair is intended to improve LV function [36] but LV dysfunction may develop post-operatively if surgery is performed too late [37]. Thus the question of early surgery is relevant but demonstrates equivocal results [38,39]. There is a need for better selection of candidates for surgery, which would be operated at the correct timing ensuring a clinical benefit. Other markers of early myocardial damage may have great potential in this issue [40].

Limitations of this work comprise a limited number of patients enrolled in a single center, thus hampering extrapolation of the results. We used an indirect parameter for classification of regurgitation severity, the CMR-derived regurgitant volume, as a surrogate of clinical outcome based on previous literature reports. The usefulness of CMR for surgery decision in this context still have to be demonstrated, further studies should directly investigate clinical outcomes or post-operative remodeling to refine pre-operative LV thresholds. A large proportion of the patients routinely addressed with severe regurgitations are symptomatic, so it is in our study cohort. We believe the extrapolation from symptomatic to asymptomatic severe regurgitations can be done, as the investigated parameters are not related to symptoms. We considered only chronic regurgitations in this work and results are likely not applicable to acute mitral or aortic regurgitations; such acute event may arise before establishment of LV dilatation with a potentially large EROA but mild-to-moderate regurgitant volume due to high filling pressures.

In conclusion, CMR assessment of LV dilatation and dysfunction in chronic severe left-sided regurgitations is more reliably associated with regurgitation severity than standard echocardiography-derived LV diameter. CMR may provide particularly useful in severe regurgitations where discordance with echocardiography is more important, and asymptomatic regurgitations for which surgery decision is based on LV size.

Conflict of interest

The authors have no conflict of interest to disclose.

Authorship contribution statement

All authors attest that they meet the current International Committee of Medical Journal Editors (ICMJE) criteria for Authorship.

This research did not receive any specific grant from funding agencies in the public, commercial, or not-for-profit sectors.

References

1. Ross J. Afterload mismatch in aortic and mitral valve disease: implications for surgical therapy. *J Am Coll Cardiol* 1985;5:811-26.
2. Enriquez-Sarano M, Sundt TM. Early surgery is recommended for mitral regurgitation. *Circulation*. 2010;121:804-12.
3. Gillam LD, Schwartz A. Primum non nocere: the case for watchful waiting in asymptomatic « severe » degenerative mitral regurgitation. *Circulation* 2010;121:813-21.
4. Lancellotti P, Tribouilloy C, Hagendorff A, Popescu BA, Edvardsen T, Pierard LA, et al. Recommendations for the echocardiographic assessment of native valvular regurgitation: an executive summary from the European Association of Cardiovascular Imaging. *Eur Heart J Cardiovasc Imaging* 2013;14:611-44.
5. Nishimura RA, Otto CM, Bonow RO, Carabello BA, Erwin JP, Guyton RA, et al. 2014 AHA/ACC guideline for the management of patients with valvular heart disease. *J Thorac Cardiovasc Surg* 2014;148:1-132.
6. Baumgartner H, Falk V, Bax JJ, De Bonis M, Hamm C, Holm PJ, et al. 2017 ESC/EACTS Guidelines for the management of valvular heart disease. *Eur Heart J* 2017;38:2739-91.
7. Bentatou Z, Finas M, Habert P, Kober F, Guye M, Bricq S et al. Distribution of left ventricular trabeculation across age and gender in 140 healthy Caucasian subjects on MR imaging. *Diagn Interv Imaging* 2018;99:689-98.
8. Wong TS, Bejar S, Michelin P, Dubourg B, Dacher JN. MR imaging of catecholamine-mediated myocarditis complicated by left ventricular thrombus. *Diagn Interv Imaging* 2018;99:337-8.
9. Gulsin GS, Singh A, McCann GP. Cardiovascular magnetic resonance in the evaluation of heart valve disease. *BMC Med Imaging* 2017;17:67.
10. Uretsky S, Gillam L, Lang R, Chaudhry FA, Argulian E, Supariwala A, et al. Discordance between echocardiography and MRI in the assessment of mitral regurgitation severity. *J Am Coll Cardiol* 2015;65:1078-88.
11. Polte CL, Gao SA, Johnsson ÅA, Lagerstrand KM, Bech-Hanssen O. Characterization of chronic aortic and mitral regurgitation undergoing valve surgery using cardiovascular magnetic resonance. *Am J Cardiol* 2017;119:2061-8.
12. Harris AW, Krieger EV, Kim M, Cawley PJ, Owens DS, Hamilton-Craig C, et al. Cardiac magnetic resonance imaging versus transthoracic echocardiography for prediction of outcomes in chronic aortic or mitral regurgitation. *Am J Cardiol* 2017;119:1074-81.
13. Myerson SG, d'Arcy J, Mohiaddin R, Greenwood JP, Karamitsos TD, Francis JM, et al. Aortic regurgitation quantification using cardiovascular magnetic resonance: association with clinical outcome. *Circulation* 2012;126:1452-60.
14. Myerson SG, d'Arcy J, Christiansen JP, Dobson LE, Mohiaddin R, Francis JM, et al. Determination of clinical outcome in mitral regurgitation with cardiovascular magnetic resonance quantification. *Circulation* 2016;133:2287-96.
15. Cawley PJ, Hamilton-Craig C, Owens DS, Krieger EV, Strugnell WE, Mitsumori L, et al. Prospective comparison of valve regurgitation quantitation by cardiac magnetic resonance imaging and transthoracic echocardiography. *Circ Cardiovasc Imaging* 2013;6:48-57.
16. Gabriel RS, Renapurkar R, Bolen MA, Verhaert D, Leiber M, Flamm SD, et al. Comparison of severity of aortic regurgitation by cardiovascular magnetic resonance versus transthoracic echocardiography. *Am J Cardiol* 2011;108:1014-20.
17. Gatehouse PD, Rolf MP, Graves MJ, Hofman MB, Totman J, Werner B, et al. Flow measurement by cardiovascular magnetic resonance: a multi-centre multi-vendor study of

background phase offset errors that can compromise the accuracy of derived regurgitant or shunt flow measurements. *J Cardiovasc Magn Reson* 2010;12:5.

18. Chernobelsky A, Shubayev O, Comeau CR, Wolff SD. Baseline correction of phase contrast images improves quantification of blood flow in the great vessels. *J Cardiovasc Magn Reson*. 2007;9:681-5.

19. Lee JC, Branch KR, Hamilton-Craig C, Krieger EV. Evaluation of aortic regurgitation with cardiac magnetic resonance imaging: a systematic review. *Heart*. 2018;104:103-10.

20. Krieger EV, Lee J, Branch KR, Hamilton-Craig C. Quantitation of mitral regurgitation with cardiac magnetic resonance imaging: a systematic review. *Heart*. 2016;102:1864-70.

21. Kawel-Boehm N, Maceira A, Valsangiacomo-Buechel ER, Vogel-Claussen J, Turkbey EB, Williams R, et al. Normal values for cardiovascular magnetic resonance in adults and children. *J Cardiovasc Magn Reson* 2015;17-29.

22. Lopez-Mattei JC, Ibrahim H, Shaikh KA, Little SH, Shah DJ, Maragiannis D, et al. Comparative assessment of mitral regurgitation severity by transthoracic echocardiography and cardiac magnetic resonance using an integrative and quantitative approach. *Am J Cardiol*. 2016;117:264-70.

23. Penicka M, Vecera J, Mirica DC, Kotrc M, Kockova R, Van Camp G. Prognostic implications of magnetic resonance–derived quantification in asymptomatic patients with organic mitral regurgitation: comparison with doppler echocardiography–derived integrative approach. *Circulation*. 2018;137:1349-60.

24. Brugger N, Wustmann K, Hürzeler M, Wahl A, de Marchi SF, Steck H, et al. Comparison of three-dimensional proximal isovelocity surface area to cardiac magnetic resonance imaging for quantifying mitral regurgitation. *Am J Cardiol*. 2015;115:1130-6.

25. Levy F, Marechaux S, Iacuzio L, Schouver ED, Castel AL, Toledano M, et al. Quantitative assessment of primary mitral regurgitation using left ventricular volumes obtained with new automated three-dimensional transthoracic echocardiographic software: A comparison with 3-Tesla cardiac magnetic resonance. *Arch Cardiovasc Dis*. 2018;111:507-17.

26. Sharma V, Stewart RA, Lee M, Gabriel R, Van Pelt N, Newby DE, et al. Plasma brain natriuretic peptide concentrations in patients with valvular heart disease. *Open Heart*. 2016;3-e000184.

27. Sechtem U, Pflugfelder PW, Gould RG, Cassidy MM, Higgins CB. Measurement of right and left ventricular volumes in healthy individuals with cine MR imaging. *Radiology*. 1987;163:697-702.

28. Hundley WG, Bluemke DA, Finn JP, Flamm SD, Fogel MA, Friedrich MG, et al. ACCF/ACR/AHA/NASCI/SCMR 2010 Expert consensus document on cardiovascular magnetic resonance. *J Am Coll Cardiol*. 2010;55:2614-62.

29. Van De Heyning CM, Magne J, Piérard LA, Bruyère P-J, Davin L, De Maeyer C, et al. Assessment of left ventricular volumes and primary mitral regurgitation severity by 2D echocardiography and cardiovascular magnetic resonance. *Cardiovasc Ultrasound*. 2013;11.

30. Chuang ML, Hibberd MG, Salton CJ, Beaudin RA, Riley MF, Parker RA, et al. Importance of imaging method over imaging modality in noninvasive determination of left ventricular volumes and ejection fraction: assessment by two- and three-dimensional echocardiography and magnetic resonance imaging. *J Am Coll Cardiol*. 2000;35:477-84.

31. Uretsky S, Supariwala A, Nidadovolu P, Khokhar SS, Comeau C, Shubayev O, et al. Quantification of left ventricular remodeling in response to isolated aortic or mitral regurgitation. *J Cardiovasc Magn Reson* 2010;12-32.

32. Ong G, Redfors B, Crowley A, Abdel-Qadir H, Harrington A, Liu Y, et al. Evaluation of left ventricular reverse remodeling in patients with severe aortic regurgitation undergoing aortic valve replacement: comparison between diameters and volumes. *Echocardiography*. 2018;35:142-7.

33. Uretsky S, Argulian E, Supariwala A, Marcoff L, Koulogiannis K, Aldaia L, et al. A comparative assessment of echocardiographic parameters for determining primary mitral regurgitation severity using magnetic resonance imaging as a reference standard. *J Am Soc Echocardiogr*. 2018;31:992-9.
34. Kitai T, Okada Y, Shomura Y, Tani T, Kaji S, Kita T, et al. Timing of valve repair for severe degenerative mitral regurgitation and long-term left ventricular function. *J Thorac Cardiovasc Surg* 2014;148:1978-82.
35. Tribouilloy C, Grigioni F, Avierinos JF, Barbieri A, Rusinaru D, Szymanski C, et al. Survival implication of left ventricular end-systolic diameter in mitral regurgitation due to flail leaflets. *J Am Coll Cardiol* 2009;54:1961-8.
36. Bonow RO, Dodd JT, Maron BJ, O’Gara PT, White GG, McIntosh CL, et al. Long-term serial changes in left ventricular function and reversal of ventricular dilatation after valve replacement for chronic aortic regurgitation. *Circulation* 1988;78:1108-20.
37. Amano M, Izumi C, Imamura S, Onishi N, Tamaki Y, Enomoto S, et al. Late recurrence of left ventricular dysfunction after aortic valve replacement for severe chronic aortic regurgitation. *Int J Cardiol* 2016;224:240.
38. Wang Y, Jiang W, Liu J, Li G, Liu Y, Hu X, et al. Early surgery versus conventional treatment for asymptomatic severe aortic regurgitation with normal ejection fraction and left ventricular dilatation. *Eur J Cardiothorac Surg*. 2017;52:118-24.
39. de Meester C, Gerber BL, Vancraeynest D, Pouleur A-C, Noirhomme P, Pasquet A, et al. Early surgical intervention versus watchful waiting and outcomes for asymptomatic severe aortic regurgitation. *J Thorac Cardiovasc Surg* 2015;150:1100-8.
40. Lee JKT, Franzone A, Lanz J, Siontis GCM, Stortecky S, Gräni C, et al. Early detection of subclinical myocardial damage in chronic aortic regurgitation and strategies for timely treatment of asymptomatic patients. *Circulation* 2018;137:184-96.

Figures

Figure 1. Figure shows typical image analysis performed in this study. A, B: aortic flow analysis on a 71-year-old man. C: corresponding integrated aortic flow output in aortic regurgitation with a regurgitant fraction of 20 %. D: left ventricular contouring for function evaluation in a 30-year-old man.

Figure 2. Study flow chart. CMR = cardiac magnetic resonance. EC = echocardiography

Figure 3. Column bars show regurgitant volumes (derived from cardiac magnetic resonance [CMR] in green - and echocardiography [EC] in blue) in left ventricular (LV)-dysfunction group as assessed by EC and in control group (no LV dysfunction by EC). A: mitral regurgitation. B: aortic regurgitation.

Figure 4. Graphs show correlation between cardiac magnetic resonance (CMR)-derived regurgitant volume and left ventricular (LV) dilatation. A: LV dilatation assessed by CMR in mitral regurgitation. B: LV dilatation assessed by CMR in aortic regurgitation. C: LV dilatation assessed by EC in mitral regurgitation. D: LV dilatation assessed by EC in aortic regurgitation. Correlation coefficient is shown for each couple of measures.

Figure 5. Column bars show comparison between echocardiography (EC) (in blue) and cardiac magnetic resonance (CMR)-derived (in green) regurgitant volumes between patients with LV dysfunction assessed by CMR and patients without LV dysfunction. A: mitral regurgitation. B: aortic regurgitation.

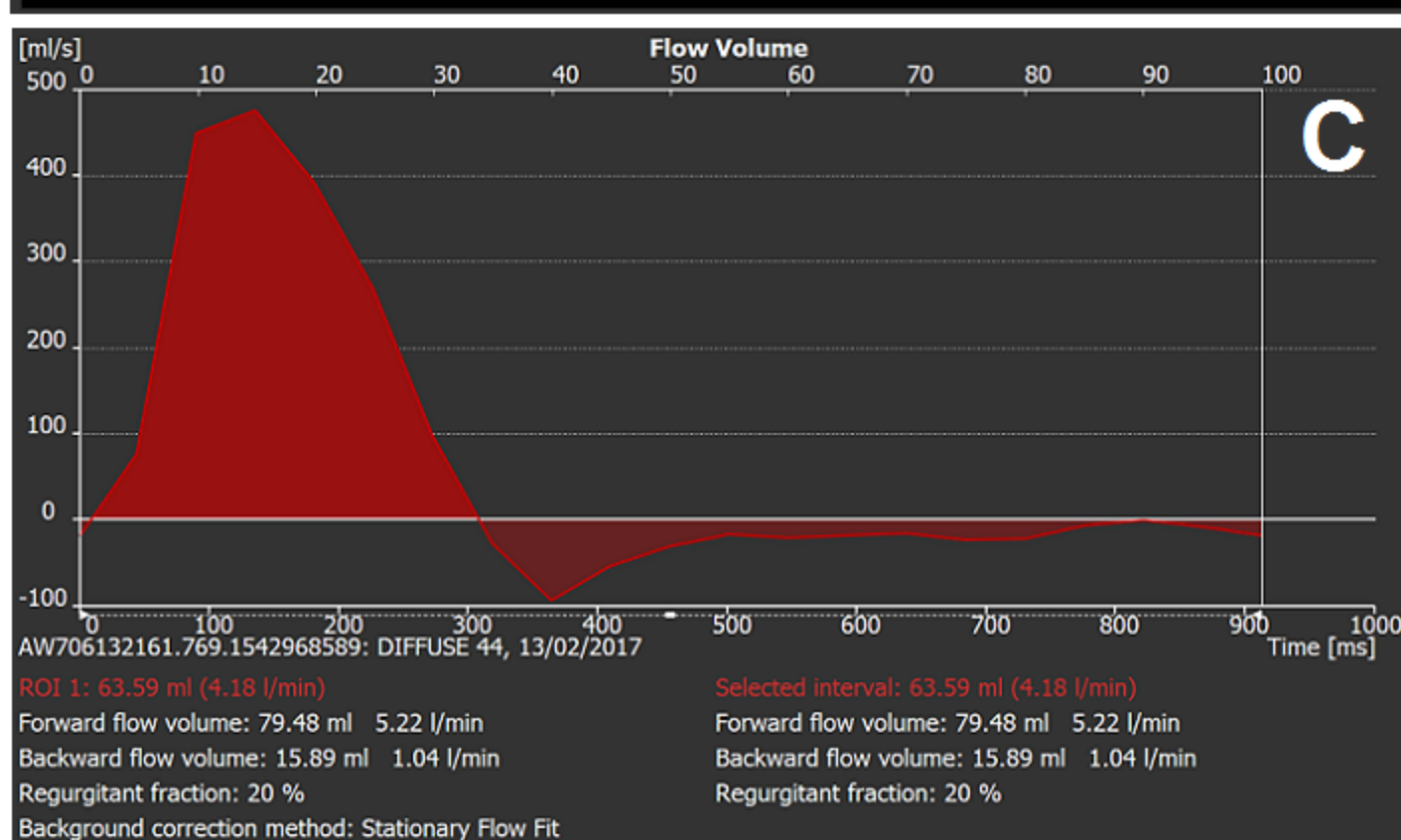
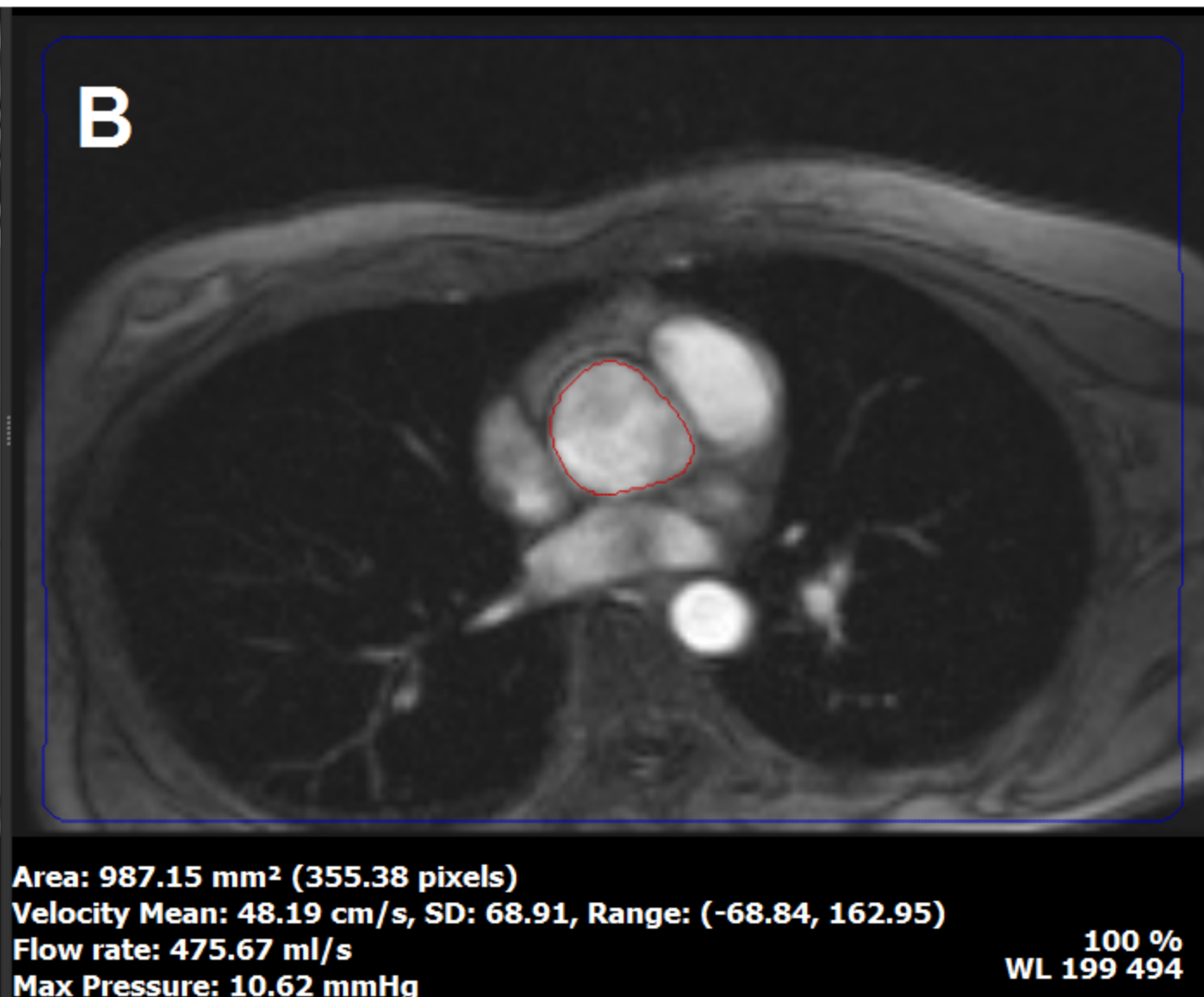
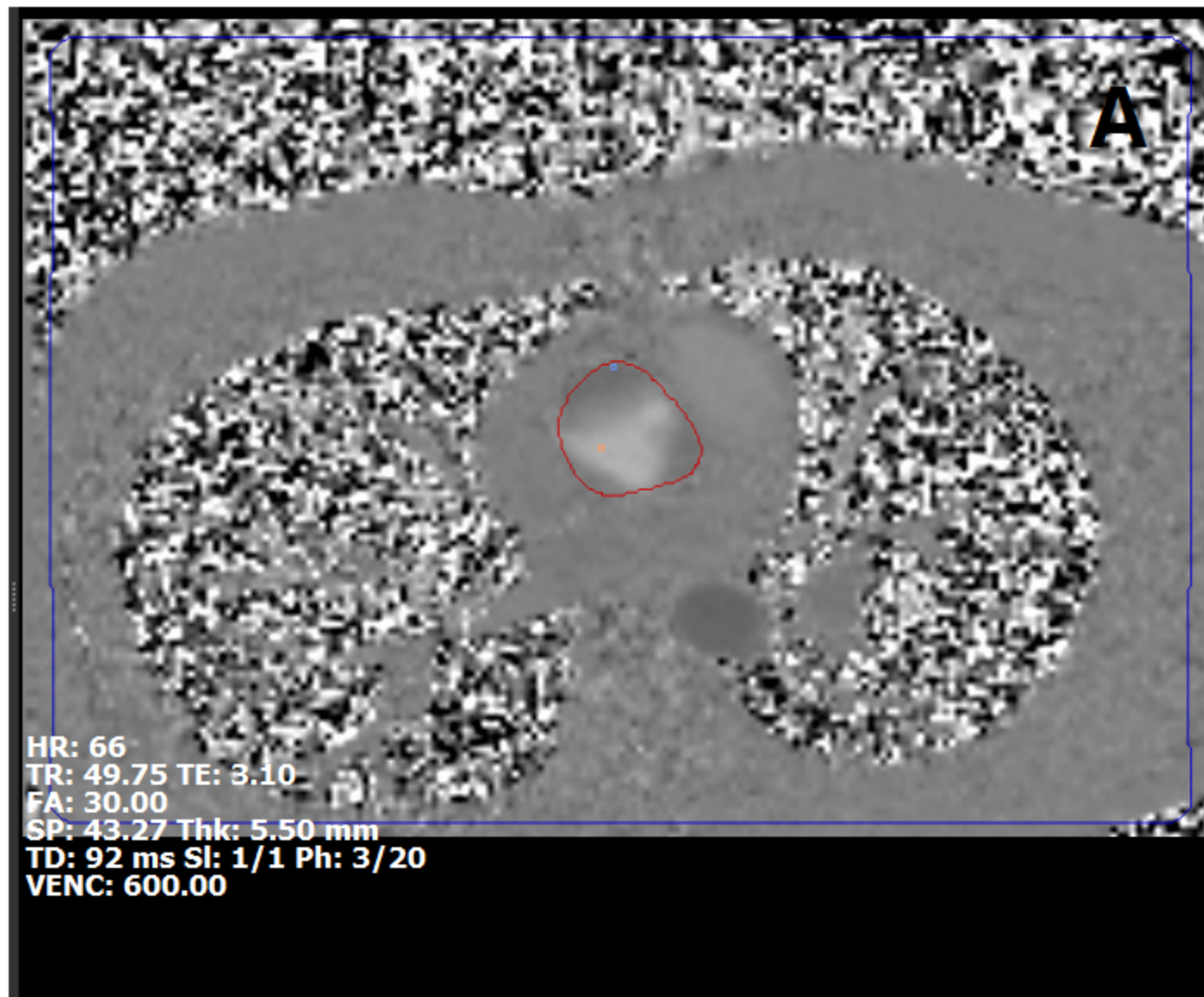
Figure 6. Receiver operating characteristics (ROC) analysis of cardiac magnetic resonance indexed end-diastolic volume (EDV_{CMRi}). A: mitral regurgitation. B: aortic regurgitation. Inserts show ROC analysis for echocardiography parameter for comparison. A: left ventricular end-systolic diameter (LVESD) in mitral regurgitation. B: indexed left ventricular end-systolic diameter (LVESDi) in aortic regurgitation.

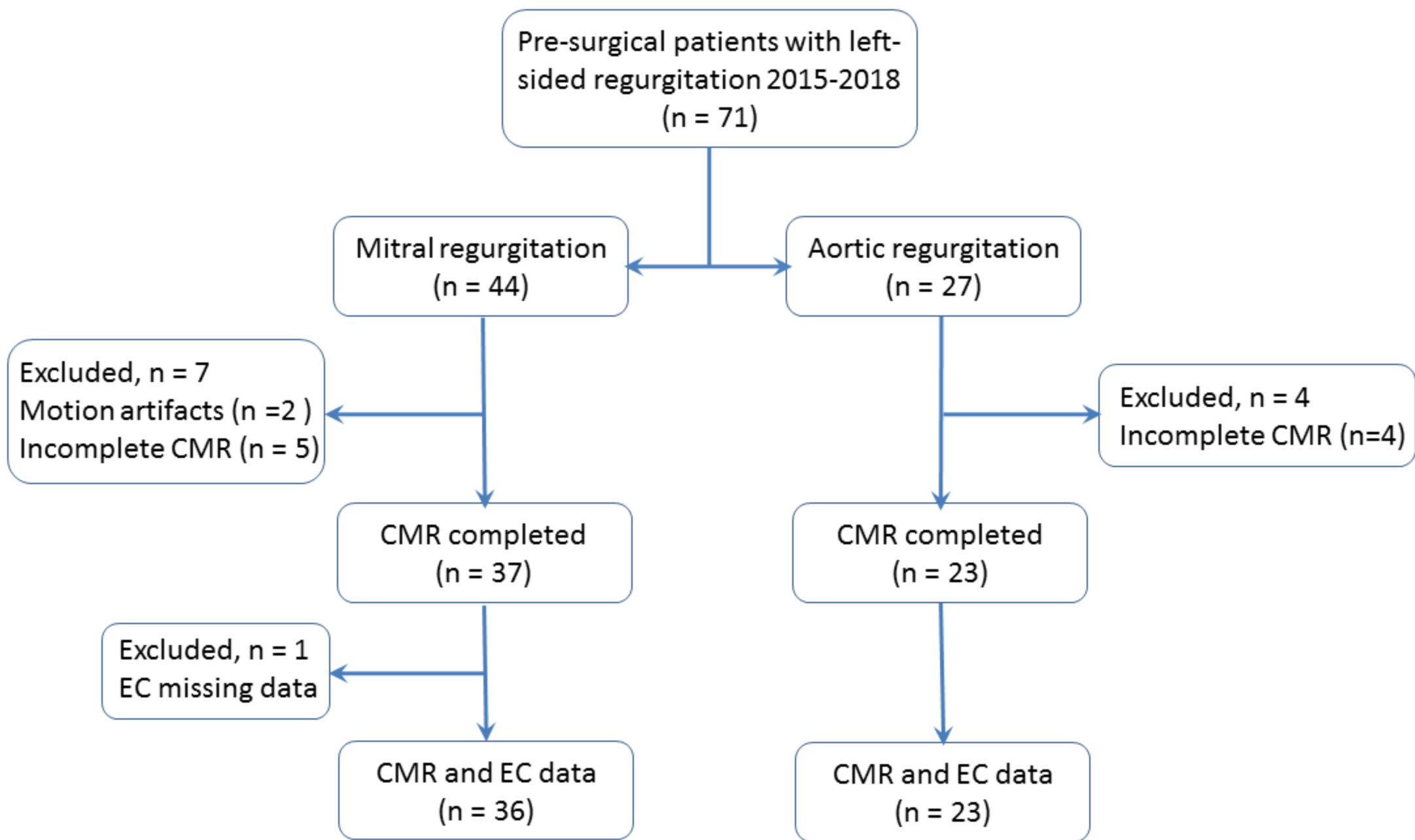
Table 1. Baseline characteristics of the study population.

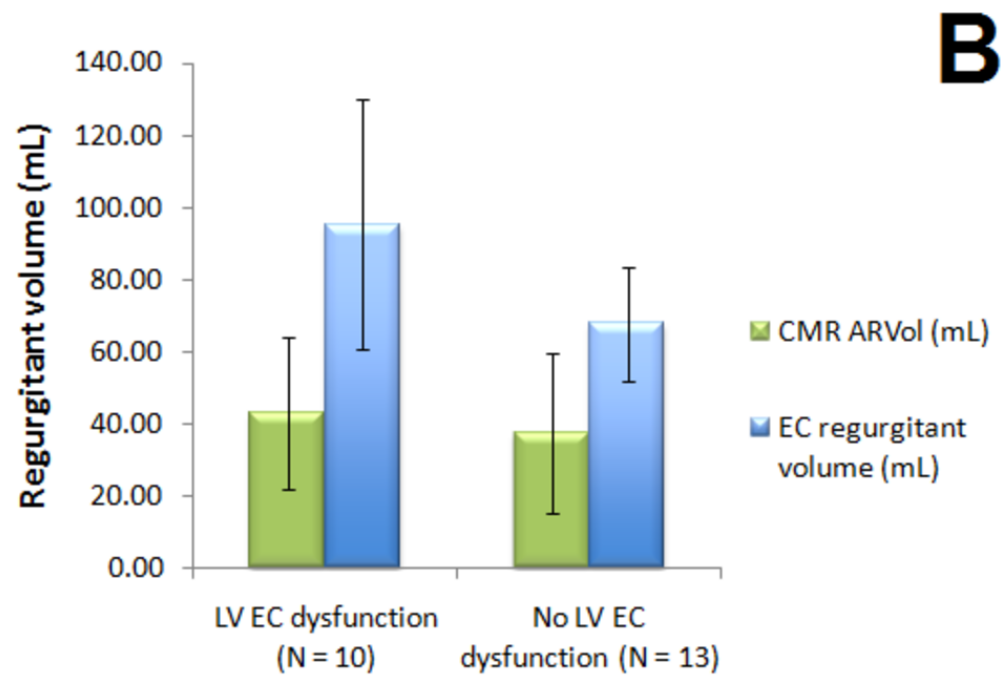
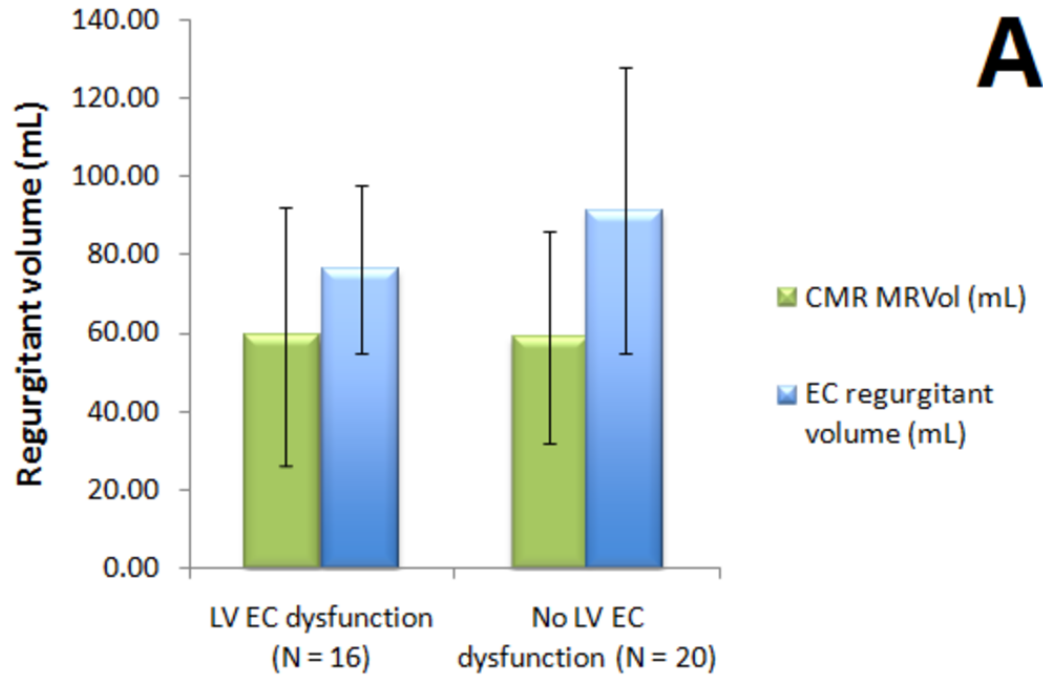
Table 2. Left ventricle dimension parameters of the study population, assessed by echocardiography (EC) and cardiac magnetic resonance (CMR).

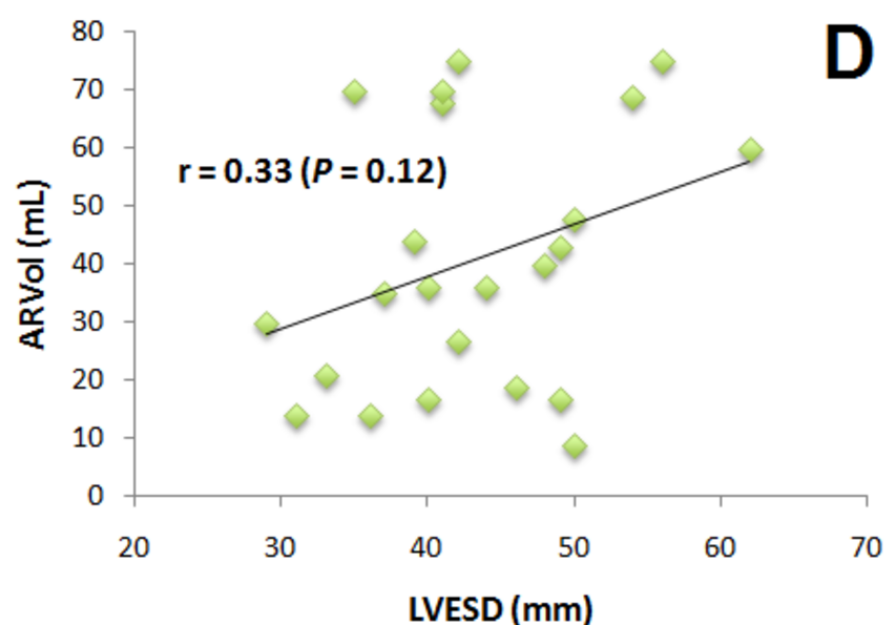
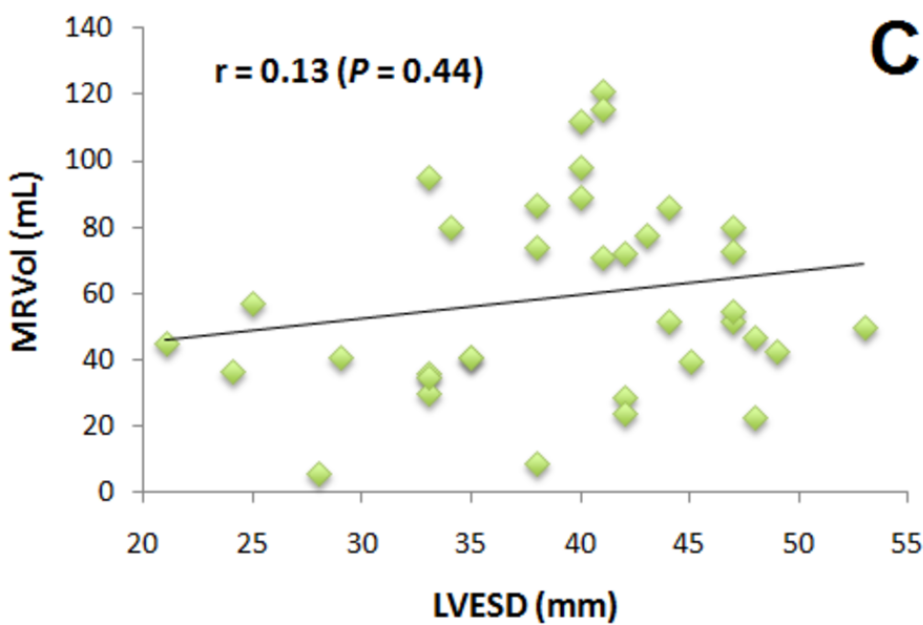
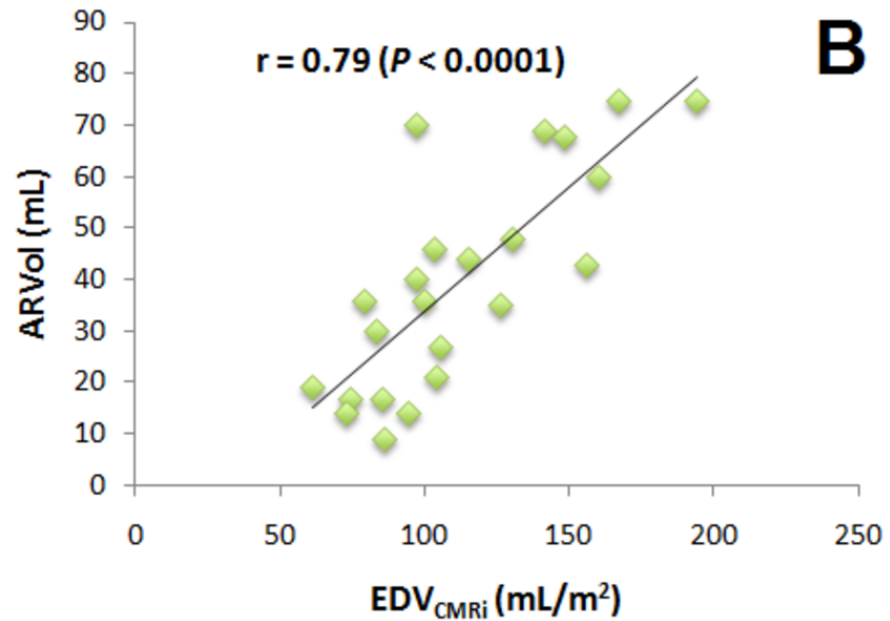
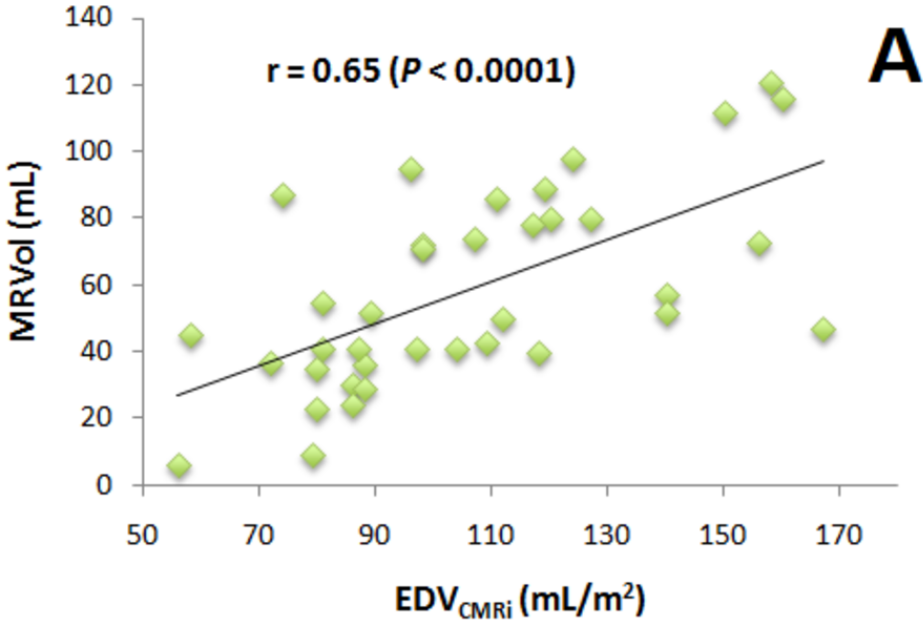
Table 3. Discriminatory ability of dimensional parameters for prediction of mitral regurgitation severity.

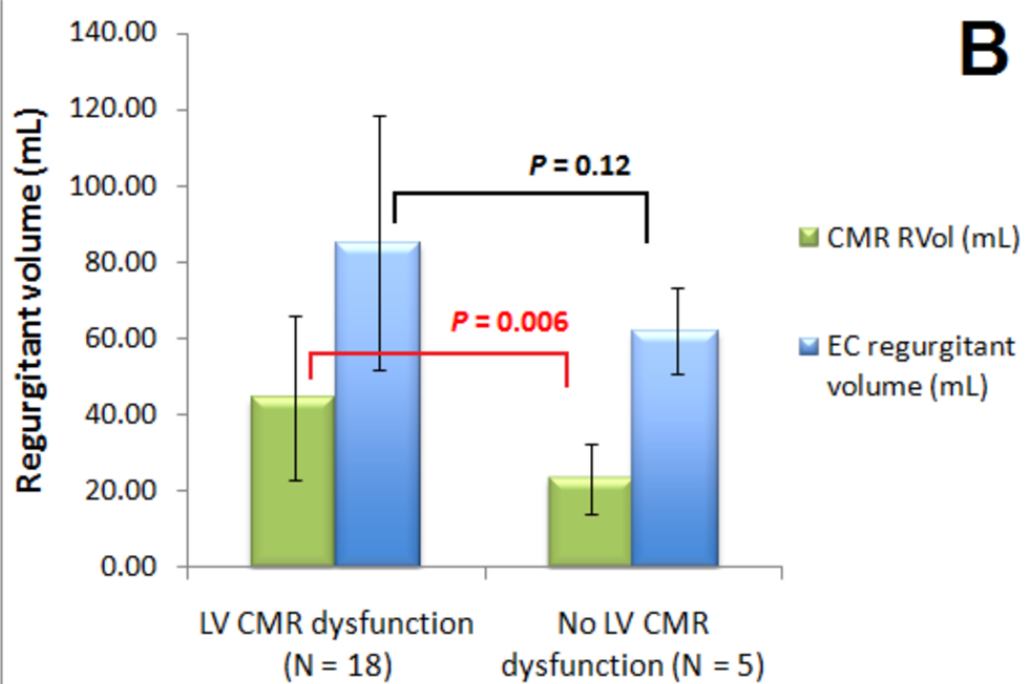
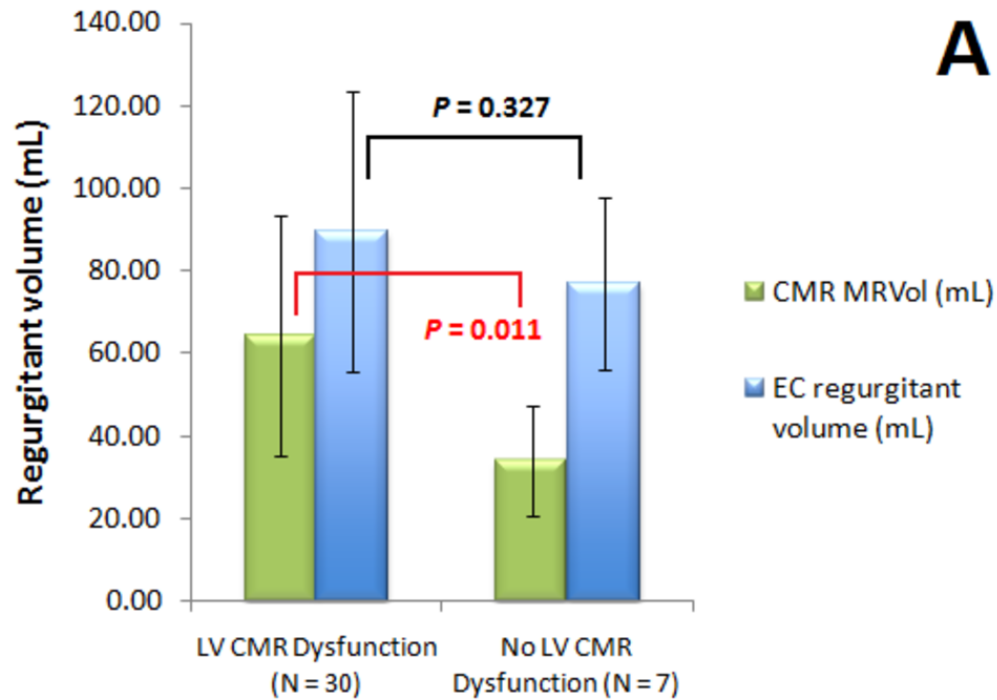
Table 4. Discriminating capabilities of dimensional variables for predicting aortic regurgitation severity.



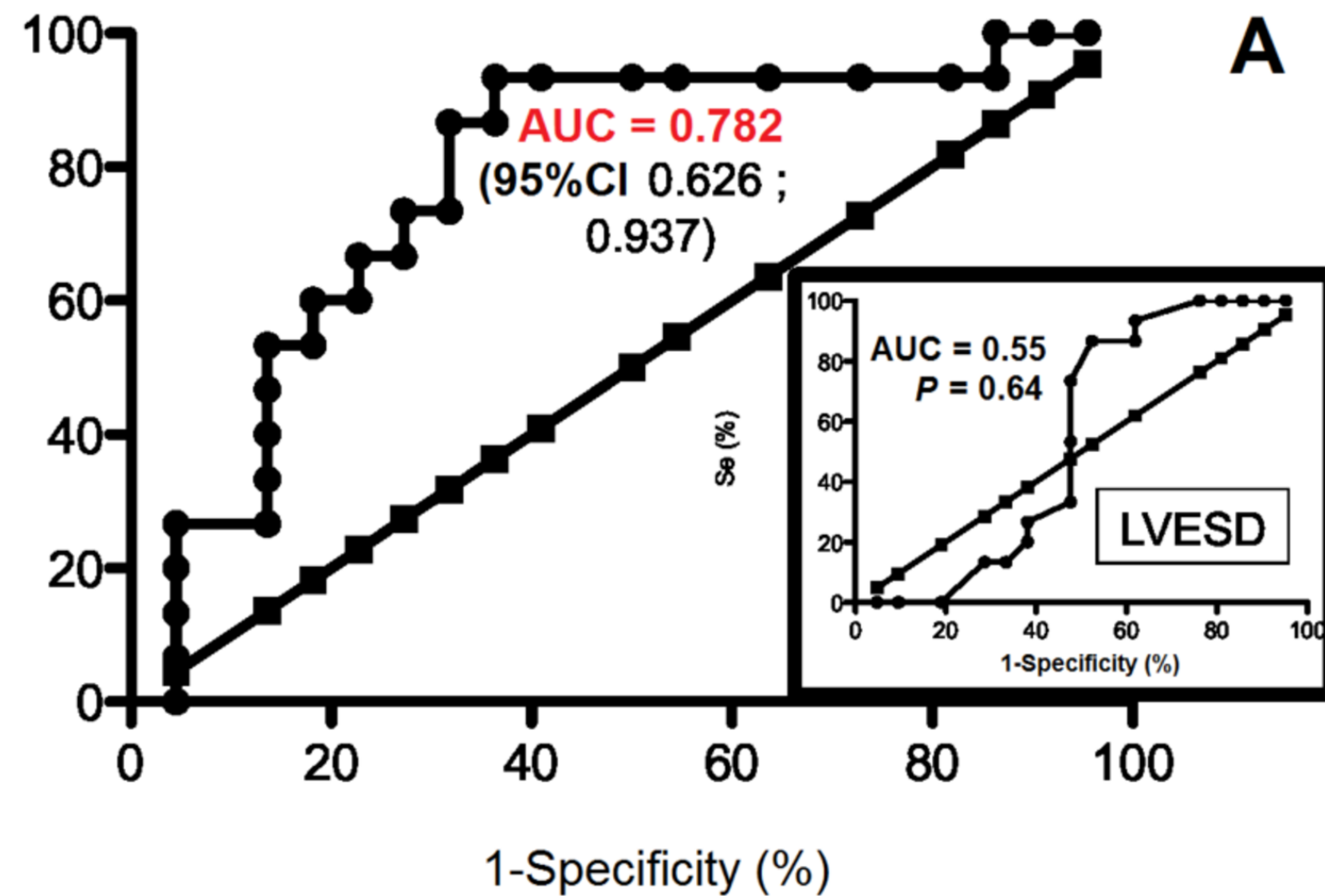




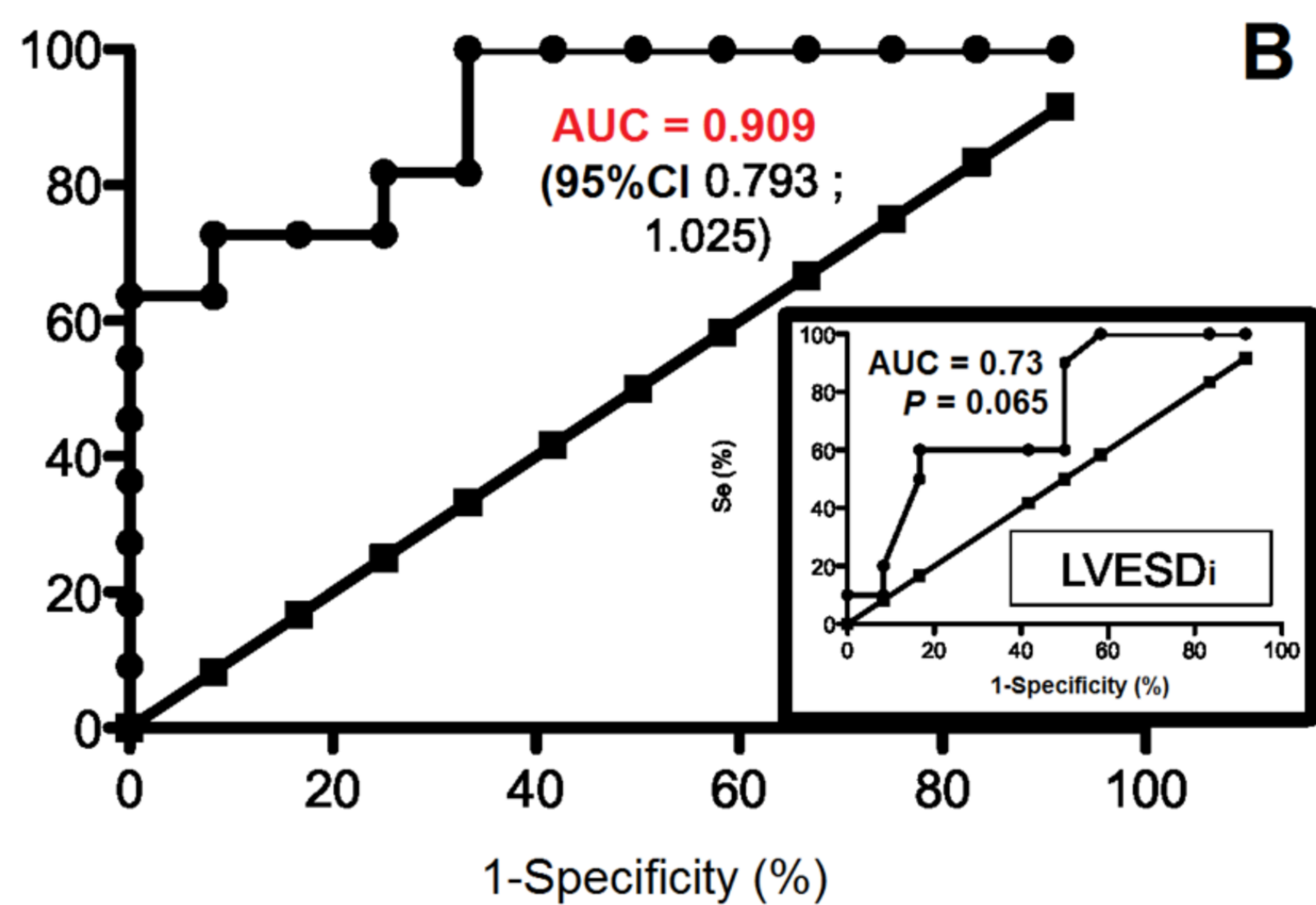




Se (%)



Se (%)



Mitral regurgitation (n = 44)

Age (year)	60 ± 13 [30-83]
Female	11 (11/44; 25%)
Male	33 (33/44; 75%)
Mecanism of MR	
<i>Prolapsus</i>	35 (35/44; 80%)
<i>Restriction</i>	4 (4/44; 9%)
<i>Others</i>	5 (5/44; 11%)
Body surface area (m ²)	1.86 ± 0.20 [1.40-2.53]
Systolic BP (mm Hg)	128 ± 18 [92-178]
Diastolic BP (mm Hg)	75 ± 10 [54-108]
Pulse pressure (mm Hg)	53 ± 15 [28-90]
EC regurgitant volume (mL)	84 ± 30 [30-163]
CMR regurgitant volume (mL)	59 ± 30 [6-121]

Aortic regurgitation (n = 27)

Age (year)	62 ± 15 [18-81]
Female	6 (6/27; 22%)
Male	21 (21/27; 78%)
Mecanism of AR	
<i>Restriction</i>	8 (8/27; 30%)
<i>Prolapsus</i>	3 (3/27; 11%)
<i>Perforation</i>	1 (1/27; 4%)
<i>Sinotubular ectasis</i>	1 (1/27; 4%)
<i>Combined/others</i>	14 (14/27; 52%)
Body surface area (m ²)	1.89 ± 0.21 [1.36-2.3]
Systolic BP (mm Hg)	132 ± 17 [108-170]
Diastolic BP (mm Hg)	69 ± 10 [50-82]
Pulse pressure (mm Hg)	63 ± 15 [45-108]
EC regurgitant volume (mL)	81 ± 31 [41-150]
CMR regurgitant volume (mL)	41 ± 22 [9-75]

Quantitative variables are expressed as means, SD; numbers in brackets are ranges. Qualitative variables

are expressed as raw numbers; numbers in parentheses are proportions followed by percentages.
BP = blood pressure. EC = echocardiography. CMR = cardiac magnetic resonance.

Mitral regurgitation (n = 44)

LVESD (mm)	39 ± 7 [21-53]
EDV _{ECi} (mL/m ²)	90 ± 24 [47-136]
ESV _{ECi} (mL/m ²)	30 ± 10 [10-52]
EDV _{CMRi} (mL/m ²)	108 ± 28 [56-167]
ESV _{CMRi} (mL/m ²)	45 ± 15 [22-87]

Aortic regurgitation (n = 27)

LVESD (mm)	43 ± 8 [29-62]
LVESDi (mm/m ²)	23 ± 4 [16-32]
EDV _{ECi} (mL/m ²)	101 ± 22 [64-170]
ESV _{ECi} (mL/m ²)	43 ± 19 [18-102]
EDV _{CMRi} (mL/m ²)	114 ± 35 [61-194]
ESV _{CMRi} (mL/m ²)	49 ± 21 [15-93]

Data are expressed as mean standard deviation; numbers in brackets are ranges.

LVESD = left ventricular end-systolic diameter; EDV_{ECi} = indexed end-diastolic volume from echocardiography; ESV_{ECi} = indexed end-systolic volume from echocardiography; EDV_{CMRi} = indexed end-diastolic volume from cardiac magnetic resonance; ESV_{CMRi} = indexed end-systolic volume from cardiac magnetic resonance; LVESDi = indexed left ventricular end-systolic diameter.

Measure	AUC (95% CI)	<i>P</i> value	Threshold
LVEDD (mm)	0.55 (0.35-0.74)	0.640	> 37
EDV _{ECi} (mL/m ²)	0.71 (0.53-0.88)	0.036	> 92
ESV _{ECi} (mL/m ²)	0.63 (0.44-0.82)	0.200	> 30
EDV _{CMRi} (mL/m ²)	0.78 (0.63-0.94)	0.004	> 92
ESV _{CMRi} (mL/m ²)	0.72 (0.55-0.90)	0.023	> 37

AUC = area under curve; CI = Confidence Interval; LVEDD = left ventricular end-systolic diameter; EDV_{ECi} = indexed end-diastolic volume from echocardiography; ESV_{ECi} = indexed end-systolic volume from echocardiography; EDV_{CMRi} = indexed end-diastolic volume from cardiac magnetic resonance; ESV_{CMRi} = indexed end-systolic volume from cardiac magnetic resonance.

Measure	AUC (95% CI)	<i>P</i> value	Threshold
LVEDD (mm)	0.74 (0.54-0.94)	0.053	>40
LVEDDi (mm/m ²)	0.73 (0.52-0.95)	0.065	>19
EDV _{ECi} (mL/m ²)	0.86 (0.69-1.02)	0.006	>99
ESV _{ECi} (mL/m ²)	0.84 (0.67-1.01)	0.008	>38
EDV _{CMRi} (mL/m ²)	0.91 (0.79-1.02)	0.0009	>95
ESV _{CMRi} (mL/m ²)	0.89 (0.75-1.02)	0.0017	> 52

AUC = area under curve; CI = confidence interval; LVEDD = left ventricular end-systolic diameter; LVEDDi = indexed left ventricular end-systolic diameter; EDV_{ECi} = indexed end-diastolic volume from echocardiography; ESV_{ECi} = indexed end-systolic volume from echocardiography; EDV_{CMRi} = indexed end-diastolic volume from cardiac magnetic resonance; ESV_{CMRi} = indexed end-systolic volume from cardiac magnetic resonance.