



**HAL**  
open science

## **An infected arterial aneurysm and a dog bite: think at capnocytophaga canimorsus!**

Mailys Ducours, Julie Leitao, Mathilde Puges, Sabine Pereyre, Frédéric Gabriel, Hervé Dutronc, Raphaëlle Chevallier, Jean-Baptiste Pinaquy, Claire Carcaud, Xavier Berard, et al.

### ► To cite this version:

Mailys Ducours, Julie Leitao, Mathilde Puges, Sabine Pereyre, Frédéric Gabriel, et al.. An infected arterial aneurysm and a dog bite: think at capnocytophaga canimorsus!. *Infection and Drug Resistance*, 2021, 14, pp.2397-2401. 10.2147/IDR.S281040 . hal-03293645

**HAL Id: hal-03293645**

**<https://hal.inrae.fr/hal-03293645>**

Submitted on 21 Jul 2021

**HAL** is a multi-disciplinary open access archive for the deposit and dissemination of scientific research documents, whether they are published or not. The documents may come from teaching and research institutions in France or abroad, or from public or private research centers.

L'archive ouverte pluridisciplinaire **HAL**, est destinée au dépôt et à la diffusion de documents scientifiques de niveau recherche, publiés ou non, émanant des établissements d'enseignement et de recherche français ou étrangers, des laboratoires publics ou privés.



Distributed under a Creative Commons Attribution - NonCommercial 4.0 International License

# An Infected Arterial Aneurysm and a Dog Bite: Think at *Capnocytophaga canimorsus*!

Maïlys Ducours <sup>1</sup>  
 Julie Leitao<sup>1</sup>  
 Mathilde Puges<sup>1</sup>  
 Sabine Pereyre <sup>2,3</sup>  
 Frédéric Gabriel <sup>4</sup>  
 Hervé Dutronc<sup>1</sup>  
 Raphaëlle Chevallier<sup>1</sup>  
 Jean-Baptiste Pinaquy <sup>5</sup>  
 Claire Carcaud<sup>6</sup>  
 Xavier Berard<sup>7</sup>  
 Charles Cazanave<sup>1,3</sup>

<sup>1</sup>CHU Bordeaux, Service des Maladies Infectieuses et Tropicales, Hôpital Pellegrin, Bordeaux, F-33000, France; <sup>2</sup>CHU Bordeaux, Laboratoire de Bactériologie, Hôpital Pellegrin, Bordeaux, F-33000, France; <sup>3</sup>University of Bordeaux, INRAE, IHMC, USC EA 3671, Bordeaux, F-33000, France; <sup>4</sup>Centre Hospitalier Universitaire de Bordeaux, Laboratoire de parasitologie-mycologie, Hôpital Pellegrin, Bordeaux, F-33000, France; <sup>5</sup>CHU Bordeaux, Service de médecine nucléaire, Bordeaux, F-33000, France; <sup>6</sup>CHU Bordeaux, Service de médecine vasculaire, Bordeaux, F-33000, France; <sup>7</sup>CHU Bordeaux, Service de chirurgie vasculaire, Bordeaux, F-33000, France

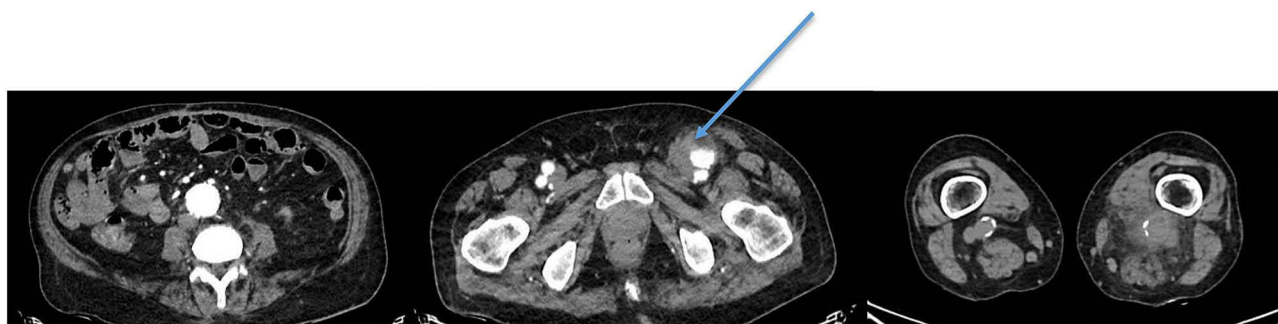
Correspondence: Charles Cazanave  
 CHU Bordeaux, Service des Maladies Infectieuses et Tropicales, Groupe Hospitalier Pellegrin, Place Amélie Raba-Léon, Bordeaux Cedex, 33076, France  
 Email charles.cazanave@chu-bordeaux.fr

**Abstract:** We describe the fourth cases of arterial aneurysm consecutive to *Capnocytophaga canimorsus* infection in a 77-year-old man. The infection occurred after a dog bite. He presented fever. The thoracic-abdominal computed tomography angiography revealed aneurysms on the abdominal aorta, left common femoral artery, and left popliteal artery. The diagnosis was performed by a blood culture positive for *Capnocytophaga canimorsus*. The outcome was favorable with surgery and antibiotic therapy.

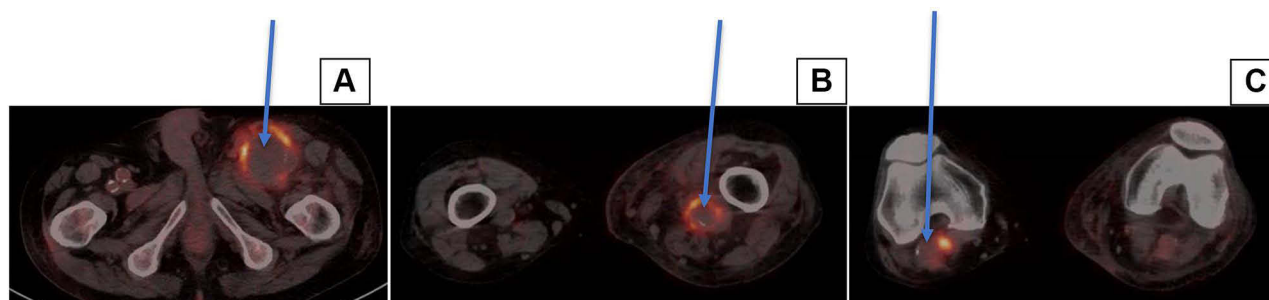
**Keywords:** *Capnocytophaga canimorsus*, vascular aneurysm, dog bite, cat bite, zoonosis

## Case Report

A 77-year-old man presented with a 1-week history of asthenia, dyspnoea, and confusion after a dog bite on the left hand 10 days previously. He had a history of ischaemic stroke, dyslipidaemia, essential thrombocythaemia, and hypertension. He also reported histories of heavy alcohol consumption and 30 pack-year smoking. At admission, his temperature and heart and respiratory rates were 37.5°C, 100/min, and 20/min, respectively. Physical examination revealed oedema of the left leg. Blood tests showed haemoglobin 11g/dL, total leucocyte count 37,400/mm<sup>3</sup>, with 33,660/mm<sup>3</sup> neutrophils, platelet count 734,000/mm<sup>3</sup>, C-reactive protein 320 mg/L, and serum creatinine 178 µmol/L. Thoracic-abdominal computed tomography angiography revealed aneurysms on the abdominal aorta (38 mm diameter), left common femoral artery (43 mm diameter), and left popliteal artery (33 mm diameter) (Figure 1). Six days later, 18F-fluorodeoxyglucose positron emission tomography-CT confirmed three growing inflammatory aneurysms, on the left common femoral (diameter 64×72 mm, Standardised Uptake Value (SUV) 12) and left (diameter 43×29 mm, SUV 10) and right (diameter 35×28 mm, SUV 10) popliteal arteries (Figure 2); the abdominal aorta was normal. Cerebral magnetic resonance imaging and transthoracic and transoesophageal echocardiography were normal. While hospitalized, his left leg was very painful and increased in volume. Ultrasonography Doppler revealed thrombosis of the deep common and superficial femoral veins. The left common femoral and popliteal aneurysms were resected and replaced using the right saphenous vein. After 11 days, cultures of the femoral aneurysm were positive for *Capnocytophaga canimorsus*. Identification was performed using matrix-assisted laser desorption/ionization time-of-flight mass spectrometry (MALDI-TOF MS) on three different isolates. The MALDI-TOF MS score identification was 2, 29. The strain was susceptible in vitro to beta-lactams, aminoglycosides, fluoroquinolones, tetracycline, and trimethoprim-sulfamethoxazole, and resistant to macrolides. A post-surgery blood culture was



**Figure 1** Axial section on computed tomography images. Arrow shows left common femoral artery aneurysm.



**Figure 2** Axial section on PET-CT with FDG. Arrows show aneurysms. (A) Aneurysm on the left common femoral artery (SUV: 12), (B) Aneurysm on the left popliteal artery (SUV: 10), (C) Aneurysm on the right popliteal artery (SUV: 10).

**Abbreviation:** SUV, Standardized Uptake Value.

positive for *Escherichia coli*, probably due to a superinfection of aneurysms; identification was performed using MALDI-TOF MS; the bacteria has no acquired antibiotic resistance. The patient received piperacillin–tazobactam 12 g/day, and then amoxicillin/clavulanic acid 6 g/day for 1 month, which allowed to treat the two bacteria. No aetiology other than bacterial infection was found to explain the rapid expansion of this aneurysm. The symptoms and the incubation period was not in favor for a rabies. Other aetiology of infected aneurysms was eliminated by blood culture and serological test. Temporal artery biopsy was not in favor for a Horton disease. Serological tests performed for autoimmune disease were negative. As his brother also has a history of arterial aneurysms, genetic research for a familial form of aneurysm is planned. The outcome was favourable.

## Discussion

Belonging to the family *Flavobacteriaceae*, the genus *Capnocytophaga* consists of nine species: *C. canimorsus*, *C. cynodegmi*, *C. gingivalis*, *C. granulosa*, *C. haemolytica*, *C. leadbetteri*, *C. ochracea*, *C. sputigena* and *C. canis*.<sup>1–3</sup>

*C. canimorsus* was first isolated from a man who developed septicaemia and meningitis following dog bites. It was first named dysgonic fermenter 2<sup>4</sup> and given its current name in 1989 from the Greek kapnos (“smoke”) for its dependence on carbon dioxide, cytophaga (Greek kytos “cell” and phagein “eat”), and the Latin canis (“dog”) and morsus (“bite”). Three *C. canimorsus* serovars (A-C) cause most human infections.<sup>5</sup> Hess et al first reported who determine the *C. canimorsus* serovar by PCR;<sup>6</sup> this test is not performed routinely in our laboratory, and should not be performed for our patient. It is a commensal bacterium of the oral cavities of dogs and cats. A Japanese study found it in 74% and 57% of the oral cavities of dogs and cats, respectively.<sup>7</sup> It is a slow-growing, facultatively anaerobic, Gram-negative bacillus. *Capnocytophaga* spp. are fastidious bacteria; their optimal growth conditions include the use of specific culture media (agar chocolate or brain heart infusion), and an environment with 5–10% CO<sub>2</sub>, temperature of 37°C, and enriched atmosphere for at least 5 days.<sup>8</sup> Transmission can occur through dogs’ and cats’ scratches, bites, or licking pre-existing wounds; however, the sources of infection remain unknown in about 10% of described cases. Pet owners and

people who have occupational associations with animals are at high risk of exposure to *C. canimorsus*.<sup>9</sup> The incubation period before the onset of symptoms ranges from 1 to 7 days. Systemic infections occur most frequently in immunocompromised patients, such as asplenic, neutropenic, or alcoholic patients, patients with haematological malignancies or receiving chemotherapy, immunosuppressive therapy or long-term steroids, patients infected by the Human Immunodeficiency Virus, elderly patients, and patients with hemochromatosis or major beta-thalassemia.<sup>9–12</sup> Reported clinical manifestations include bacteraemia, endocarditis, joint infections, peritonitis, meningitis, vascular infection, disseminated intravascular coagulation, and thrombotic thrombocytopenic purpura.<sup>8–20</sup> Most patients have bacteraemia.<sup>16</sup> *C. canimorsus* is often difficult to isolate and identify because of its specific nutrient requirements, so the frequency of *C. canimorsus* infection might be underestimated.<sup>15</sup> Polymerase chain reaction (PCR) and sequencing of the 16S ribosomal RNA (rRNA) is sometimes useful for identifying *C. canimorsus*.<sup>21</sup> The diagnosis should be made in cases of endocarditis or joint infections with negative cultures and contact with an animal.<sup>8,13</sup> The slow growth of this organism may also result in difficulty performing antimicrobial susceptibility

testing. *C. canimorsus* is usually susceptible to clindamycin, linezolid, tetracycline, imipenem, beta-lactamase inhibitor combination, and quinolones. It is always resistant to polymyxin, fusidic acid, fosfomycin, colimycin, and trimethoprim. It frequently produces a beta-lactamase, but susceptibility is restored by beta-lactamase inhibitors.<sup>14,22,23</sup> Prevention of infection is mandatory after dog and cat bites by antibiotic prophylaxis with amoxicillin/clavulanic acid. Established infections should be treated with a penicillin-beta-lactamase inhibitor combination or a third-generation cephalosporin before obtaining antibiotic susceptibility.<sup>22,23</sup> The duration of antibiotic therapy depends on the type of infection. In the case of septicemia, the mortality is about 30%.<sup>16</sup>

The three reported cases of aortic aneurysm caused by *C. canimorsus* are summarised in Table 1.<sup>10,11,24</sup> Two patients had cardiovascular risk factors and two also reported wounds contaminated with dog or cat saliva. All three needed emergency surgery because of impending rupture with worsening condition. The final diagnosis was made by culture in two patients [of the aortic wall<sup>10</sup> and blood<sup>11</sup>] and 16S rRNA gene sequencing definitively identified *C. canimorsus*.<sup>10,11</sup> In the third case, cultures were negative, but 16S rRNA sequencing from aortic tissue identified *C. canimorsus*.<sup>24</sup> In our case,

**Table 1** Patients Reported with Aortic Aneurysms Caused by *C. canimorsus*

| Publication                   | Age, Years | Gender | Risk Factors                                       | Wound                 | Clinical Features      | Diagnosis  | Treatment  | Outcome   |
|-------------------------------|------------|--------|--|-----------------------|------------------------|--|--|-----------|
| Tierney et al <sup>10</sup>   | 65         | M      | Cardiovascular risk factors                        | Dog bite on right arm | Fever, lower back pain | Positive culture on aortic wall, and 16S rRNA gene sequencing                      | - Piperacillin-tazobactam, then imipenem, then amoxicillin-clavulanate, and finally with ciprofloxacin for at least 6 weeks<br>-Emergency surgery because of the impending rupture worsening condition | Favorable |
| Rougemont et al <sup>11</sup> | 49         | F      | HIV-infected patient with an aortic vascular graft | No                    | Fever, lower back pain | Positive blood cultures and 16S rRNA gene sequencing                               | - Piperacillin-tazobactam<br>- Emergency surgery because of the impending rupture worsening condition  | Death     |
| Chu et al <sup>24</sup>       | 69         | H      | Cardiovascular risk factors                        | Dog bite on hand      | Fever, lower back pain | 16S rRNA gene sequencing from the aortic tissue (negative bacteriological culture) | - Intravenous meropenem during 4 weeks, then ciprofloxacin for 6 months<br>- Emergency surgery because of the impending rupture worsening condition  | Favorable |

**Abbreviations:** F, female; M, male; 16S rRNA, 16 S ribosomal ribonucleic acid.

identification was performed using MALDI-TOF MS, with an identification score of  $\geq 2.0$ , which is considered an accurate species-level identification. This explains why we did not realise 16s rRNA gene sequencing. One patient was treated with piperacillin/tazobactam, then imipenem, then amoxicillin/clavulanate and, finally, with ciprofloxacin for at least 6 weeks,<sup>10</sup> another with piperacillin/tazobactam,<sup>12</sup> and the third with intravenous meropenem for 4 weeks, and then ciprofloxacin for 6 months. Ultimately, one patient died of haemorrhagic shock and ventilator-associated pneumonia.

In conclusion, we reported the fourth case of a rapidly growing arterial aneurysm caused by *C. canimorsus* infection after a dog bite. Since *C. canimorsus* is a fastidious bacterium, infection is often difficult to diagnose; contact with pets (dogs and cats) should be considered. Antibiotic therapy is mandatory, often associated with surgery, illustrating a multidisciplinary management.

## Consent Statements

A written informed consent has been provided by the patient to have the case details and any accompanying images published. This work is consistent with the protection of personal health data and privacy under article 65-2, the amended Computer and Freedoms Act and the General Regulation of Personal Data Protection. Institutional approval was not required to publish the case details.

## Acknowledgments

Dr ISSA Nahema and Dr CAMOU Fabrice, Réanimation médicale, Hôpital Saint André, CHU de Bordeaux.

## Disclosure

The authors report no conflicts of interest in this work.

## References

- Renzi F, Dol M, Raymackers A, Manfredi P, Cornelis GR. Only a subset of *Capnocytophaga canimorsus* strains is dangerous for humans. *Emerg Microbes Infect.* 2016;5:1. doi:10.1038/emi.2016.43
- Donner V, Buzzi M, Lazarevic V, et al. Septic shock caused by *Capnocytophaga canis* after a cat scratch. *Eur J Clin Microbiol Infect Dis.* 2020;39(10):1993–1995. doi:10.1007/s10096-020-03922-8
- Taki M, Shimojima Y, Nogami A, et al. Sepsis caused by newly identified *Capnocytophaga canis* following cat bites: *C. canis* is the third candidate along with *C. canimorsus* and *C. cynodegmi* causing zoonotic infection. *Intern Med.* 2018;57(2):273–277. doi:10.2169/internalmedicine.9196-17
- Bobo RA, Newton EJ. A previously undescribed gram-negative bacillus causing septicemia and meningitis. *Am J Clin Pathol.* 1976;65(4):564–569. doi:10.1093/ajcp/65.4.564
- Hess E, Renzi F, Karhunen P, et al. *Capnocytophaga canimorsus* capsular serovar and disease severity, Helsinki Hospital District, Finland, 2000–2017. *Emerg Infect Dis.* 2018;24(12):2195–2201. doi:10.3201/eid2412.172060
- Hess E, Renzi F, Koudad D, Dol M, Cornelis GR, Patel R. Identification of virulent *Capnocytophaga canimorsus* isolates by capsular typing. *J Clin Microbiol.* 2017;55(6):1902–1914. doi:10.1128/JCM.00249-17
- Suzuki M, Kimura M, Imaoka K, Yamada A. Prevalence of *Capnocytophaga canimorsus* and *Capnocytophaga cynodegmi* in dogs and cats determined by using a newly established species-specific PCR. *Vet Microbiol.* 2010;144(1–2):172–176. doi:10.1016/j.vetmic.2010.01.001
- Coutance G, Labombarda F, Pellissier A, et al. *Capnocytophaga canimorsus* endocarditis with root abscess in a patient with a bicuspid aortic valve. *Heart Int.* 2009;4(1):e5. doi:10.4081/hi.2009.e5
- Gastra W, Lipman LJA. *Capnocytophaga canimorsus*. *Vet Microbiol.* 2010;140(3–4):339–346. doi:10.1016/j.vetmic.2009.01.040
- Tierney DM, Strauss LP, Sanchez JL. *Capnocytophaga canimorsus* mycotic abdominal aortic aneurysm: why the mailman is afraid of dogs. *J Clin Microbiol.* 2006;44(2):649–651. doi:10.1128/JCM.44.2.649-651.2006
- Rougemont M, Ratib O, Wintch J, Schrenzel J, Hirschel B. *Capnocytophaga canimorsus* prosthetic aortitis in an HIV-positive woman. *J Clin Microbiol.* 2013;51(8):2769–2771. doi:10.1128/JCM.00321-13
- Wilson JP, Kafetz K, Fink D. Lick of death: *Capnocytophaga canimorsus* is an important cause of sepsis in the elderly. *BMJ Case Rep.* 2016;2016:2016. doi:10.1136/bcr-2016-215450
- Kelly BC, Constantinescu DS, Foster W. *Capnocytophaga canimorsus* periprosthetic joint infection in an immunocompetent patient: a case report. *Geriatr Orthop Surg Rehabil.* 2019;10:2151459318825199. doi:10.1177/2151459318825199
- Jolivet-Gougeon A, Sixou J-L, Tamanaï-Shacoori Z, Bonneure-Mallet M. Antimicrobial treatment of *Capnocytophaga* infections. *Int J Antimicrob Agents.* 2007;29(4):367–373. doi:10.1016/j.ijantimicag.2006.10.005
- Janda JM, Graves MH, Lindquist D, Probert WS. Diagnosing *Capnocytophaga canimorsus* infections. *Emerg Infect Dis.* 2006;12(2):340–342. doi:10.3201/eid1202.050783
- Lion C, Escande F, Burdin JC. *Capnocytophaga canimorsus* infections in human: review of the literature and cases report. *Eur J Epidemiol.* 1996;12(5):521–533. doi:10.1007/BF00144007
- Mosher CB, Corp R. Mediastinal abscess with *Capnocytophaga* spp. in a competent host. *J Clin Microbiol.* 1986;24(1):161–162. doi:10.1128/jcm.24.1.161-162.1986
- Hartley JW, Martin ED, Gothard WP, Levine DF. Fulminant *Capnocytophaga canimorsus* (DF2) septicaemia and diffuse intravascular coagulation in hairy cell leukaemia with splenectomy. *J Infect.* 1994;29(2):229–230. doi:10.1016/S0163-4453(94)90890-7
- Tani N, Nakamura K, Sumida K, Suzuki M, Imaoka K, Shimono N. An immunocompetent case of *Capnocytophaga canimorsus* infection complicated by secondary thrombotic microangiopathy and disseminated intravascular coagulation. *Intern Med.* 2019;58(23):3479–3482. doi:10.2169/internalmedicine.3110-19
- Ma A, Goetz MB. *Capnocytophaga canimorsus* sepsis with associated thrombotic thrombocytopenic purpura. *Am J Med Sci.* 2013;345(1):78–80. doi:10.1097/MAJ.0b013e318262db1a
- Hansen M, Crum-Cianflone NF. *Capnocytophaga canimorsus* meningitis: diagnosis using polymerase chain reaction testing and systematic review of the literature. *Infect Dis Ther.* 2019;8(1):119–136. doi:10.1007/s40121-019-0233-6
- Jolivet-Gougeon A, Buffet A, Dupuy C, et al. In vitro susceptibilities of *Capnocytophaga* isolates to beta-lactam antibiotics and beta-lactamase inhibitors. *Antimicrob Agents Chemother.* 2000;44(11):3186–3188. doi:10.1128/AAC.44.11.3186-3188.2000

23. Roscoe DL, Zemcov SJ, Thornber D, Wise R, Clarke AM. Antimicrobial susceptibilities and beta-lactamase characterization of *Capnocytophaga* species. *Antimicrob Agents Chemother.* 1992;36(10):2197–2200. doi:10.1128/AAC.36.10.2197
24. Chu P, Howden BP, Jones S, Fell G, Roberts AK. Once bitten, twice shy: an unusual case report of a mycotic aortic aneurysm. *ANZ J Surg.* 2005;75(11):1024–1026. doi:10.1111/j.1445-2197.2005.03599.x

## Infection and Drug Resistance

Dovepress

### Publish your work in this journal

Infection and Drug Resistance is an international, peer-reviewed open-access journal that focuses on the optimal treatment of infection (bacterial, fungal and viral) and the development and institution of preventive strategies to minimize the development and spread of resistance. The journal is specifically concerned with the epidemiology of

antibiotic resistance and the mechanisms of resistance development and diffusion in both hospitals and the community. The manuscript management system is completely online and includes a very quick and fair peer-review system, which is all easy to use. Visit <http://www.dovepress.com/testimonials.php> to read real quotes from published authors.

Submit your manuscript here: <https://www.dovepress.com/infection-and-drug-resistance-journal>