

# Tumor microenvironment imaging: Benefits of multimodality to study chondrosarcoma

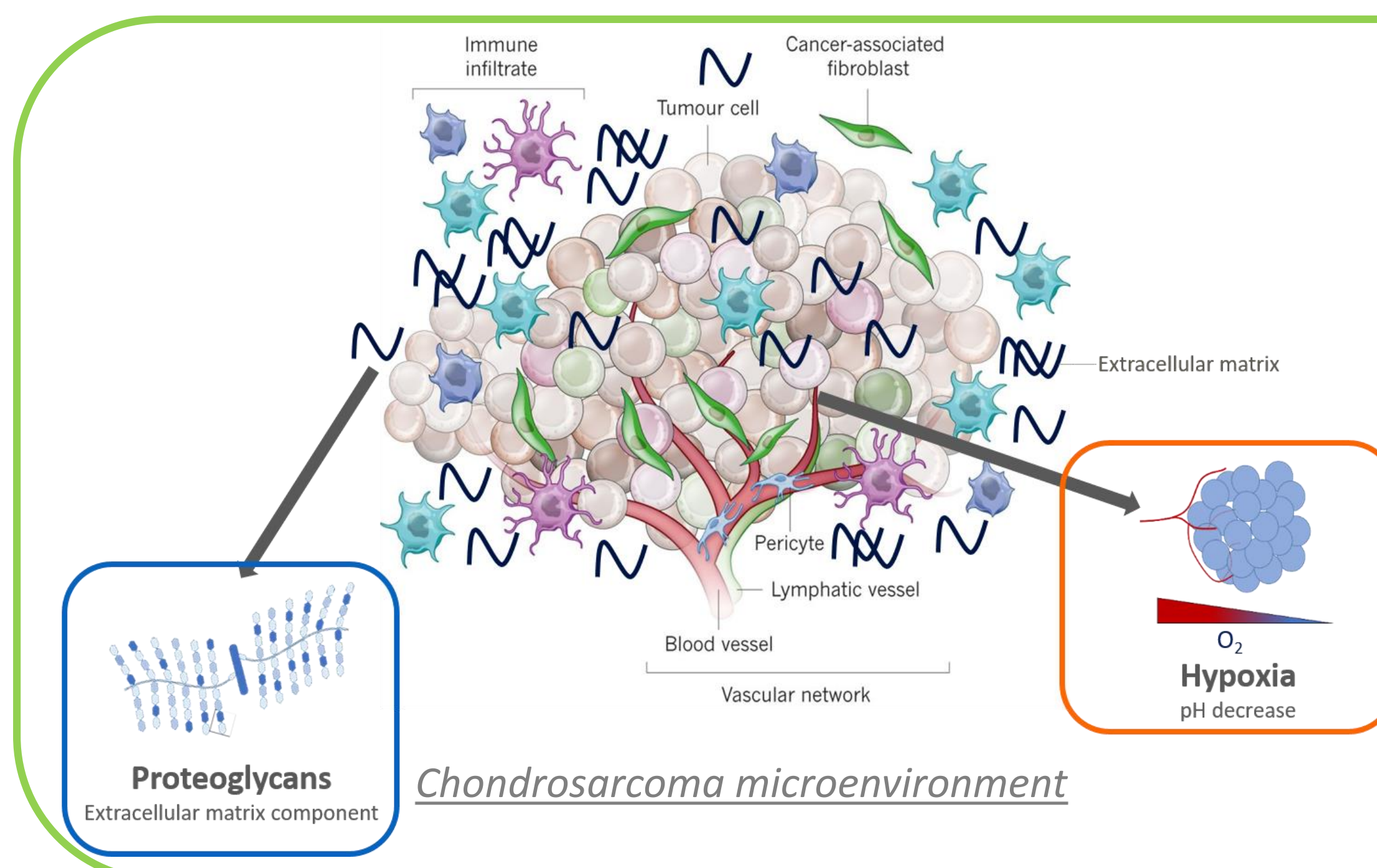
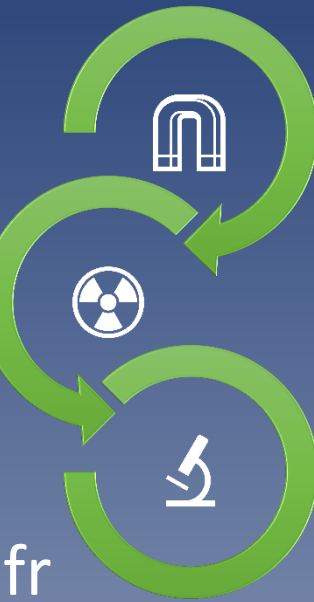Roxane Autissier<sup>1,2,3</sup> ; Leslie Mazuel<sup>1,2,3</sup> ; Elise Maubert<sup>2</sup> ; Jean-Marie Bonny<sup>1,3</sup> ; Philippe Auzeloux<sup>2</sup> ; Sébastien Schmitt<sup>2</sup> ; Amidou Traoré<sup>1,3</sup> ; Caroline Peyrode<sup>2</sup> ; Elisabeth Miot-Noirault<sup>2</sup> ; Guilhem Pagés<sup>1,3</sup>

<sup>1</sup>INRAE, UR QuaPA, F-63122 Saint-Genès-Champanelle, France

<sup>2</sup>Université Clermont Auvergne, INSERM, U1240 Imagerie Moléculaire et Stratégies Théranostiques, F-63000 Clermont-Ferrand, France

<sup>3</sup>INRAE, ISC AgroResonance, F-63122 Saint-Genès-Champanelle, France

Contact: Roxane.Autissier@uca.fr



## CONTEXT

Chondrosarcoma (CHS) is a malignant cartilaginous tumor representing the most common primary bone cancer in adults (<https://www.cancer.org/cancer/bone-cancer/about/key-statistics.html>, American Cancer Society Web site, 2021). Due to its dense chondrogenic extracellular matrix and hypoxic environment, CHS is highly resistant to conventional chemotherapy and radiation (Nazeri E *et al.*, *Crit Rev Oncol Hemat*, 2018). Development of multimodal imaging to characterize and map *in vivo* CHS microenvironment is fundamental for specific diagnosis and personalized therapy.

**In this context, we proposed to combine the resolution of chemical exchange saturation transfer (CEST) MRI with nuclear imaging sensitivity to improve CHS microenvironment understanding (Autissier R *et al.*, *Magn Reson Med*, 2021).**

## METHODS

Swarm rat CHSs were implanted subcutaneously in NMRI nude mice (n=10).

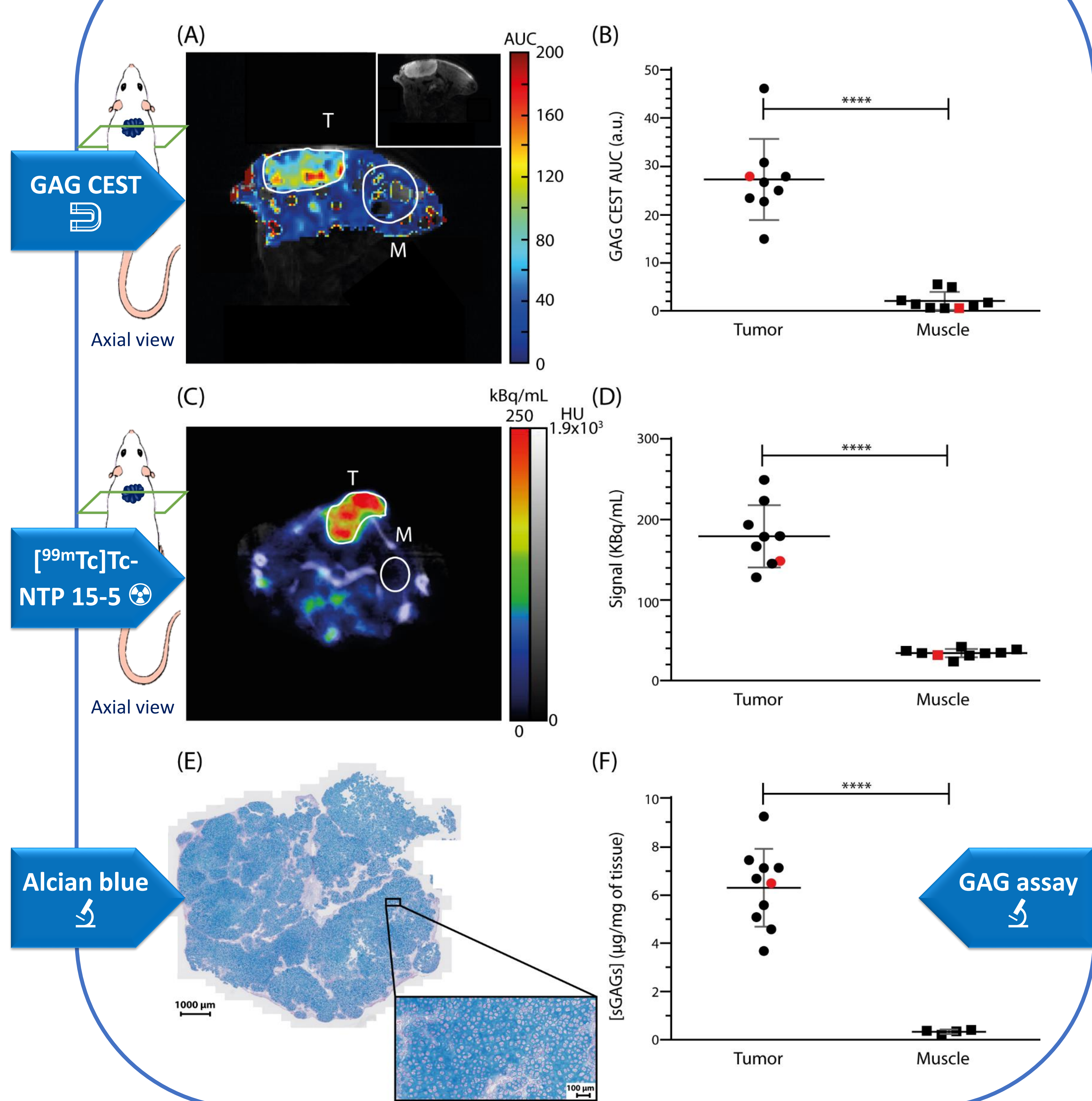
When tumors were measurable (12-16 days post-transplant), mice were imaged by CEST MRI (Dou W *et al.*, *Quant Imaging Med Surg*, 2019). Proteoglycans, the main component of chondrogenic extracellular matrix, were quantified by GAG CEST contrast. Guanidyl- and APT CEST contrasts were combined to characterize acidic pH, as hypoxia reflect.

These two features, proteoglycans and hypoxia, were assessed in parallel by nuclear imaging with [<sup>99m</sup>Tc]Tc-NTP 15-5 SPECT imaging (Peyrode C *et al.*, *Sarcoma*, 2011) and [<sup>18</sup>F]-FMISO PET imaging (Rajendran JG *et al.*, *Clin Cancer Res*, 2004), respectively.

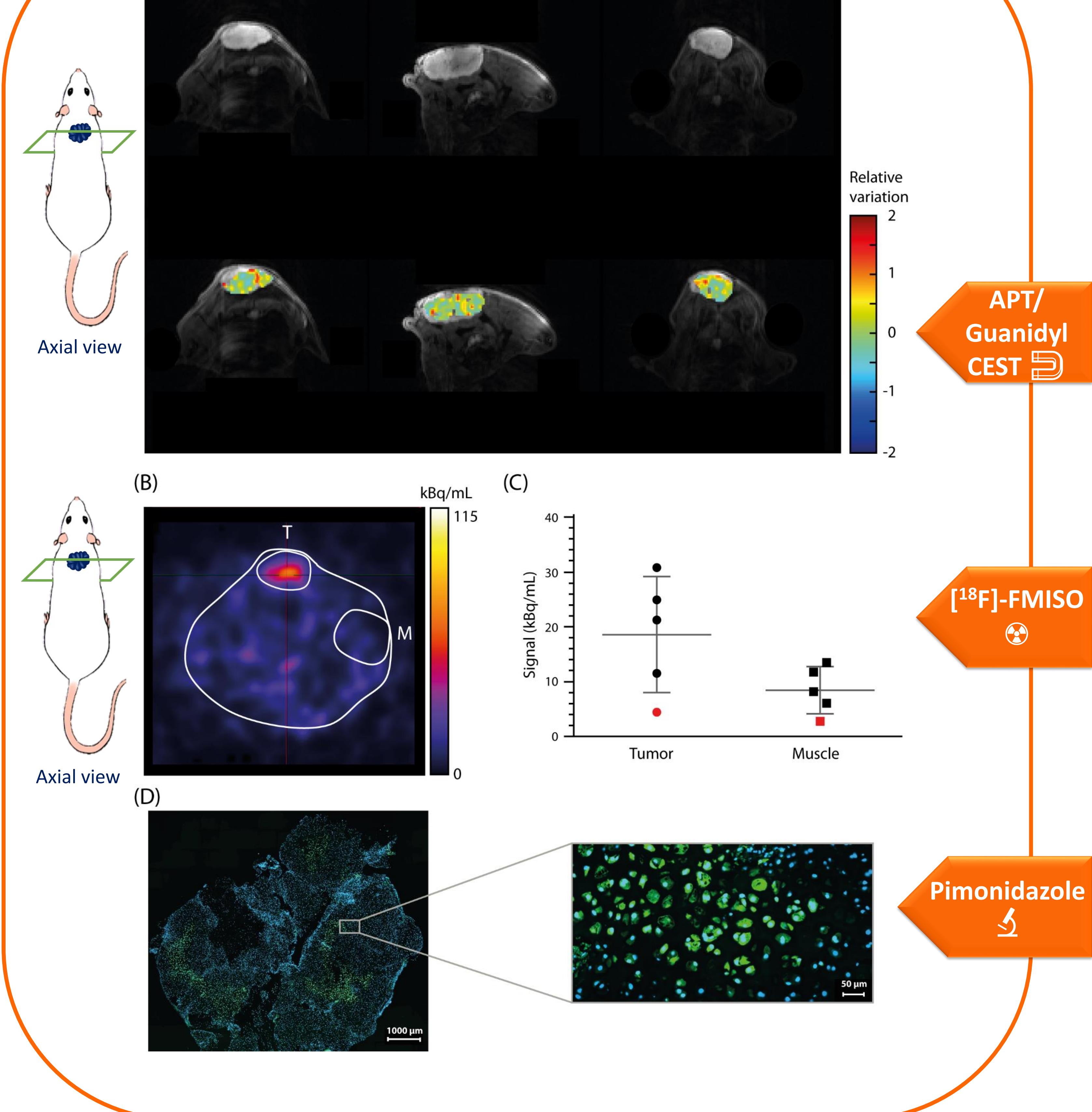
Data were also completed by *ex vivo* analyses of tumor and muscle proteoglycans (Alcian blue stain and biochemical assay with dimethylmethylene blue) and hypoxia (pimonidazole immunofluorescence).

## RESULTS

### PROTEOGLYCAN MAPPING



### HYPOXIA MAPPING



**CONCLUSION:** The results from CEST MRI, nuclear imaging and *ex vivo* analyses were in agreement and highlighted a rich proteoglycan extracellular matrix and a heterogeneous hypoxic tumoral microenvironment for Swarm rat CHS xenograft in mice.

**This study emphasizes the role of multimodal imaging to characterize tumor phenotypes resistant to treatments and allows a better understanding of the relationship between tumor cells and their environment.**

Grants: "La Ligue contre le Cancer Auvergne-Rhône-Alpes". All imaging experiments were performed at In Vivo Imaging Auvergne (IVIA) facility (Clermont-Ferrand, France; <https://doi.org/10.18145/ivia>).