



HAL
open science

TUMOR MICROENVIRONMENT IMAGING: BENEFITS OF MULTIMODALITY TO STUDY CHONDROSARCOMA

Roxane Autissier, ; Leslie Mazuel, Elise Maubert, Jean-Marie Bonny, Philippe Auzeloux, Sébastien Schmitt, Amidou Traoré, Caroline Peyrode, Elisabeth Miot-Noirault, Guilhem Pagés

► **To cite this version:**

Roxane Autissier, ; Leslie Mazuel, Elise Maubert, Jean-Marie Bonny, Philippe Auzeloux, et al.. TUMOR MICROENVIRONMENT IMAGING: BENEFITS OF MULTIMODALITY TO STUDY CHONDROSARCOMA. 2021. hal-03334052

HAL Id: hal-03334052

<https://hal.inrae.fr/hal-03334052>

Submitted on 3 Sep 2021

HAL is a multi-disciplinary open access archive for the deposit and dissemination of scientific research documents, whether they are published or not. The documents may come from teaching and research institutions in France or abroad, or from public or private research centers.

L'archive ouverte pluridisciplinaire **HAL**, est destinée au dépôt et à la diffusion de documents scientifiques de niveau recherche, publiés ou non, émanant des établissements d'enseignement et de recherche français ou étrangers, des laboratoires publics ou privés.

TUMOR MICROENVIRONMENT IMAGING: BENEFITS OF MULTIMODALITY TO STUDY CHONDROSARCOMA

Roxane Autissier^{1,2,3}; Leslie Mazuel^{1,2,3}; Elise Maubert²; Jean-Marie Bonny^{1,3}; Philippe Auzeloux²; Sébastien Schmitt²; Amidou Traoré^{1,3}; Caroline Peyrode²; Elisabeth Miot-Noirault²; Guilhem Pagés^{1,3}

¹INRAE, UR QuaPA, F-63122 Saint-Genès-Champanelle, France; ²Université Clermont Auvergne, INSERM, U1240 Imagerie Moléculaire et Stratégies Théranostiques, F-63000 Clermont-Ferrand, France; ³INRAE, ISC AgroResonance, F-63122 Saint-Genès-Champanelle, France

INTRODUCTION: Chondrosarcoma (CHS) is a malignant cartilaginous tumor representing the most common primary bone cancer in adults.[1] Due to its dense chondrogenic extracellular matrix and hypoxic environment, CHS is highly resistant to conventional chemotherapy and radiation.[2] Development of multimodal imaging to characterize and map *in vivo* CHS microenvironment is fundamental for specific diagnosis and personalized therapy. In this work, we proposed to combine the resolution of chemical exchange saturation transfer (CEST) MRI with nuclear imaging sensitivity to improve CHS microenvironment understanding.[3]

METHODS: Swarm rat CHSs were implanted subcutaneously in NMRI nude mice (n=10). When tumors were measurable (12-16 days post-transplant), mice were imaged by CEST MRI.[4] Proteoglycans, the main component of chondrogenic extracellular matrix, were quantified by GAG CEST contrast. Guanidyl- and APT CEST contrasts were combined to characterize acidic pH, as hypoxia reflect. These two features, proteoglycans and hypoxia, were assessed in parallel by nuclear imaging with ^{99m}Tc-NTP 15-5 SPECT imaging [5] and ¹⁸F-FMISO PET imaging [6], respectively. Data were also completed by *ex vivo* analyses of proteoglycans (Alcian blue stain and biochemical assay with dimethylmethylene blue) and hypoxia (pimonidazole immunofluorescence).

RESULTS/DISCUSSION: For extracellular matrix assessment, a proteoglycan concentration-related map was established with GAG CEST contrast showing more intense areas in the tumor than in the muscle (AUC = 27.29 ± 8.38 vs 2.15 ± 1.88, respectively; $P < 0.0001$) (Fig 1). Similarly, a significant ($P < 0.0001$) radiotracer uptake was observed by nuclear imaging with ^{99m}Tc-NTP 15-5 within tumoral tissue (179.38 ± 38.39 kBq/mL) as opposed to muscle (35.07 ± 5.17 kBq/mL). These results were supported by biochemical assay (6.33 ± 1.60 µg/mg vs 0.41 ± 0.09 µg/mg, respectively; $P < 0.0001$). Considering hypoxia, a small discrepancy was observed between CHS and muscle with ¹⁸F-FMISO PET imaging. Interestingly, with Guanidyl and APT contrast, the weakly hypoxic status of the CHS was explained by a heterogeneous acidic pH distribution within the tumoral tissue (Fig 1). Moreover, immunofluorescence with pimonidazole evidenced a weak staining within tumor mainly localized in the center of CHS lobules.

CONCLUSION: The results from CEST MRI, nuclear imaging and *ex vivo* analyses were in agreement and highlighted a rich proteoglycan extracellular matrix and a heterogeneous hypoxic tumoral microenvironment for Swarm rat CHS xenograft in mice. This study emphasizes the role of multimodal imaging to characterize tumor phenotypes resistant to treatments and allows a better understanding of the relationship between tumor cells and their environment.

ACKNOWLEDGMENTS: This project (R16146C) was supported by Ligue Contre le Cancer Auvergne-Rhône-Alpes. All imaging experiments were performed at In Vivo Imaging Auvergne (IVIA) facility (Clermont-Ferrand, France; <https://doi.org/10.18145/ivia>).

- [1] *Key Statistics for Bone Cancer: Key Statistics About Bone Cancer*. American Cancer Society Web site. Available at: <https://www.cancer.org/cancer/bone-cancer/about/key-statistics.html>. Updated January 12, 2021
- [2] Nazeri E, Gouran Savadkoohi M, Majidzadeh-A K et al., 2018, *Crit Rev Oncol Hematol*. 131:102-109, doi: 10.1016/j.critrevonc.2018.09.001
- [3] Autissier R, Mazuel L, Maubert E et al., 2021, *Magn Reson Med*. 86(2):1008-1018, doi: 10.1002/mrm.28781
- [4] Dou W, Lin CE, Ding H et al., 2019, *Quant Imaging Med Surg*. 9(10):1747-1766. doi: 10.21037/qims.2019.10.03
- [5] Peyrode C, Gouin F, Vidal A et al., 2011, *Sarcoma*. 2011:691608, doi: 10.1155/2011/691608
- [6] Rajendran JG, Mankoff DA, O'Sullivan F et al., 2004, *Clin Cancer Res*. 10(7):2245-52. doi: 10.1158/1078-0432.ccr-0688-3.

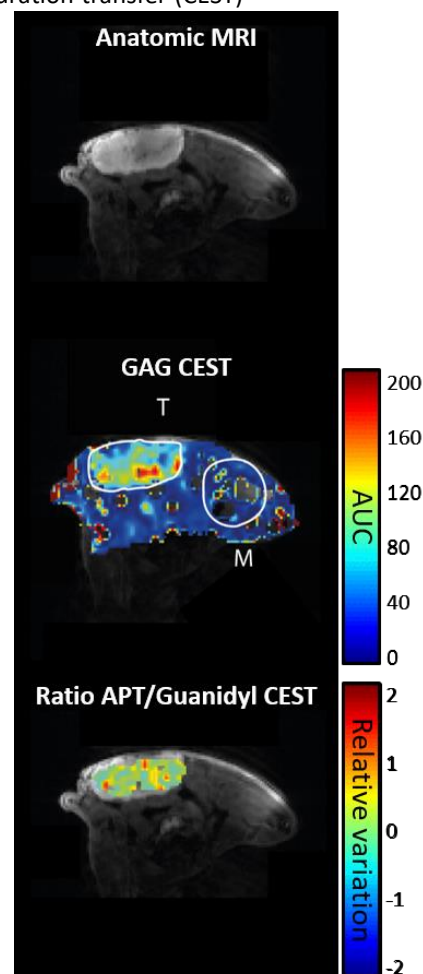


Figure 1 : *In vivo* CEST MRI maps obtained during the same acquisition; M: Muscle; T: Tumor