



HAL
open science

Ultrasonographic guided block of the median nerve

A. Beaumont, L. Bertoni, Jean-Marie Denoix

► **To cite this version:**

A. Beaumont, L. Bertoni, Jean-Marie Denoix. Ultrasonographic guided block of the median nerve. Equine Veterinary Education, 2021, 33 (4), pp.208-214. 10.1111/eve.13287 . hal-03988952

HAL Id: hal-03988952

<https://hal.inrae.fr/hal-03988952>

Submitted on 14 Feb 2023

HAL is a multi-disciplinary open access archive for the deposit and dissemination of scientific research documents, whether they are published or not. The documents may come from teaching and research institutions in France or abroad, or from public or private research centers.

L'archive ouverte pluridisciplinaire **HAL**, est destinée au dépôt et à la diffusion de documents scientifiques de niveau recherche, publiés ou non, émanant des établissements d'enseignement et de recherche français ou étrangers, des laboratoires publics ou privés.



Distributed under a Creative Commons Attribution 4.0 International License

Original Article

Ultrasonographic guided block of the median nerve

A. Beaumont* , L. Bertoni  and J-M. Denoix

CIRALE-NEV, INRA USC 957 BPLC, ENVA-UPEC, Normandie Equine Vallée, Goustranville, France

*Corresponding author email: audrey.beaumont@vet-alfort.fr

Keywords: horse; ultrasonographic guided injection; diagnostic analgesia; median nerve

Summary

Median nerve anaesthesia is sometimes indicated in the diagnosis of forelimb lameness in the horse in conjunction with the ulnar nerve block, but the localisation of the nerve to perform a precise deposition of the anaesthetic solution around and close to the nerve is difficult to achieve using the conventional blind technique. The objectives of this paper are to describe the ultrasonographic anatomy of the median nerve and the technique for performing an ultrasound-guided anaesthetic block of the nerve. The median nerve is imaged using a microconvex (or linear) probe in transverse section performed proximally to the chestnut on the medial aspect of the forearm. Distribution of the anaesthetic solution around the nerve is done by initially inserting the needle caudally and then cranially to the nerve and injecting 4–6 mL at each site. Control of the needle penetration avoids erroneous intravascular or intramuscular injections or sudden horse reaction. Ultrasound-guided injection has the potential to safely and accurately block the median nerve.

Introduction

Ultrasonographic guided injections (USGI) are currently widely used for treating joint disease (Denoix 2006; Carnicer *et al.* 2008) as well as neck, back and pelvic conditions in horses (Denoix and Heitzmann 2005). Growing interest for the use of these techniques is related to the rapid advances in ultrasound technology and the availability of compact portable machines with adequate image quality and resolution to perform USGI. Use of USGI for blocking nerves is rarely reported in equine medicine (Denoix and Audigié 2011; Denoix *et al.* 2020) but is widespread in other species (Shilo *et al.* 2010; Campoy *et al.* 2010; Echeverry *et al.* 2010) and in human medicine (Gray 2006; Marhofer and Chan 2007). Indeed, preliminary results indicate that the use of ultrasound can improve block success rate and decrease complications (Marhofer and Chan 2007). Diagnostic nerve blocks are an essential step to identify the source of pain in lameness evaluation of the horse. Unfortunately, many pitfalls are reported leading to false negative and false positive responses. Amongst them, inappropriate placement and diffusion of the anaesthetic solution are one of the most common complications (Denoix and Tapprest 1992; Nagy *et al.* 2009; Davidson 2018). The use of an ultrasound-guided technique for nerve blocks should assist in avoiding or reducing such complications. Median nerve anaesthesia in practice is often considered in the diagnostic approach of forelimb lameness using a conventional blind technique (Dyson 1984; Denoix 1991; Denoix and Tapprest 1992; Denoix 1995; Bassage and Ross 2003; Fürst 2012). Whilst the anatomical landmarks for blocking superficial nerves in the distal limb,

metacarpus and metatarsus can easily be identified (Dyson 1984; Denoix 1991; Denoix and Tapprest 1992), the exact location of deep nerves such as the median nerve is more difficult to determine, which enhances the interest of using USGI to anaesthetise this nerve.

To perform an optimal ultrasound-guided (USG) nerve block, the targeted nerve should be clearly identified, and the needle and the spread of the anaesthetic solution around the nerve should be tracked in real time (Marhofer and Chan 2007; Denoix *et al.* 2020). The objective of this paper is to describe the ultrasonographic anatomy of the median nerve and the technique to perform USG block of this nerve.

Anatomy of the median nerve

The median nerve is the biggest nerve of the forearm (Ghoshal and Getty 1968; Barone and Simoens 2010). It runs

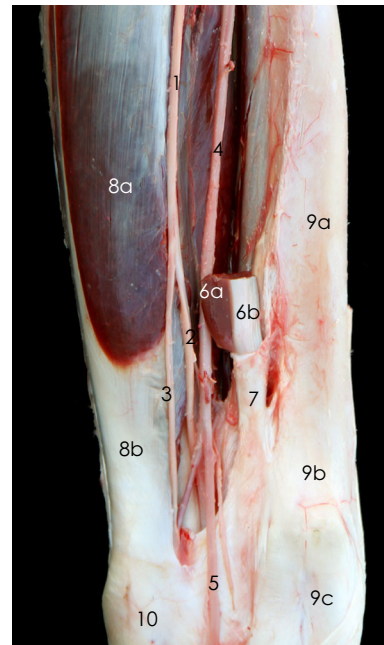


Fig 1: Medial aspect of the dissected antebrachium: superficial structures. Vessels and nerves: 1 – median nerve; 2 – medial palmar nerve; 3 – Ramus communicans with ulnar nerve (lateral palmar nerve); 4 – median artery; 5 – distal radial artery. Muscles and tendons: 6 – flexor carpi radialis muscle, 6a – muscle body, 6b – distal tendon; 7 – tendon sheath of the flexor carpi radialis distal tendon; 8 – flexor carpi ulnaris muscle, 8a – body, 8b – distal tendon. Bones: 9 – radius; 9a – body; 9b – distal metaphysis, 9c – styloid process; 10 – accessory carpal bone.

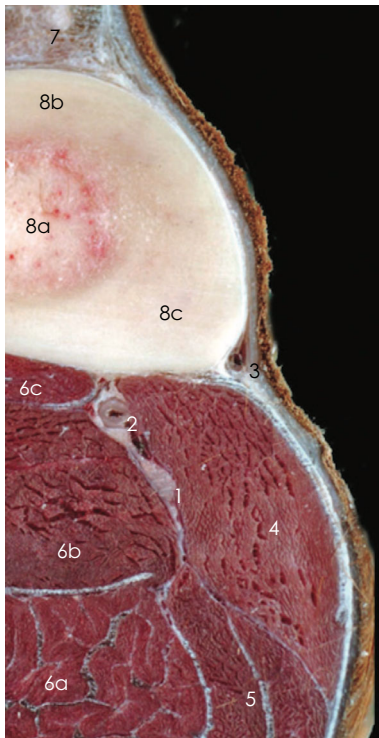


Fig 2: Transverse anatomical section of the antebrachium made at its mid-level (adapted from Denoix 2019). Vessels and nerves: 1 – median nerve; 2 – median artery and veins (collapsed); 3 – cephalic vein (collapsed). Muscles and tendons: 4 – flexor carpi radialis muscle; 5 – flexor carpi ulnaris muscle; 6 – deep digital flexor muscle, 6a – caudal part of the humeral head (fused with the superficial digital flexor muscle body), 6b – cranial part of the humeral head, 6c – radial head; 7 – extensor carpi radialis musculotendinous junction. Bones: 8 – radius, 8a – medullary cavity, 8b – cranial cortex, 8c – medial cortex.

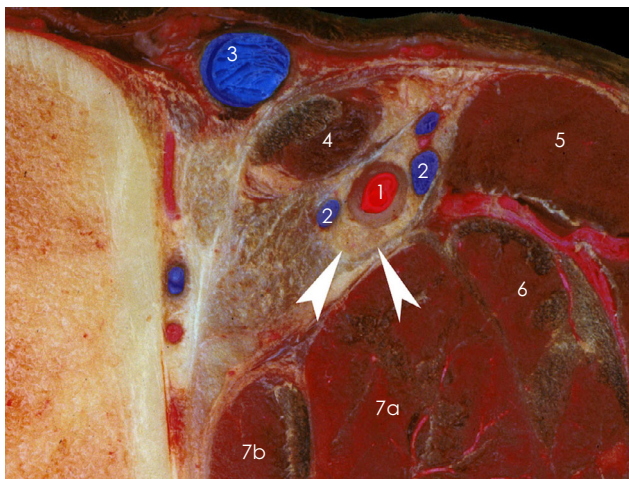


Fig 3: Transverse anatomical section of the antebrachium made just proximal to the chestnut and focused on the median nerve. Arrowheads: median nerve; 1 – median artery; 2 – median veins; 3 – cephalic vein; 4 – flexor carpi radialis musculotendinous junction; 5 – flexor carpi ulnaris muscle; 6 – superficial digital flexor muscle; 7a and 7b – deep digital flexor muscle.

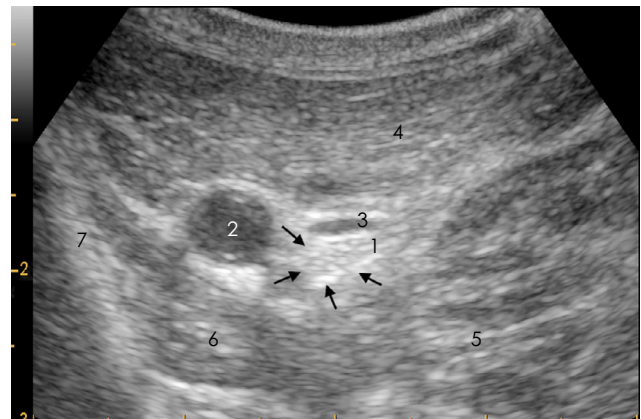

Fig 4: Transverse ultrasound image of the middle forearm using a medial approach with a 7.5 MHz microconvex probe: focused on the median nerve (arrows). Cranial is to the left. 1 – Median nerve; 2 – median artery; 3 – median vein (collapsed); 4 – flexor carpi radialis muscle; 5 – humeral head of the deep digital flexor muscle; 6 – radial head of the deep digital flexor muscle; 7 – radius (caudal aspect).

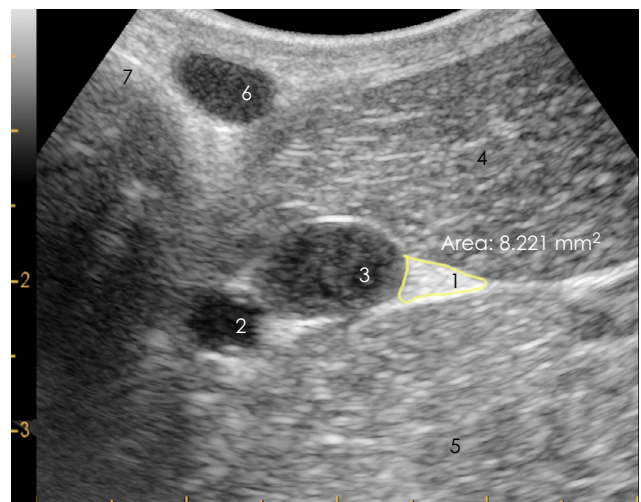

Fig 5: Triangular cross-sectional shape and area of the median nerve at the middle forearm. Cranial is to the left. 1 – Median nerve (cross-sectional area 8.2 mm²); 2 – median artery; 3 – median vein; 4 – flexor carpi radialis muscle; 5 – humeral head of the deep digital flexor muscle; 6 – cephalic vein; 7 – radius.

caudally to the radius and deep to the flexor carpi radialis. It is closely related to the median artery (Fig 1). In the proximal forearm, it provides strong muscle rami for the deep and superficial digital flexor muscles and for the flexor carpi radialis muscle (Barone 2000; Barone and Simoens 2010). In the middle forearm, it is located approximately 2 cm deep and 2 cm caudal to the radius and is then deep and caudal to the median artery and veins (Fig 2) (Denoix 2019). In the distal forearm, it can be found deep (lateral) or caudal to the median artery and veins (Fig 3)

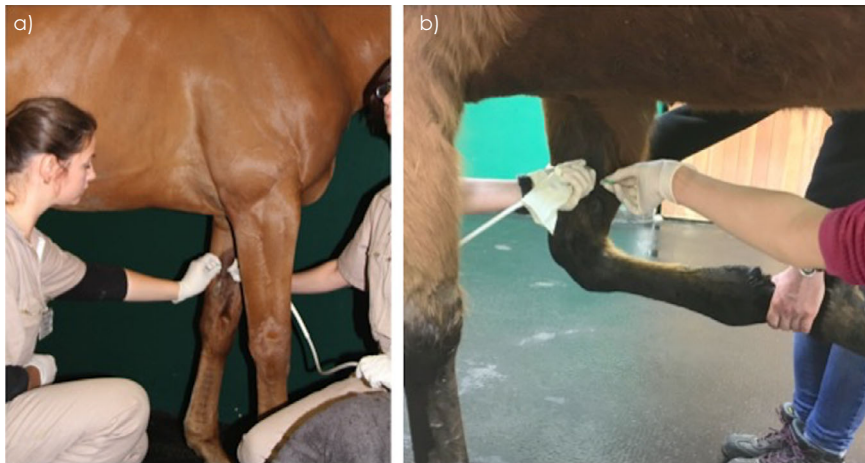


Fig 6: Positioning of the operators for injecting the median nerve using a caudal approach. a) On the weightbearing. A twitch is placed on the upper lip of the horse. The probe operator places the probe passing cranially to the opposite forelimb. The needle operator is approaching the injected limb caudomedially; b) on the flexed limb with a third operator. The operators' positions are the same, but a third operator is necessary to pull the injected limb caudally. This positioning is safer to avoid sudden flexion of the carpus of the weightbearing limb and the risk of fall.

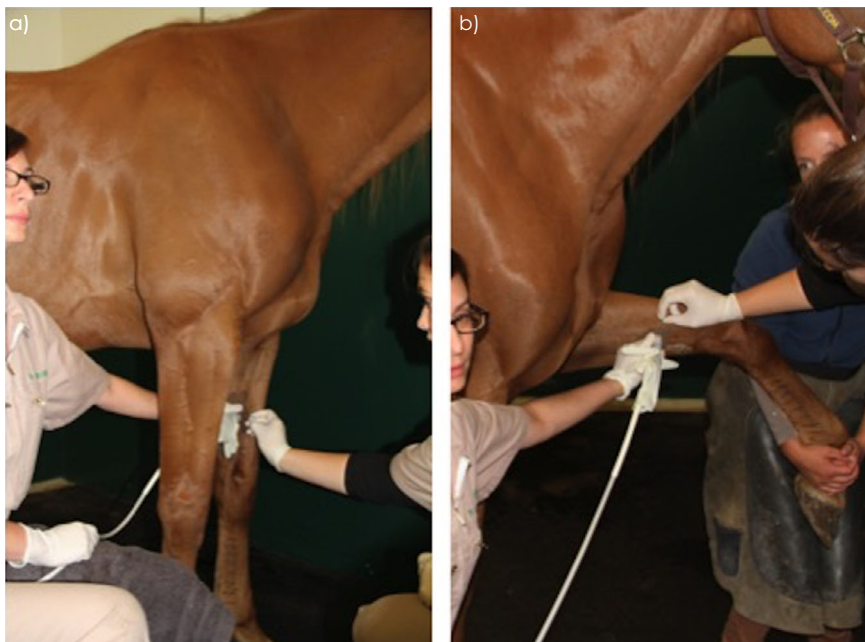


Fig 7: Positioning of the operators for injecting the median nerve using a cranial approach. a) On the weightbearing. A twitch is placed on the upper lip of the horse. The probe operator places the probe passing caudally to the opposite forelimb. The needle operator is approaching the injected limb craniomedially, after careful evaluation of the horse behaviour; b) On the flexed limb with a third operator. The third operator pulls the injected limb cranially and keeps it stable.

and finishes approximately at the distal quarter of the forearm at a bifurcation that produces two rami just above the accessory ligament of the superficial flexor muscle (Barone and Simoens 2010). One of them (lateral palmar nerve) joins the palmar ramus of the ulnar nerve and participates in the constitution of the lateral palmar common digital nerve. As for the main ramus (medial palmar nerve), it runs in the carpal canal and continues in the metacarpus as the medial common digital palmar nerve. The median nerve, together with the ulnar nerve,

provides all deep sensitivity and the main part of skin sensitivity of the carpus, metacarpus (including bones and tendons) and distal limb (fetlock, pastern and foot) (Denoux 1995; Bassage and Ross 2003; Barone and Simoens 2010).

Indications for performing an USG block of the median nerve include the following:

- Diagnosis of the site of pain of a lame horse when a proximal metacarpal nerve block is negative or partially positive (Denoux 1991).

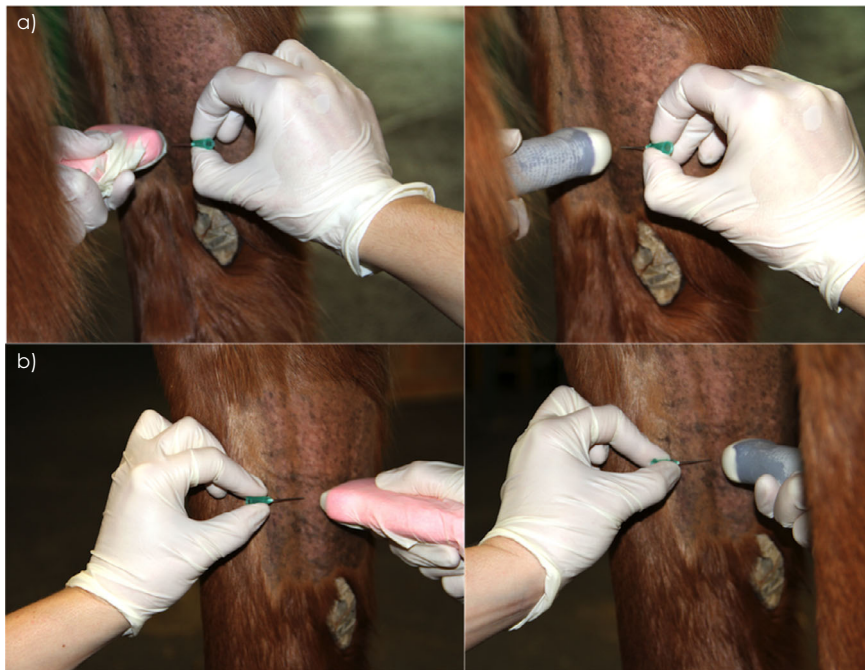

Fig 8: Positioning of the probes for injecting the median nerve. *a)* Linear and microconvex probes for the caudal approach; *b)* linear and microconvex probes for the cranial approach.

- Suspicion of subchondral carpal bone pain that does not respond to intra-articular analgesia of the carpus (Bassage and Ross 2003).
- Suspicion of lameness arising from the carpal canal (Bassage and Ross 2003).
- Exclusion of any distal or middle forelimb cause of pain when a proximal forelimb lameness is suspected (Denoix 1995).
- Standing surgery on the carpus or proximal metacarpus. For example, this block can be performed to facilitate lavage of the carpal joints or carpal canal or to perform regional limb perfusion of antimicrobials in standing horses (Bassage and Ross 2003).

Usually an ulnar nerve block is done in conjunction with the median nerve block to induce complete anaesthesia of the distal limb (carpus, metacarpus and digital area).

Ultrasonographic anatomy of the median nerve in the middle forearm

On a transverse ultrasound section performed proximally to the chestnut using a medial approach, the median nerve is imaged as an echogenic structure close to the median artery and veins. This neurovascular bundle is deep to the flexor carpi radialis muscle body, medial to humeral head of the deep digital flexor muscle (DDFM) body and caudal to the radial head of DDFM (Fig 4). As mentioned previously, it can be found deep or caudal to the median artery. Its cross-sectional shape can vary from triangular to oval depending on its location. Its cross-section is approximately between 8 and 10 mm² in a 550 kg horse (Fig 5). It is usually 20–25 mm deep to the skin (Alexander and Dobson 2003) and 20–22 mm caudal to the caudal cortex of the radius (Denoix 1995). On high detailed ultrasonographic images, its

fascicular architecture can be seen (Fig 4) (Alexander and Dobson 2003; Denoix and Audigié 2011).

Technical data for performing an ultrasonographic guided block of the median nerve

Equipment and preparation

The basic equipment to perform an USG block of the median nerve includes a 25 mm 21-gauge needle and a 6–10 MHz microconvex probe. A linear probe can also be used but adequate positioning is required to improve ultrasonographic image quality (Whitcomb 2009) and to facilitate visualisation and guidance of the needle. The adequate positioning will be described and illustrated in the next paragraph describing the USGI technique. The use of an epijet (Venipuncture Set) may help to avoid repositioning the needle if the horse moves (Denoix *et al.*, 2020). If an epijet is used, it is important to flush the extension set to avoid injecting gas which can cause acoustic shadowing and comet artefacts, making it more difficult to visualise the nerve (Zekas and Forrest 2005).

If too long, the hair is clipped from the chestnut to 5 cm proximal at the medial aspect of the forearm. The skin is prepared aseptically. A sterile glove is placed over the microconvex probe.

Horse restrain and operator(s) positioning

The median nerve can either be blocked on the weightbearing or on the flexed limb. In our experience, it is safer to block the median nerve on the flexed limb as the horse may flex the limb and fall down if the needle touches the nerve. However, the flexed procedure requires three operators. A twitch is placed on the upper lip of the horse, and both operators (one holding the probe, and one placing the needle) are approaching the medial aspect of the

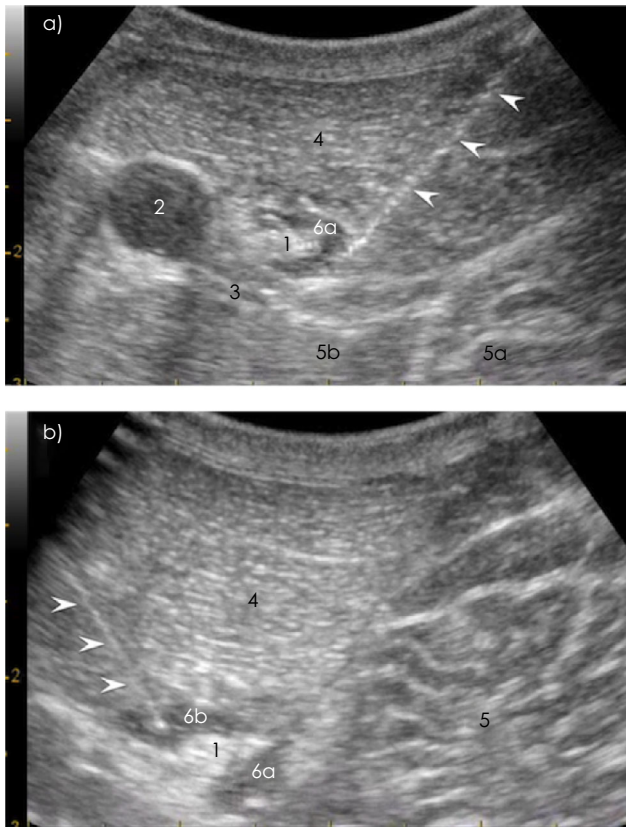


Fig 9: Ultrasonographic guided perineural injection of the median nerve – transverse ultrasound image of the medial part of the middle forearm with a microconvex probe. Cranial is to the left. **a)** Caudal approach; **b)** cranial approach. 1 – Median nerve; 2 – median artery; 3 – median vein; 4 – flexor carpi radialis muscle; 5 – humeral head of the deep digital flexor muscle, 5a – caudal part of the humeral head, 5b – cranial part of the humeral head; 6a – anaesthetic solution injected in the conjunctive tissue at the caudal aspect of the nerve, 6b – anaesthetic solution injected in the conjunctive tissue at the cranial aspect of the nerve. Arrowheads: needle.

injected limb from the opposite side of the horse for ergonomic and safety reasons (Figs 6 and 7). To achieve a complete and efficient block of the median nerve, it is best to combine injection of local anaesthetic solution caudally and cranially to the nerve.

Injection of the caudal aspect of the median nerve on the weightbearing limb is performed with the guide operator imaging the nerve from the cranial aspect of the opposite forelimb, and the needle operator is operating from the caudal aspect of this limb (Figs 6a and 8a). On the flexed limb, the operators' positions are the same but a third operator is necessary to hold the injected limb in a retracted position (Fig 6b). The operators' positions are reversed for injecting the cranial aspect of the median nerve (Figs 7a and 8b). On the flexed limb, the third operator holds the injected limb in protraction (Fig 7b).

Ultrasonographic guided injection technique

Caudal approach

The probe is placed transversally at the medial aspect of the forearm over the flexor carpi radialis muscle body, proximal

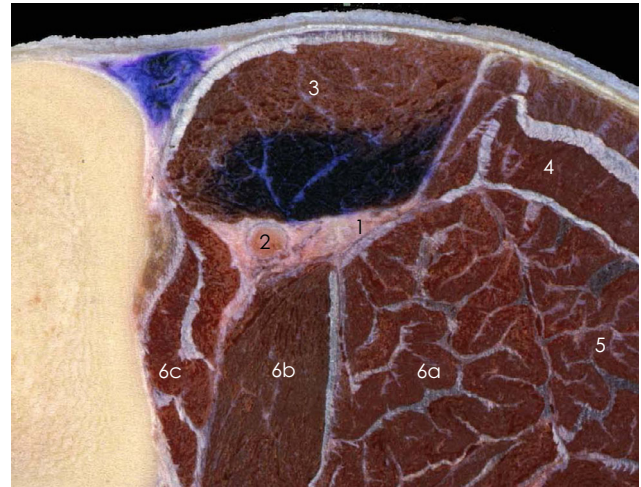

Fig 10: Erroneous perineural injection of the median nerve made with methyl violet on a isolated thoracic limb. Transverse anatomical section of the medial part of the middle forearm (adapted from Denoix 1995). The coloured solution has been injected in the deep and lateral part of the flexor carpi radialis muscle impairing diffusion to the nerve. Vessels and nerves: 1 – median nerve; 2 – median artery and veins (collapsed). Muscles and tendons: 3 – flexor carpi radialis muscle; 4 – flexor carpi ulnaris muscle; 5 – superficial digital flexor muscle; 6 – deep digital flexor muscle, 6a – caudal part of the humeral head (fused with the superficial digital flexor muscle body), 6b – cranial part of the humeral head, 6c – radial head.

to the chestnut and up to 5 cm proximally to it (Fig 6a,b). The median nerve is imaged close to the median artery. If a linear probe is used, it must be shifted cranially to facilitate adequate positioning of the needle (Fig 8a). The 25 mm long needle is placed in the ultrasound beam, caudally to the probe and directed to the caudal aspect of the median nerve (Fig 9a). Injection of 4–6 mL of mepivacaine¹ or lidocaine hydrochloride² is made in the loose connective tissue embedding the neurovascular bundle to avoid touching the nerve. Once anaesthetic fluid is seen close to the nerve, the needle is approached closer to it to complete the injection.

Cranial approach

The probe is placed transversely at the same level but moved slightly caudally to open enough space between its surface and the radius (Fig 7a,b). If a linear probe is used, it must be shifted caudally to facilitate adequate positioning of the needle (Fig 8b). A 25 mm long needle is placed cranially to the probe and directed to the cranial aspect of the median nerve (Fig 9b). As soon as the tip of the needle is seen in the perineural connective tissue, injection is performed. Once anaesthetic fluid is seen close to the median nerve, the needle can be placed closer to the nerve and injection of 4–6 mL of anaesthetic solution is made again.

Results of the ultrasonographic guided injections

The objective of performing both cranial and caudal approaches is to distribute the anaesthetic solution all around the nerve, achieving a complete troncular anaesthesia (Denoix *et al.* 2020). Erroneous intramuscular (Fig 10) (Denoix

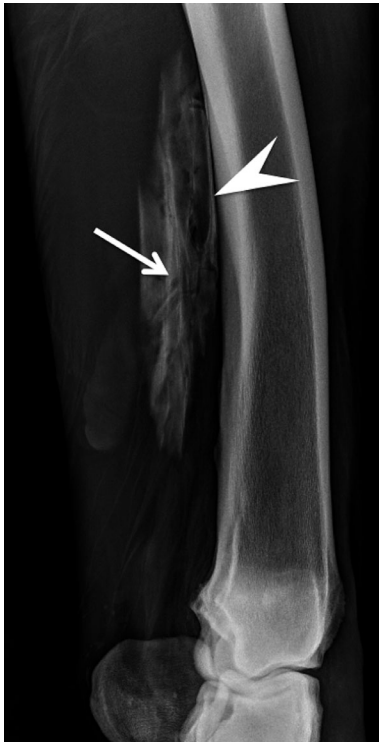

Fig 11: Lateromedial radiograph of the forearm after ultrasonographic guided injection of a total volume of 12 mL of diluted contrast material cranially and caudally to the median nerve. The radiograph was taken 10 min after injection. Note, the proximal diffusion of contrast material deep to the flexor carpi radialis (arrowhead) and the perivascular diffusion around the median nerve and vessels (arrow).

1995) and intravascular injections (Denoix and Tapprest 1992) must be avoided. As for every other nerve block (Nagy *et al.* 2009; Denoix *et al.* 2020), a proximo-distal diffusion of the anaesthetic solution in the perinervous connective tissue is expected and can be imaged using ultrasonography or documented using contrast radiography (Fig 11). Proximal diffusion in the connective tissue along the neurovascular bundle (median artery, veins, nerve) may block the lateral palmar nerve that joins the ulnar nerve and may induce partial anaesthesia of the muscle rami of the median nerve arising in the proximal antebrachium. No correlated adverse reactions on the horse gait have been noted following block of the median nerve. Five to ten minutes after injection, successful anaesthesia of the medial heel of the injected forelimb must be checked to assess reliability of the median nerve block (Dyson 1984). The horse can then be re-examined to assess changes in lameness from 5 min after injection. Many horses improve between 5 to 10 min after the block. If improvement is partial, further examinations up to 30 min after injection can be performed (Dyson 1984; Denoix and Tapprest 1992; Denoix 1995; Bassage and Ross 2003) but specificity for blocking exclusively distal or local pain decreases.

Discussion

In our experience, USGI is an easy and rewarding method for median nerve anaesthesia because of direct visualisation of

the nerve and diffusion of anaesthetic solution. In the study of Alexander and Dobson (2003), the success rate in identifying the median nerve with ultrasound was 100% on living horses. Five ultrasound examinations were also performed on cadaveric limbs including two USGI of methylene blue. After dissection, the methylene blue was well distributed around the median nerve on both specimens and ultrasonography was then considered to be potential interesting tool for identification of peripheral nerves, evaluation of nerve damage or to perform specific local anaesthesia. Ultrasonographic guidance was also reported to enable a real-time positioning of the needle and a correct distribution of anaesthetic solution (Marhofer and Chan 2007; Strakowski 2016). As the position of the nerve varies along the forearm, anaesthetic solution infusion can indeed be adjusted given the depth and position of the nerve with respect to the median artery. Control of the needle penetration is also crucial to avoid touching the median nerve and experience sudden horse reaction (Fürst 2012). Puncturing and intraneural injections of peripheral nerves did however not result in neurological damage in a human study (Bigeleisen 2006). USGI therefore appears to be more reliable and safer than the conventional blind technique that is based on external anatomical landmarks. Furthermore, for safety reasons, injection on the flexed limb is preferred to avoid sudden flexion of the carpus and the risk of fall. However, this technique requires the intervention of an additional operator.

USGI procedure has the potential to improve the accuracy of the median nerve block. For example, intramuscular injection in the flexor carpi radialis muscle or humeral head of the deep digital flexor muscle reduces diffusion in the adjacent connective tissue containing the median nerve. This erroneous injection is difficult to avoid using a blind technique. A review from Marhofer and Chan (2007) reports positive outcomes in human case series with improvement of success rates, faster onset of effect and longer duration of anaesthesia when using USGI technique compared to conventional techniques. Another study indicates that lower doses of anaesthetic solution can be injected when using USGI, reducing the occurrence and speed of diffusion of the anaesthetic solution (Eichenberger *et al.* 2009). Median nerve block is expected to induce complete analgesia of the medial aspect of the carpus and lower limb, and partial analgesia of its lateral aspect as median nerve fibres are joining the lateral common digital nerve through the ramus communicans crossing the palmar aspect of the flexor tendons in the metacarpus (Denoix and Tapprest 1992; Barone and Simoens 2010). Recent investigations have shown that some fibres coming from the lateral common digital nerve can run in a reverse direction to the ramus communicans to the medial common digital nerve (Schumacher *et al.* 2013). This could explain incomplete analgesia and skin anaesthesia of the medial aspect of the distal limb when the median nerve is anaesthetised alone. A complete analgesia of the deep structures of limb distal to the site of the block requires simultaneous blocks of the median and ulnar nerves (Denoix and Tapprest 1992; Bassage and Ross 2003).

The USGI technique described in this paper appears safer and more accurate than the blind technique to anaesthetise the median nerve. It can be performed easily with any portable ultrasound machine equipped with a microconvex or linear probe.

Authors' declaration of interest

No conflicts of interest have been declared.

Ethical animal research

Not applicable to this article.

Source of funding

The authors thank the Normandy Regional Council and the European Regional Development Funds for their financial support.

Authorship

A. Beaumont was responsible for the study design. All authors contributed to the study execution and image acquisition. A. Beaumont and L. Bertoni prepared the manuscript. All authors gave their final approval of the manuscript.

Manufacturers' addresses

¹Richter Pharma, Wels, Austria.

²CEVA Sante Animale, Libourne, France.

References

- Alexander, K. and Dobson, H. (2003) Ultrasonography of peripheral nerves in the normal adult horse. *Vet. Radiol. Ultrasound* **44**, 456-464.
- Barone, R. (2000) Anatomie comparée des Mammifères domestiques. In: *Tome second Arthrologie et Myologie*, Ed: R. Barone, Editions Vigot, Paris. pp 773-791.
- Barone, R. and Simoens, P. (2010) Anatomie comparée des mammifères domestiques. In: *Tome seventh Neurologie II*. Ed: R. Barone, Editions Vigot, Paris. pp 187-198.
- Bassage, L.H. II and Ross, M.W. (2003) Diagnostic analgesia. In: *Diagnosis and Management of Lameness in the Horse*, Eds: M.W. Ross and S.J. Dyson, Elsevier, St Louis. pp 93-123.
- Bigeleisen, P.E. (2006) Nerve puncture and apparent intraneural injection during ultrasound-guided axillary block does not invariably result in neurologic injury. *Anesthesiology* **105**, 779-783.
- Campoy, L., Bezuidenhout, A.J., Gleed, R.D., Martin-Flores, M., Raw, R.M., Santare, C.L., Jay, A.R. and Wang, A.L. (2010) Ultrasound-guided approach for axillary brachial plexus, femoral nerve, and sciatic nerve blocks in dogs. *Vet. Anaesth. Analg.* **37**, 144-153.
- Carnicer, D., Coudry, V. and Denoix, J.-M. (2008) Ultrasonographic guided injection of the scapulohumeral joint in horses. *Equine Vet. Educ.* **20**, 103-106.
- Davidson, E.J. (2018) Lameness evaluation of the athletic horse. *Vet. Clin. N. Am. Equine Pract.* **34**, 181-191.
- Denoix, J.-M. (1991) Anesthésies sémiologiques des régions proximales des membres chez le cheval. In: *Proceedings International Conference Equine Surgery*, Geneva. p 82.
- Denoix, J.-M. (1995) Anesthésie sémiologique nerveuse antébrachiale chez le cheval. *Rec. Med. Vet.* **171**, 747-756.
- Denoix, J.-M. (2006) Ultrasonographic guided injections of joints in horses. In: *Proceedings 9th World Equine Veterinary Association (WEVA) Congress*, Marrakech.
- Denoix, J.-M. (2019) *Essentials of Clinical Anatomy of the Equine Locomotor System*, CRC Press, Boca Raton. p 46.
- Denoix, J.-M. and Audigié, F. (2011) Diagnosis of peripheral nerve injuries in horses. In: *Proceedings 7th MRI User Meeting*, Bern.
- Denoix, J.-M. and Heitzmann, A.G. (2005) Apport des injections échoguidées pour les traitements locaux et intra-articulaires. In: *Proceedings of the Association Vétérinaire Équine Française (AVEF) Congrès*, Montpellier. pp 24-27.
- Denoix, J.-M. and Tapprest, J. (1992) Anesthésies sémiologiques nerveuses tronculaires dans le diagnostic des boiteries chez le cheval : 2e partie. *Point Vet.* **24**, 259-273.
- Denoix, J.-M., Beaumont, A. and Bertoni, L. (2020) Ultrasonographic guided block of the tibial nerve. *Equine Vet. Educ.* **32**, 372-377.
- Dyson, S. (1984) Nerve blocks and lameness diagnosis in the horse. *In Practice* **6**, 102-107.
- Echeverry, D.F., Gil, F., Laredo, F., Ayala, M.D., Belda, E., Soler, M. and Agut, A. (2010) Ultrasound-guided block of the sciatic and femoral nerves in dogs: a descriptive study. *Vet. J.* **186**, 210-215.
- Eichenberger, U., Stöckli, S., Marhofer, P., Huber, G., Willmann, P., Kettner, S.C., Pleiner, J., Curatolo, M. and Kapral, S. (2009) Minimal local anesthetic volume for peripheral nerve block: a new ultrasound-guided, nerve dimension-based method. *Region. Anesth. Pain Med.* **34**, 242.
- Fürst, A.E. (2012) Diagnostic anesthesia. In: *Equine Surgery*, Eds: J.A. Auer and J.A. Stick, Elsevier, St Louis. pp 998-1015.
- Ghoshal, N.G. and Getty, R. (1968) A comparative morphological study of the somatic innervation of the antebrachium and manus of the domestic animal (*Bos taurus*, *Ovis aries*, *Capra hircus*, *Sus scrofa domestica*, *Equus caballus*). *Iowa State J. Sci.* **42**, 283-296.
- Gray, A.T. (2006) Ultrasound-guided regional anesthesia current state of the art. *Anesthesiology* **104**, 368-373.
- Marhofer, P. and Chan, V.W.S. (2007) Ultrasound-guided regional anesthesia: current concepts and future trends. *Anesth. Analg.* **104**, 1265.
- Nagy, A., Bodo, G., Dyson, S.J., Szabo, F. and Barr, A.R.S. (2009) Diffusion of contrast medium after perineural injection of the palmar nerves: an in vivo and in vitro study. *Equine Vet. J.* **41**, 379-383.
- Schumacher, J., Taintor, J., Schumacher, J., Degraevs, F., Schramme, M. and Wilhite, R. (2013) Function of the *ramus communicans* of the medial and lateral palmar nerves of the horse: Function of the *ramus communicans* of the palmar nerves. *Equine Vet. J.* **45**, 31-35.
- Shilo, Y., Pascoe, P.J., Cissell, D., Johnson, E.G., Kass, P.H. and Wisner, E.R. (2010) Ultrasound-guided nerve blocks of the pelvic limb in dogs. *Vet. Anaesth. Analg.* **37**, 460-470.
- Strakowski, J.A. (2016) Ultrasound-guided peripheral nerve procedures. *Phys. Med. Rehabil. Clin. N. Am.* **27**, 687-715.
- Whitcomb, M.B. (2009) Review of ultrasonographic techniques to improve musculoskeletal image quality. *AAEP Proc.* **55**, 431-437.
- Zekas, Lisa J. and Forrest, Lisa J. (2005) Effect of perineural anesthesia on the ultrasonographic appearance of equine palmar metacarpal structures. *Vet. Radiol. Ultrasound* **44**, 59-64.