



HAL
open science

Recent advances in neutropenic enterocolitis: Insights into the role of gut microbiota

Natacha Kapandji, Elie Azoulay, Lara Zafrani

► To cite this version:

Natacha Kapandji, Elie Azoulay, Lara Zafrani. Recent advances in neutropenic enterocolitis: Insights into the role of gut microbiota. *Blood Reviews*, 2022, 54, pp.100944. 10.1016/j.blre.2022.100944 . hal-04297150

HAL Id: hal-04297150

<https://hal.inrae.fr/hal-04297150v1>

Submitted on 22 Jul 2024

HAL is a multi-disciplinary open access archive for the deposit and dissemination of scientific research documents, whether they are published or not. The documents may come from teaching and research institutions in France or abroad, or from public or private research centers.

L'archive ouverte pluridisciplinaire **HAL**, est destinée au dépôt et à la diffusion de documents scientifiques de niveau recherche, publiés ou non, émanant des établissements d'enseignement et de recherche français ou étrangers, des laboratoires publics ou privés.



Distributed under a Creative Commons Attribution - NonCommercial 4.0 International License

1 **Recent advances in neutropenic enterocolitis: insights into the role**
2 **of gut microbiota**

3
4 Natacha Kapandji MD^{1,2}, Elie Azoulay MD-PhD¹, Lara Zafrani MD-PhD¹

5 ^{1.} Intensive Care Unit, Saint Louis Academic Hospital,

6 1 avenue Claude Vellefaux, 75010 Paris, France

7 ^{2.} ProbiHote Team, MICALIS Institute, 78350 Jouy-en-Josas, INRAE, France

8

9

10

11

12 **Corresponding author: Natacha Kapandji**

13 Intensive Care Unit,

14 Saint Louis Academic Hospital,

15 1 avenue Claude Vellefaux, 75010 Paris, France

16 ProbiHote Team, MICALIS institute, INRAE, France

17 (French National Research Institute for Agriculture, Food and the Environment, France)

18 Mail: natacha.kapandji@gmail.com

19 Phone: 0033 667339214

20

21 **Emails of co-authors:**

22 Pr Elie Azoulay : elie.azoulay@aphp.fr

23 Pr Lara Zafrani : lara.zafrani@aphp.fr

24

25

26 TABLE OF CONTENTS

27		
28	ABSTRACT	4
29	KEY WORDS	4
30	INTRODUCTION	5
31	RESEARCH METHODOLOGY.....	5
32	EPIDEMIOLOGY.....	5
33	PATHOPHYSIOLOGY (Figure 1)	7
34	DIAGNOSTIC	10
35	a. CLINICAL PRESENTATION	10
36	b. RADIOLOGICAL PRESENTATION (Figure 2).....	10
37	c. DEFINITION (Figure 3)	11
38	d. HISTOPATHOLOGICAL DESCRIPTION (Figure 4)	13
39	e. MICROBIOLOGY	13
40	THERAPEUTIC MANAGEMENT (Figure 5).....	14
41	a. INFECTIOUS MANAGEMENT (Table 3)	14
42	b. HEMATOLOGICAL MANAGEMENT	15
43	c. METABOLIC MANAGEMENT.....	16
44	d. SURGICAL MANAGEMENT.....	17
45	CONCLUSION AND FUTURE CONSIDERATIONS.....	17
46	PRACTICE POINTS	17

47	RESEARCH AGENDA.....	18
48	ACKNOWLEDGMENTS	18
49	CONFLICT OF INTEREST	18
50	FUNDING	19
51	AUTHORS' CONTRIBUTIONS.....	19
52	BIBLIOGRAPHY.....	20
53	FIGURE LEGENDS.....	34
54		
55		

56 **ABSTRACT**

57 Neutropenic enterocolitis (NE) is a life-threatening complication associated with neutropenia
58 and the main cause of acute abdominal syndrome in neutropenic patients, especially those
59 receiving intensive chemotherapy. This review aims to delineate actual insights into this
60 clinical entity, to emphasize diagnostic and therapeutic management, and to generate
61 hypotheses on pathophysiology to identify avenues for research. Diagnosis is based on the
62 association of neutropenia, fever, abdominal symptoms, and radiologic bowel wall thickening.
63 Main complications are sepsis, perforations, and gastrointestinal bleeding. Several
64 mechanisms may be responsible for mucosal injury: treatment-induced necrosis of the
65 intestinal specific infiltrates, spontaneous intramural hemorrhage, or microvascular
66 thrombosis. The prevailing cause is the direct cytotoxicity of chemotherapy. However, the
67 role of gut dysbiosis in NE remains to be fully elucidated. Therapeutic management includes
68 early multidrug antibiotherapy, transfusion support, hematopoietic growth factor treatment,
69 fluid resuscitation, correction of electrolytes imbalance, and bowel rest. Indication and timing
70 for surgical management are still debated.

71

72

73

74 **KEY WORDS: neutropenic enterocolitis, microbiota, neutropenia**

75

76

77

78

79

80 INTRODUCTION

81 Neutropenic enterocolitis (NE) is a life-threatening digestive complication associated with
82 neutropenia. In 1962, Amromin and Solomon reported the first necropsy series of 69
83 necrotizing enteropathies [1]. Similar descriptions were reported by Prolla et al. in 1964 under
84 the name of agranulocytic lesions – colitis – or necrosis, highlighting the critical role of
85 immunosuppression in the pathogenesis of the disease [2]. The name typhlitis, from the Greek
86 word “typhlon”, meaning cecum – or cecitis, in Latin – was coined by Wagner and coworkers
87 in 1970 [3]. The current name of neutropenic enterocolitis was ultimately suggested by Moir
88 et al. in 1976, resulting in a more global definition encompassing severe neutropenia together
89 with either localized or diffused digestive inflammation [4]. We conducted this narrative
90 review to sum up insights into this entity.

91

92 RESEARCH METHODOLOGY

93 References for this review were identified through searches of PubMed, Embase and
94 Cochrane databases with the search terms: “NEUTROPENIC ENTEROCOLITIS”,
95 “NECROTIZING ENTEROPATHY”, “AGRANULOCYTIC LESIONS – COLITIS –
96 NECROSIS”, “TYPHLITIS”, and “CECITIS” from 1962 until December 2020. Articles were
97 also identified through searches of the authors’ own files. The research was restricted to
98 abstracts in English with full-text articles available. The final reference list was generated
99 based on originality and relevance to the broad scope of this review.

100

101 EPIDEMIOLOGY

102 NE was initially described in pediatric leukemic populations [3]. Adult patients with
103 leukemia, as well as patients presenting other hematological malignancies such as
104 lymphomas, multiple myeloma, and myelodysplastic syndromes, may develop NE, especially

105 when high dose chemotherapy is used as part of autologous hematopoietic stem cell
106 transplantation [5]. From the 2000s onwards, there has been a growing stream of case reports
107 of patients with solid tumors presenting NE, especially small-cell or non-small cell lung
108 carcinomas [6], breast [7], colorectal [8], ovarian [9], and testicular cancers [10]. NE is not
109 only a complication restricted to intensive chemotherapy. It has also been described in
110 leukemic patients before the administration of any chemotherapy [11], in aplastic anemia
111 [12], in cyclic neutropenia [13] and in toxic agranulocytosis [14]. Finally, it has been
112 described in other immunosuppressed patients, including patients infected with human
113 immunodeficiency virus [15], solid organ transplant recipients (kidney or heart) [16][17], and
114 patients under immunosuppressive treatment for chronic inflammatory diseases [18].

115

116 The prevalence of NE is extremely variable. Indeed, the existing literature consists primarily
117 of case reports and case series, with only a few cohort studies and no published prospective
118 studies. The first necropsy series reported high prevalence of NE, up to 46% in a leukemic
119 pediatric population [4]. The systematic review by Gorschlüter et al., which compiled studies
120 from 1953 to 2004, found a much lower combined prevalence of 5.3% in adults hospitalized
121 with hematological malignancies, solid tumors, and aplastic anemia [19]. Finally, a
122 prevalence ranging from 0.22% to 46% has been reported in recent literature [20][21] (**Table**
123 **1**). As will be further described, these discrepancies may be explained by: (1) the criteria used
124 for diagnosis – whether the final diagnosis is based on clinical suspicion, radiologically or
125 histologically confirmed; (2) the type of radiological imaging used – CT-scan or
126 ultrasonography; and (3) the inclusion or not of patients displaying lesions that do not involve
127 the cecum. NE ranks as the main cause of acute abdominal syndrome in neutropenic patients
128 admitted to the ICU, with a prevalence of 33% in this population [22]. There is little data on
129 the exact percentage of patients presenting NE and admitted to ICUs. NE may require ICU

130 management in case of septic shock, gastrointestinal bleeding, and digestive perforation. In
131 their cohort, Pugliese et al. found that 8% of NE patients required ICU admittance with a 23%
132 mortality rate. Duceau and team focused on 134 critically ill ICU patients over 8 years (2010-
133 2017). Mortality rate in this cohort was 38.8% [23]. This rises to 42.2% when surgical
134 management is required [24].

135

136 **PATHOPHYSIOLOGY (Figure 1)**

137 Although NE was described for the first time almost 60 years ago, its pathophysiology
138 remains unclear. Hypotheses are mostly based on clinical associations and histopathological
139 descriptions. It has been postulated that NE is the result of mucosal injury which, in the
140 context of neutropenia, leads to bacterial invasion of the bowel wall. The resulting
141 consequences sequentially involve: (1) bacterial translocation with subsequent uncontrolled
142 bacteremia in the context of neutropenia; and (2) local production of bacterial endotoxins,
143 creating cytotoxic edema and microvascular thrombosis with mucosal hypoperfusion and
144 necrosis in a self-perpetuating destructive process.

145

146 Causes for the initial mucosal injury could be multiple: mechanical lesions, treatment-induced
147 necrosis of the intestinal specific infiltrates, spontaneous intramural hemorrhage, or
148 microvascular thrombosis caused by coagulation disorders. However, the prevailing cause is
149 the direct cytotoxicity of chemotherapy. Indeed, NE has been reported mainly after
150 chemotherapy administration, especially during induction chemotherapy for acute leukemia
151 and autologous human stem-cell transplantation for lymphomas. Several drugs have been
152 implicated (**Table 2**): anthracyclines in the adult leukemic population regardless of the dose
153 [21], platinum-based chemotherapies in lung [6], testis [10], ovarian carcinomas [9]; and
154 taxanes in breast cancers [7].

155
156 Gastrointestinal mucositis emerges as a commonly reported risk factor for NE [25].
157 Gastrointestinal mucositis is an inflammation and/or ulceration of the gastrointestinal tract
158 occurring as a complication of chemotherapy and radiation therapy and thus represents the
159 missing link between chemotherapy and NE. It is mostly associated with aggressive
160 myeloablative chemotherapy. Sonis proposed a five-step model to explain its
161 pathophysiology, including [26]: (1) an initiation phase with the formation of reactive oxygen
162 species (ROS); (2) a primary damage response phase with inflammation and apoptosis largely
163 driven by the activation of Nuclear Factor- κ B (NF- κ B); (3) a signal amplification phase
164 promoted by key pro-inflammatory cytokines such as Tumor Necrosis Factor- α (TNF- α),
165 Interleukin-1 β (IL-1 β), and Interleukin-6 (IL-6) amplifying the inflammation response and
166 apoptosis; (4) a phase of ulcer formation promoting bacterial translocation; and (5) a healing
167 phase, with cell proliferation. We therefore hypothesize that NE could be the uncontrolled
168 step 4 in the proposal by Sonis. The two factors that could hamper the healing process may
169 reside in a deep and/or prolonged neutropenia and severe gut microbiota dysbiosis.

170
171 Indeed, prolonged neutropenia is the most robust risk factor of NE identified in the literature
172 [27], and has been repeatedly associated with mortality [28]. It may be responsible for the
173 perpetuation of bacterial sub-mucosal proliferation and intra-vascular translocation. Profound
174 neutropenia is also thought to be directly involved in mucosal lesions although the
175 underpinning mechanism remains to be clarified [29].

176
177 Gut microbiota play a critical role in the maintenance of mucosal trophicity, immune
178 homeostasis, and the clearance of invading pathogens. Low-diversity dysbiosis has been
179 observed in cancer patients [30]. In allogeneic hematopoietic stem cell transplantation

180 profound dysbiosis is associated with infectious complications [31], acute gastrointestinal
181 graft versus host disease (aGvHD-GI) [32], and overall mortality [33]. The main factors that
182 may alter gut microbiota in cancer patients are conditional chemotherapy [34], antibiotherapy
183 [35], and diet modifications. This reduced diversity in the gut microbiota is associated with a
184 reduced proportion of anaerobes and an increased proportion of facultative anaerobes from
185 the Proteobacteria and Bacilli phyla [30]. In 1970, Wagner et al. suggested the potential role
186 of digestive flora changes in the pathophysiology of NE [3]. Reyna-Figueroa and colleagues
187 also approached this issue when they described the association between the development of
188 NE and the use of antimicrobials [27], but no study has ever focused on the modifications of
189 gut microbiota within the course of NE. However, recent findings on the interaction of host-
190 microbiota, especially in stem cell transplant patients, may generate hypotheses to identify
191 avenues for research. First, within the Firmicutes phyla, the increased abundance of pro-
192 inflammatory bacteria from the Lactobacillales can compromise epithelial barrier integrity
193 [36] and stimulate local inflammation [37]. Concurrently, the reduced abundance of anti-
194 inflammatory short chain fatty acids producing bacteria from the Clostridiales order can lead
195 to increased permeability and inflammation [38]. Third, the injury of Paneth cells that has
196 been observed after total body irradiation or during aGvHD-GI may contribute to increased
197 intestinal permeability and bacterial translocation [39] [40]. Indeed, Paneth cells are epithelial
198 cells located in intestinal crypts which secrete antimicrobial peptides (defensins) that can
199 regulate the composition of the gut microbiome [40]. Moreover, they serve as multifunctional
200 guardians of stem cells, by providing essential niche signals involved in epithelial
201 regeneration [41]. Finally, Shono et al. have shown that mucus degradation induced by
202 mucinolytic bacteria such as *Akkermansia muciniphila* exacerbate aGvHD-GI and favor
203 bacterial translocation [42].

204

205 **DIAGNOSTIC**

206 **a. CLINICAL PRESENTATION**

207 Clinical presentation includes a broad range of non-specific symptoms: fever, abdominal pain
208 and tenderness, diarrhea or constipation, nausea, and vomiting [43]. NE-induced
209 complications can also be present at diagnosis, including: (1) infectious complications, ie.,
210 bacteremia, or fungemia, and septic shock; (2) local complications, ie., intestinal perforations,
211 peritonitis, abscesses, and fistulation [44]; and (3) gastrointestinal bleeding [45]. Finally,
212 occlusive syndrome [23], and abdominal compartment syndrome have also been reported
213 [46]. In patients who have received chemotherapy, symptomatology appears after a median
214 delay of 14 days after chemotherapy initiation [23]. Laboratory findings mostly include
215 pancytopenia and electrolyte imbalances with hyponatremia, hypophosphatemia,
216 hypokalemia, and hypoalbuminemia [43].

217

218 **b. RADIOLOGICAL PRESENTATION (Figure 2)**

219 Cartoni and colleagues [47] and Gorschlüter et al. [48], were the first to use ultrasound as part
220 of the diagnostic criteria. They observed that bowel wall thickening (1) could properly be
221 evaluated by ultrasonography; (2) was correlated with NE when higher than 4mm; and (3)
222 was correlated with mortality when greater than 10mm. Concurrently, Kirkpatrick and
223 Greenberg were the first to present an extensive CT-scan assessment of gastrointestinal
224 complications of neutropenic patients [49]. The study compared 53 patients with clinical
225 diagnosis of NE, 14 with *Clostridium difficile*-associated colitis and 7 with GvHD. In their
226 study, bowel wall thickening greater than 4mm was present in all patients regardless of the
227 diagnosis. The thickening proved to be greater than in *Clostridium difficile* colitis but located
228 exclusively in the colon. Characteristics of NE were patchy damage of the entire digestive
229 tract with bowel wall thickening greater than 4mm associated with pneumatosis in 21% of the

230 cases, mesenteric stranding in 51%, and ascites in 43% of patients. Nowadays, imaging
231 evaluation represents a key step in the diagnostic process. Recent studies have gone so far as
232 to suggest that an early radiological diagnosis either by ultrasound [50], or CT-scan [51] is
233 associated with survival. It provides multiple crucial points: (1) confirming the pathologic
234 bowel wall thickening according to the standardized criteria; (2) excluding differential
235 diagnoses of acute abdominal syndrome: appendicitis, acute cholecystitis, mesenteric
236 ischemia, acute pancreatitis, intussusception; (3) assessing factors associated with a severe
237 course: bowel wall thickening greater than 10mm, pneumatosis, extensive damage; and (4)
238 searching for complications: perforation, abscess, peritonitis, fistula, active bleeding. Either
239 abdominal CT-scan or ultrasound have been recommended. CT-scan should be performed
240 with contrast injection. Conversely, oral contrast administration is not only useless but could
241 be harmful in this context. Ultrasound is helpful for patient follow-up, and has the benefit of
242 being a low cost, no contrast injection without ionizing radiation, a major issue in the
243 pediatric population. It may also be a useful tool for imaging patients who are too unstable for
244 transport to the CT-scanner. However, because of its superior accuracy compared to
245 ultrasound to diagnose NE, to exclude differential diagnoses and to identify complications, a
246 CT-scan remains the standard reference and should be privileged in severe NE patients, when
247 feasible. Colonoscopy is contraindicated because of the high-risk of associated perforation.

248

249 **c. DEFINITION (Figure 3)**

250 The diagnostic for NE remains a challenge for every clinician as no specific criteria exists to
251 date. Nesher and Rolston formalized the last bundle of criteria in 2013 [52] with major criteria
252 including neutropenia under 500.10^9 neutrophils/L, fever exceeding 38.3°C (oral or rectal),
253 and bowel wall thickening (CT-scan or ultrasound) greater than 4mm in cross-section and
254 30mm in longitudinal section. Minor criteria include abdominal pain, distension or cramping,

255 diarrhea, and lower gastrointestinal bleeding. Several differential diagnoses must be ruled out,
256 including aGvHD-GI, radiation-induced enteritis, an exacerbation of inflammatory bowel
257 diseases or an infectious colitis. Microbiological investigations are necessary to exclude all
258 known gastrointestinal pathogens including *Clostridium difficile* and *Cytomegalovirus* (CMV)
259 gastrointestinal disease, as well as other viruses (*Norovirus*, *Rotavirus*, *Adenovirus*, *human*
260 *Astrovirus*, and *Sapovirus*), bacteria (*Salmonella* spp., *Yersinia enterocolitica*, *Shigella* spp.,
261 *Enterotoxigenic and Shiga-toxin producing Escherichia coli*, *Campylobacter* spp.,
262 *Plesiomonas shigelloides*, and *Vibrio* spp.), *Mucormycosis*, *Aspergillosis*, *Microsporidia* and
263 parasites (*Cryptosporidium* spp., *Giardia* spp., and *Strongyloides stercoralis*). Stool culture,
264 detection of toxigenic *Clostridium Difficile* and a parasitological stool examination should be
265 performed [53]. If available, enteropathogen multiplex nucleic acid amplification tests may be
266 helpful with a good sensitivity and specificity in symptomatic patients [53][54][55][56].
267 Regarding gastrointestinal CMV disease, proven disease requires macroscopic mucosal
268 lesions and viral documentation in tissue. However, because of the high risk of colic
269 perforation during NE, colonoscopy and gut biopsy are often contraindicated. We suggest a
270 kinetic analysis of plasma CMV DNA load to search for a possible CMV disease [57][58].
271 Similarly, microscopy observations and culture of tissue specimens allow definitive diagnoses
272 of gastrointestinal *Mucormycosis* and *Aspergillosis* [59]. However, a molecular based
273 diagnostic from blood and serum may be helpful for the diagnosis of *Mucormycosis* or
274 *Aspergillosis* [60]. Therefore, blood *Aspergillus* and Mucorales PCR testing and *Aspergillus*
275 Galactomannan antigen detection should be performed in the initial work-up of NE patients.
276 In case of persisting symptoms after hematological recovery, colonoscopy may be discussed
277 to rule out these differential diagnoses.
278

279 **d. HISTOPATHOLOGICAL DESCRIPTION (Figure 4)**

280 Histopathological descriptions came from initial autopsy studies [4] and pathological study of
281 surgical specimens [61]. Macroscopically, gross pathological findings include variable wall
282 thickness, luminal dilatation, and extensive ulcerations covered by necrotic and hemorrhagic
283 debris. NE can affect the entire digestive tract albeit with a patchy lesional pattern [61]. The
284 cecum and the right colon are the most frequently affected areas. Hypotheses accounting for
285 this specific location include the terminal nature of the cecum vascularization, its
286 distensibility with relative stasis and bacterial overgrowth, and its relative scarcity in
287 lymphoid organs [62]. Microscopical examinations disclose transmural edema, mucosal and
288 submucosal hemorrhage, necrosis varying from superficial ulcerations to full thickness, and
289 perivascular and submucosal microorganism proliferation [4][61]. The absence of
290 granulocytes is a salient histopathological feature, but moderate mononuclear inflammatory
291 infiltrate composed of lymphocytes, plasma cells, and histiocytes have been reported. Specific
292 leukemic infiltration was described in case reports when NE occurred before administration of
293 chemotherapy but is seldom reported in more recent series [61].

294

295 **e. MICROBIOLOGY**

296 In the latest studies, bacteremia accounts for 50% of patients [5][23][43]. Bacterial
297 identification yielded 60% *Enterobacteriaceae* (*Escherichia coli*, *Klebsiella spp.*,
298 *Enterobacter cloacae*), 25% Gram-positive cocci (*Enterococcus spp.*, *Staphylococcus spp.*,
299 *Streptococcus spp.*), 5% anaerobes and 6% *Pseudomonas spp.* [23]. Bacteriemia due to
300 *Clostridium* species: *Clostridium septicum* but also *Clostridium Tertium* and *Clostridium*
301 *Chauvoei* have been reported [63]. As *Clostridiaceae* are gas forming Gram-variable bacillus,
302 *Clostridiaceae* infections should be suspected whenever NE symptomatology is associated
303 with cutaneous necrotic lesions indicating myonecrosis. Fungemia accounts for around 6% of

304 patients. *Candida spp.* are the most represented species (76–94%). Radiologically assessed
305 enteritis is associated with the occurrence of fungemia [23]. A hypothesis for this observation
306 could be a higher fungi inoculum in the proximal digestive tract. Enteral damages and
307 fungemia could also be surrogates of NE severity. Indeed, NE severity involves severe
308 mucosal damage, neutropenia and dysbiosis of gut microbiota, which are known risk factors
309 for bloodstream *Candida* infection [64][65].

310

311 **THERAPEUTIC MANAGEMENT (Figure 5)**

312 Therapeutic management has not been standardized to date due to the dearth of high-level
313 evidence studies. NE is often associated with major complications such as septic shock, gut
314 perforation, and major gastrointestinal bleeding. Several studies suggest early ICU admission
315 policy in neutropenic patients as delayed ICU admission is associated with lower survival in
316 these cases [66][67][68][69]. Therefore, we strongly suggest early ICU admission of patients
317 with NE especially in the case of hemodynamic instability, suspected gastrointestinal
318 bleeding, or acute abdominal syndrome. Medical management should focus on infectious,
319 hematologic, and metabolic disorders.

320

321 **a. INFECTIOUS MANAGEMENT (Table 3)**

322 Sepsis is the main complication of NE. Akin to febrile neutropenia the empirical
323 antibiotherapy is a medical emergency and must be initiated within the first hour [70].
324 Empirical antibiotherapy should include an anti-pseudomonal beta-lactam (ceftazidime,
325 cefepime, piperacillin-tazobactam or carbapenem) associated with nitroimidazole if a
326 cephalosporin is selected. The choice should be tailored according to prior patient-specific
327 culture data and institutional epidemiology. Due to the high prevalence of associated
328 mucositis and gram-positive cocci (mainly *Enterococcus faecium*) bacteriemia in NE patients

329 (up to 27% of patients in the study by Duceau and coworkers [23]), we suggest that a
330 glycopeptide should be initiated, especially in patients with hemodynamic instability as
331 recommended by the Infectious Diseases Society of America guidelines [70]. The association
332 of an aminoglycoside should be considered in the case of hemodynamic instability or multi-
333 drug resistant colonization to broaden the spectrum of antibacterial coverage.

334

335 There is no recommendation about the proper time to initiate empiric antifungal therapy in
336 NE. In febrile neutropenia it is recommended after five to seven days of appropriate
337 antibacterial therapy and persistent fever or in case of hemodynamic instability [71][72].
338 However, the last study by Duceau et al. supported an earlier treatment in case of
339 radiologically assessed enteritis [23]. Echinocandins should be favored for empirical
340 treatment, especially in the case of hemodynamic instability or known colonization with an
341 azole-resistant strain because of their fungicide activity on all *Candida* species except
342 *Candida Parapsilosis* [73][74]. Azole antifungal agents should not be used empirically
343 especially in patients receiving fluconazole or posaconazole long-term prophylaxis because of
344 the risk of selection of *Candida Krusei* and acquired resistance in the case of *Candida*
345 *Glabrata*.

346

347 **b. HEMATOLOGICAL MANAGEMENT**

348 Prophylactic platelet transfusion is recommended to prevent severe hemorrhagic
349 complications. Platelet transfusion threshold should be 10g/L [75], but we advise raising the
350 threshold to 50g/L when gastrointestinal bleeding is observed. Similarly, coagulopathy
351 should be corrected. We suggest targeting a prothrombin time international normalized ratio
352 of more than 40% and a rate of fibrinogen of more than 1.5g/L.

353

354 Finally, as reported earlier, prolonged neutropenia is associated with NE [76], and NE-related
355 mortality [28]. Therefore, hematopoietic growth factor (G-CSF) treatment [77] and
356 granulocyte transfusion have been proposed [78]. However, there is no randomized control
357 trial regarding the use of G-CSF in NE. The use of G-CSF is nonetheless aligned with the
358 guidelines of the European Organization for Research and treatment of Cancer (EORTC)
359 which recommend G-CSF treatment in febrile neutropenic patients who are “at a higher risk
360 of infection-related complications” [79]. Those recommendations are based on the meta-
361 analysis by Clark et al. which observed a decrease of time to neutrophil recovery, length of
362 hospitalization, and infection-related mortality with G-CSF treatment [80].

363

364 **c. METABOLIC MANAGEMENT**

365 First, metabolic support must include intravenous fluid resuscitation and correction of
366 electrolytes imbalance [52]. Second, bowel rest and sometimes bowel decompression with
367 nasogastric suction are necessary. Total parenteral nutrition is then needed to prevent
368 malnutrition in these patients. Simultaneously, treatments that may aggravate ileus
369 (antidiarrheal and opioid agents) should be avoided.

370

371 Some authors consider the possibility of minimal enteral feeding in selected patients [19].
372 Pending clinical trials, this approach derives from a sound pathophysiological and
373 experimental perspective, including: (1) the association of enteral fasting with significant
374 mucosal atrophy and abnormal gut permeability in critically ill patients [81]; (2) the major
375 local inflammation, epithelial apoptosis and gut microbiota anomalies observed under total
376 parenteral nutrition [82]; and (3) the efficiency of minimal enteral feeding to shorten recovery
377 of methotrexate-induced mucositis in rat models [83].

378

379 **d. SURGICAL MANAGEMENT**

380 Due to the potential risks associated with abdominal surgery during neutropenia and
381 thrombopenia, physicians are often reluctant to perform surgery in NE patients. However, in
382 2018, Saillard and team [24] found that abdominal surgery during NE was not associated with
383 increased mortality as long as it was combined with intensive resuscitation. Shamberger and
384 coworkers were the first to issue objective criteria for surgical treatment: (1) the persistence of
385 gastrointestinal bleeding despite the medical treatment of thrombocytopenia and clotting
386 abnormalities; (2) the presence of free intraperitoneal gas revealing perforation or of parietal
387 pneumatosis revealing necrosis; (3) the clinical deterioration despite optimal medical
388 management; and (4) the development of other indications for surgery (appendicitis etc.) [84].
389 The optimal timing of surgery in NE patients remains to be defined [29].

390

391 **CONCLUSION AND FUTURE CONSIDERATIONS**

392 NE is a frequent and underestimated complication of neutropenia in onco-hematological
393 patients who often require ICU admission. The pathophysiology of NE needs to be
394 reconsidered in the light of recent discoveries on gut microbiota and its role in maintaining
395 the integrity of the intestinal barrier and inflammatory response. A better understanding of NE
396 mechanisms may improve specific management of these patients.

397

398 **PRACTICE POINTS**

- 399 1. Diagnosis of neutropenic enterocolitis is based on the association of neutropenia under
400 500.10^9 neutrophils/L with fever exceeding 38.3°C , and bowel wall thickening.
- 401 2. It is the main cause of acute abdominal syndrome in neutropenic patients, with a
402 prevalence of 33% in this population.

- 403 3. Sepsis is the main complication with bacteremia in 50% of patients
404 (Enterobacteriaceae but also Gram-positive cocci, Anaerobes, and Pseudomonas spp.)
405 and fungemia in 6% of patients.
- 406 4. Therapeutic management combines broad spectrum empiric antibiotherapy, potential
407 antifungal therapy, hematopoietic growth factors, transfusion support, and sometimes
408 surgical management.
- 409 5. Early antifungal therapy should be discussed in case of radiologically assessed
410 enteritis.

411

412 **RESEARCH AGENDA**

- 413 1. Studies focusing on the involvement of gut microbiota in the pathophysiology of
414 neutropenic enterocolitis may pave the way for identifying new microbiota-based
415 therapeutic interventions.
- 416 2. Indications and timing of surgery should be further evaluated in larger studies.
- 417 3. Indications of minimal enteral feeding should be further evaluated in larger studies.

418

419 **ACKNOWLEDGMENTS**

420 We thank Dr Roche, pathologist, and Dr Sand, radiologist, for their help in iconographic
421 interpretation.

422

423 **CONFLICT OF INTEREST**

424 Dr. Kapandji has nothing to disclose. Pr Azoulay has received fees for lectures from MSD,
425 Pfizer, and Alexion; his institution and research group have received support from Baxter,
426 Jazz Pharmaceuticals, Fisher & Paykel, Gilead, Alexion, and Ablynx; and he received support

427 for article research from Assistance Publique - Hôpitaux de Paris. Pr Zafrani's institution
428 received funding from the Assistance Publique - Hôpitaux de Paris, and Jazz Pharmaceuticals.

429

430 **FUNDING**

431 This research did not receive any specific grant from funding agencies in the public,
432 commercial, or not-for-profit sectors.

433

434 **AUTHORS' CONTRIBUTIONS**

435 Dr Natacha Kapandji: Corresponding author

436 - Literature search and data selection process

437 - Data analysis

438 - Figure drawing

439 - Original draft writing

440 Pr Elie Azoulay

441 - Verification of underlying data

442 - Validation

443 Pr Lara Zafrani:

444 - Literature search and data selection process

445 - Supervision

446 - Verification of underlying data

447 - Validation

448

449 **BIBLIOGRAPHY**

- 450 [1] Amromin GD and Solomon RD. Necrotizing Enteropathy: A Complication of Treated
451 Leukemia or Lymphoma Patients. JAMA 1962;182:23-29.
452 <https://doi.org/10.1001/jama.1962.03050400025005>.
- 453 [2] Prolla JC and Kirsner JB. The Gastrointestinal Lesions and Complications of the
454 Leukemias. Internal of Internal Medicine 1964;61:20:1084-1103.
- 455 [3] Wagner ML, Rosenberg HS, Fernbach DJ, Singleton EB. TYPHLITIS: A
456 COMPLICATION OF LEUKEMIA IN CHILDHOOD. American Journal of Roentgenology
457 1970;109:341-50. <https://doi.org/10.2214/ajr.109.2.341>.
- 458 [4] Moir DH, Bale PM. Necropsy findings in childhood leukaemia, emphasizing
459 neutropenic enterocolitis and cerebral calcification. Pathology 1976;8:247-58.
460 <https://doi.org/10.3109/00313027609059005>.
- 461 [5] Gil L, Poplawski D, Mol A, Nowicki A, Schneider A, Komarnicki M. Neutropenic
462 enterocolitis after high-dose chemotherapy and autologous stem cell transplantation:
463 incidence, risk factors, and outcome. Transplant Infectious Disease 2013;15:1-7.
464 <https://doi.org/10.1111/j.1399-3062.2012.00777.x>.
- 465 [6] Ji EH, Kim YM, Kim SJ, Yeom SJ, Ha SE, Kang HH, et al. A Case of Typhlitis
466 Developed after Chemotherapy with Irinotecan and Cisplatin in a Patient with Small Cell
467 Lung Carcinoma. Tuberc Respir Dis (Seoul) 2012;73:288-91.
468 <https://doi.org/10.4046/trd.2012.73.5.288>.
- 469 [7] Oehadian A, Fadjari TH. Neutropenic Enterocolitis in Breast Cancer Patient After
470 Taxane-Containing Chemotherapy. Acta Med Indones 2008;40:5:29-33.
- 471 [8] Kronawitter U, Kemeny NE, Blumgart L. Neutropenic enterocolitis in a patient with
472 colorectal carcinoma. Cancer 1997;80:656-60. [https://doi.org/10.1002/\(SICI\)1097-0142\(19970815\)80:4<656::AID-CNCR2>3.0.CO;2-L](https://doi.org/10.1002/(SICI)1097-0142(19970815)80:4<656::AID-CNCR2>3.0.CO;2-L).

- 474 [9] Gadducci A, Gargini A, Palla E, Fanucchi A, Genazzani AR. Neutropenic
475 Enterocolitis in an Advanced Epithelial Ovarian Cancer Patient Treated with
476 Paclitaxel/Platinum-based Chemotherapy: A Case Report and Review of the Literature.
477 *ANTICANCER RESEARCH* 2005;25:2509-14
- 478 [10] Takaoka E-I, Kawai K, Ando S, Shimazui T, Akaza H. Neutropenic Colitis during
479 Standard Dose Combination Chemotherapy with Nedaplatin and Irinotecan for Testicular
480 Cancer. *Japanese Journal of Clinical Oncology* 2006;36:60-3.
481 <https://doi.org/10.1093/jjco/hyi219>.
- 482 [11] Wilson DB, Rao A, Hulbert M, Mychaliska KP, Luchtman-Jones L, Hill DA, et al.
483 Neutropenic enterocolitis as a presenting complication of acute lymphoblastic leukemia: an
484 unusual case marked by delayed perforation of the descending colon. *Journal of Pediatric*
485 *Surgery* 2004;39:e18–20. <https://doi.org/10.1016/j.jpedsurg.2004.03.083>.
- 486 [12] Koh MB, Cheung DY, Noh CH, Lee SM, Park YB, Kim JI, et al. Bleeding polypoid
487 lesions in the colon as a presentation of neutropenic colitis in aplastic anemia. *Gastrointestinal*
488 *Endoscopy* 2009;69:953-4. <https://doi.org/10.1016/j.gie.2008.10.056>.
- 489 [13] Geelhoed GW, Kane MA, Dale DC, Wells SA. Colon ulceration and perforation in
490 Cyclic Neutropenia. *Journal of Pediatric Surgery* 1973;8:379–82.
491 [https://doi.org/10.1016/0022-3468\(73\)90105-X](https://doi.org/10.1016/0022-3468(73)90105-X).
- 492 [14] Carti EB, Oymaci E, Ucar AD, Coskun A, Erkan N, Yildirim M. Neutropenic
493 enterocolitis secondary to propylthiouracil-induced agranulocytosis. *The Turkish Journal of*
494 *Gastroenterology* 2014;25:588-9. <https://doi.org/10.5152/tjg.2014.3761>.
- 495 [15] Roca B, Fernandez P, Roca M. Typhlitis as a complication of influenza in a patient
496 with advanced HIV infection. *Postgraduate Medicine* 2018;130:650-1.
497 <https://doi.org/10.1080/00325481.2018.1508984>.
- 498 [16] Pelletier JH, Nagaraj S, Gbadegesin R, Wigfall D, McGann KA, Foreman J.

- 499 Neutropenic enterocolitis (typhlitis) in a pediatric renal transplant patient. A case report and
500 review of the literature. *Pediatric Transplantation* 2017;21:e13022.
501 <https://doi.org/10.1111/petr.13022>.
- 502 [17] Miller EE, Reardon LC. Neutropenic Enterocolitis in a Pediatric Heart Transplant
503 Recipient on Multiple Immunosuppressants. *Case Reports in Transplantation* 2018;1-4.
504 <https://doi.org/10.1155/2018/3264921>.
- 505 [18] Tamburrini S, Setola FR, Belfiore MP, Saturnino PP, Della Casa MG, Sarti G, et al.
506 Ultrasound diagnosis of typhlitis. *Journal of Ultrasound* 2019;22:103-6.
507 <https://doi.org/10.1007/s40477-018-0333-2>.
- 508 [19] Gorschlüter M, Mey U, Strehl J, Ziske C, Schepke M, Schmidt-Wolf IGH, et al.
509 Neutropenic enterocolitis in adults: systematic analysis of evidence quality. *European Journal*
510 *of Haematology* 2005;75:1–13. <https://doi.org/10.1111/j.1600-0609.2005.00442.x>.
- 511 [20] El-Matary W, Soleimani M, Spady D, Belletrutti M. Typhlitis in Children With
512 Malignancy: A Single Center Experience. *Journal of Pediatric Hematology/Oncology*
513 2011;33:e98–100. <https://doi.org/10.1097/MPH.0b013e3181eda606>.
- 514 [21] Seddon AN, Chaim J, Akin O, Drill E, Michael AG, Adel N, et al. Similar incidence
515 of typhlitis in patients receiving various doses of daunorubicin or idarubicin as induction for
516 acute myeloid leukemia. *Leukemia Research* 2018;68:48–50.
517 <https://doi.org/10.1016/j.leukres.2018.03.004>.
- 518 [22] Lebon D, Biard L, Buyse S, Schnell D, Lengliné E, Roussel C, et al. Gastrointestinal
519 emergencies in critically ill cancer patients. *Journal of Critical Care* 2017;40:69–75.
520 <https://doi.org/10.1016/j.jcrc.2017.03.015>.
- 521 [23] Duceau B, Picard M, Pirracchio R, Wanquet A, Pène F, Merceron S, et al.
522 Neutropenic Enterocolitis in Critically Ill Patients: Spectrum of the Disease and Risk of
523 Invasive Fungal Disease. *Critical Care Medicine* 2019;47:668-76.

- 524 <https://doi.org/10.1097/CCM.0000000000003687>.
- 525 [24] Saillard C, Zafrani L, Darmon M, Bisbal M, Chow-Chine L, Sannini A, et al. The
526 prognostic impact of abdominal surgery in cancer patients with neutropenic enterocolitis: a
527 systematic review and meta-analysis, on behalf the Groupe de Recherche en Réanimation
528 Respiratoire du patient d'Onco-Hématologie (GRRR-OH). *Annals of Intensive Care*
529 2018;8:47. <https://doi.org/10.1186/s13613-018-0394-6>.
- 530 [25] Moran H, Yaniv I, Ashkenazi S, Schwartz M, Fisher S, Levy I. Risk Factors for
531 Typhlitis in Pediatric Patients With Cancer: *Journal of Pediatric Hematology/Oncology*
532 2009;31:630–4. <https://doi.org/10.1097/MPH.0b013e3181b1ee28>.
- 533 [26] Sonis ST. The pathobiology of mucositis. *Nature Reviews Cancer* 2004;4:277–84.
534 <https://doi.org/10.1038/nrc1318>.
- 535 [27] Reyna-Figueroa J, Galindo-Delgado P, Madrid-Marina V. Antibiotic Use Before
536 Chemotherapy: A Risk Factor for Developing Neutropenic Colitis in Children With
537 Leukemia. *J Pediatr Hematol Oncol* 2015;37:121-27.
- 538 [28] Badgwell BD, Cormier JN, Wray CJ, Borthakur G, Qiao W, Rolston KV, et al.
539 Challenges in Surgical Management of Abdominal Pain in the Neutropenic Cancer Patient:
540 *Annals of Surgery* 2008;248:104–9. <https://doi.org/10.1097/SLA.0b013e3181724fe5>.
- 541 [29] Tokar B, Aydogdu S, Pasaoglu Ozgul, Ilhan H, Kasapoglu E. Neutropenic
542 enterocolitis: is it possible to break vicious circle between neutropenia and the bowel wall
543 inflammation by surgery? *International Journal of Colorectal Disease* 2003;18:455–8.
544 <https://doi.org/10.1007/s00384-003-0502-3>.
- 545 [30] Kriss M, Hazleton KZ, Nusbacher NM, Martin CG, Lozupone CA. Low diversity gut
546 microbiota dysbiosis: drivers, functional implications and recovery. *Current Opinion in*
547 *Microbiology* 2018;44:34–40. <https://doi.org/10.1016/j.mib.2018.07.003>.
- 548 [31] Galloway-Peña JR. The role of the gastrointestinal microbiome in infectious

- 549 complications during induction chemotherapy for acute myeloid leukemia. *Cancer*
550 2016;122:2186.-96. <https://onlinelibrary.wiley.com/doi/epdf/10.1002/cncr.30039>.
- 551 [32] Greco R, Nitti R, Mancini N, Pasciuta R, Lorentino F, Lupo-Stanghellini MT, et al.
552 Microbiome markers are early predictors of acute GVHD in allogeneic hematopoietic stem
553 cell transplant recipients. *Blood* 2021;137:1556–9. <https://doi.org/10.1182/blood.2020007158>.
- 554 [33] Peled JU, Gomes ALC, Devlin SM, Littmann ER, Taur Y, Sung AD, et al. Microbiota
555 as Predictor of Mortality in Allogeneic Hematopoietic-Cell Transplantation. *N Engl J Med*
556 2020;382:822–34. <https://doi.org/10.1056/NEJMoa1900623>.
- 557 [34] Zwielehner J, Lassel C, Hippe B, Pointner A, Switzeny OJ, Remely M, et al. Changes
558 in Human Fecal Microbiota Due to Chemotherapy Analyzed by TaqMan-PCR, 454
559 Sequencing and PCR-DGGE Fingerprinting. *PLoS One* 2011;6:e28654.
560 <https://doi.org/10.1371/journal.pone.e0028654>.
- 561 [35] Weber D, Hiergeist A, Weber M, Dettmer K, Wolff D, Hahn J, et al. Detrimental
562 effect of broad-spectrum antibiotics on intestinal microbiome diversity in patients after
563 allogeneic stem cell transplantation: Lack of commensal sparing antibiotics. *Clin Infect Dis*
564 2019;68:1303-10. doi: 10.1093/cid/ciy711.
- 565 [36] Steck N, Hoffmann M, Sava IG, Kim SC, Hahne H, Tonkonogy SL, et al.
566 *Enterococcus faecalis* Metalloprotease Compromises Epithelial Barrier and Contributes to
567 Intestinal Inflammation. *Gastroenterology* 2011;141:959–71.
568 <https://doi.org/10.1053/j.gastro.2011.05.035>.
- 569 [37] Kim SO, Sheikh HI, Ha S-D, Martins A, Reid G. G-CSF-mediated inhibition of JNK
570 is a key mechanism for *Lactobacillus rhamnosus*-induced suppression of TNF production in
571 macrophages. *Cell Microbiol* 2006;8:1958–71. [https://doi.org/10.1111/j.1462-](https://doi.org/10.1111/j.1462-5822.2006.00763.x)
572 [5822.2006.00763.x](https://doi.org/10.1111/j.1462-5822.2006.00763.x).
- 573 [38] Sun M, Wu W, Liu Z, Cong Y. Microbiota metabolite short chain fatty acids, GPCR,

- 574 and inflammatory bowel diseases. *Journal of Gastroenterology* 2017;52:1–8.
575 <https://doi.org/10.1007/s00535-016-1242-9>.
- 576 [39] Gorbunov NV, Kiang JG. Up-regulation of autophagy in small intestine Paneth cells
577 in response to total-body γ -irradiation: Ionizing irradiation increases autophagy in small
578 intestine Paneth cells. *J Pathol* 2009;219:242–52. <https://doi.org/10.1002/path.2591>.
- 579 [40] Eriguchi Y, Takashima S, Oka H, Shimoji S, Nakamura K, Uryu H, et al. Graft-
580 versus-host disease disrupts intestinal microbial ecology by inhibiting Paneth cell production
581 of α -defensins. *Blood* 2012;120:223–31. <https://doi.org/10.1182/blood-2011-12-401166>.
- 582 [41] Sato T, van Es JH, Snippert HJ, Stange DE, Vries RG, van den Born M, et al. Paneth
583 cells constitute the niche for Lgr5 stem cells in intestinal crypts. *Nature* 2011;469:415–8.
584 <https://doi.org/10.1038/nature09637>.
- 585 [42] Shono Y, Docampo MD, Peled JU, Perobelli SM, Velardi E, Tsai JJ, et al. Increased
586 GVHD-related mortality with broad-spectrum antibiotic use after allogeneic hematopoietic
587 stem cell transplantation in human patients and mice. *Sci Transl Med* 2016;8:339ra71.
588 <https://doi.org/10.1126/scitranslmed.aaf2311>.
- 589 [43] User İR, Akbayram S, Özokutan BH. Clinical Presentation, Prognostic Factors, and
590 Outcome in Neutropenic Enteropathy of Childhood Leukemia: *Journal of Pediatric*
591 *Hematology/Oncology* 2018;40:216–20. <https://doi.org/10.1097/MPH.0000000000001065>.
- 592 [44] Teichmann D, Cummins M, Keogh SJ, Rogers T. The complication of gastro-enteric
593 fistulisation in neutropenic enterocolitis secondary to aplastic anaemia: An Unusual
594 Complication. *Pediatric Blood & Cancer* 2014;61:358–9. <https://doi.org/10.1002/pbc.24531>.
- 595 [45] Meyerovitz M, Fellows K. Typhlitis: a cause of gastrointestinal hemorrhage in
596 children. *American Journal of Roentgenology* 1984;143:833–5.
597 <https://doi.org/10.2214/ajr.143.4.833>.
- 598 [46] van Vliet M, van der Hoeven HJG, van der Velden WJFM. Abdominal compartment

- 599 syndrome in neutropenic enterocolitis. *British Journal of Haematology* 2013;160:273–273.
600 <https://doi.org/10.1111/bjh.12140>.
- 601 [47] Cartoni C, Dragoni F, Micozzi A, Pescarmona E, Mecarocci S, Chirletti P, et al.
602 Neutropenic Enterocolitis in Patients With Acute Leukemia: Prognostic Significance of
603 Bowel Wall Thickening Detected by Ultrasonography. *Journal of Clinical Oncology*
604 2001;19:756–61. <https://doi.org/10.1200/JCO.2001.19.3.756>.
- 605 [48] Gorschlüter M, Marklein G, Höfling K, Clarenbach R, Baumgartner S, Hahn C, et al.
606 Abdominal infections in patients with acute leukaemia: a prospective study applying
607 ultrasonography and microbiology. *British Journal of Haematology* 2002;117:351–8.
608 <https://doi.org/10.1046/j.1365-2141.2002.03434.x>.
- 609 [49] Kirkpatrick IDC, Greenberg HM. Gastrointestinal Complications in the Neutropenic
610 Patient: Characterization and Differentiation with Abdominal CT. *Radiology* 2003;226:668–
611 74. <https://doi.org/10.1148/radiol.2263011932>.
- 612 [50] Pugliese N, Salvatore P, Iula DV, Catania MR, Chiurazzi F, Della Pepa R, et al.
613 Ultrasonography-driven combination antibiotic therapy with tigecycline significantly
614 increases survival among patients with neutropenic enterocolitis following cytarabine-
615 containing chemotherapy for the remission induction of acute myeloid leukemia. *Cancer Med*
616 2017;6:1500–11. <https://doi.org/10.1002/cam4.1063>.
- 617 [51] Vogel M, Goeppert B, Maksimovic O, Brodoefel H, Faul C, Claussen C, et al. CT
618 Features of Neutropenic Enterocolitis in Adult Patients with Hematological Diseases
619 Undergoing Chemotherapy. *RöFo - Fortschritte Auf Dem Gebiet Der Röntgenstrahlen Und*
620 *Der Bildgebenden Verfahren* 2010;182:1076–81. <https://doi.org/10.1055/s-0029-1245815>.
- 621 [52] Neshar L, Rolston KVI. Neutropenic Enterocolitis, a Growing Concern in the Era of
622 Widespread Use of Aggressive Chemotherapy. *Clinical Infectious Diseases* 2013;56:711–7.
623 <https://doi.org/10.1093/cid/cis998>.

- 624 [53] Florescu DF. The evaluation of critically ill transplant patients with infectious
625 diarrhea: *Current Opinion in Critical Care* 2017;23:364–71.
626 <https://doi.org/10.1097/MCC.0000000000000444>.
- 627 [54] Yalamanchili H, Dandachi D, Okhuysen PC. Use and Interpretation of Enteropathogen
628 Multiplex Nucleic Acid Amplification Tests in Patients With Suspected Infectious Diarrhea
629 *Gastroenterol Hepatol (N Y)* 2018;14:646-52
- 630 [55] Coste J-F, Vuiblet V, Moustapha B, Bouin A, Lavaud S, Toupance O, et al.
631 Microbiological diagnosis of severe diarrhea in kidney transplant recipients by use of
632 multiplex PCR assays. *J Clin Microbiol* 2013;51:1841–9. [https://doi.org/10.1128/JCM.03366-](https://doi.org/10.1128/JCM.03366-12)
633 12.
- 634 [56] Bueno F, Albert E, Giménez E, Piñana JL, Pérez A, Dolores Gómez M, et al. An
635 investigation of the potential association between gastrointestinal viral and bacterial infection
636 and development of intestinal acute graft versus host disease following allogeneic
637 hematopoietic stem cell transplantation. *J Med Virol* 2021;93:4773–9.
638 <https://doi.org/10.1002/jmv.26892>.
- 639 [57] Ljungman P, de la Camara R, Robin C, Crocchiolo R, Einsele H, Hill JA, et al.
640 Guidelines for the management of cytomegalovirus infection in patients with haematological
641 malignancies and after stem cell transplantation from the 2017 European Conference on
642 Infections in Leukaemia (ECIL 7). *The Lancet Infectious Diseases* 2019;19:e260–72.
643 [https://doi.org/10.1016/S1473-3099\(19\)30107-0](https://doi.org/10.1016/S1473-3099(19)30107-0).
- 644 [58] Ljungman P, Boeckh M, Hirsch HH, Josephson F, Lundgren J, Nichols G, et al.
645 Definitions of Cytomegalovirus Infection and Disease in Transplant Patients for Use in
646 Clinical Trials: Table 1. *Clin Infect Dis* 2017;64:87–91. <https://doi.org/10.1093/cid/ciw668>.
- 647 [59] Skiada A, Lass-Floerl C, Klimko N, Ibrahim A, Roilides E, Petrikkos G. Challenges in
648 the diagnosis and treatment of mucormycosis. *Medical Mycology* 2018;56:S93–101.

649 <https://doi.org/10.1093/mmy/myx101>.

650 [60] Millon L, Herbrecht R, Grenouillet F, Morio F, Alanio A, Letscher-Bru V, et al. Early
651 diagnosis and monitoring of mucormycosis by detection of circulating DNA in serum:
652 retrospective analysis of 44 cases collected through the French Surveillance Network of
653 Invasive Fungal Infections (RESSIF). *Clinical Microbiology and Infection* 2016;22:810.e1-
654 810.e8. <https://doi.org/10.1016/j.cmi.2015.12.006>.

655 [61] Sachak T, Arnold MA, Naini BV, Graham RP, Shah SS, Cruise M, et al. Neutropenic
656 Enterocolitis: New Insights Into a Deadly Entity. *The American Journal of Surgical Pathology*
657 2015;39:1635–42. <https://doi.org/10.1097/PAS.0000000000000517>.

658 [62] Dworkin B, Winawer SJ, Lightdale CJ. Typhlitis: Report of a case with long-term
659 survival and a review of the recent literature. *Digestive Diseases and Sciences* 1981;26:1032–
660 7. <https://doi.org/10.1007/BF01314769>.

661 [63] Weatherhead JE, Tweardy DJ. Lethal human neutropenic enterocolitis caused by
662 *Clostridium chauvoei* in the United States: Tip of the iceberg? *Journal of Infection*
663 2012;64:225–7. <https://doi.org/10.1016/j.jinf.2011.09.004>.

664 [64] Koh AY, Köhler JR, Cogshall KT, Van Rooijen N, Pier GB. Mucosal damage and
665 neutropenia are required for *Candida albicans* dissemination. *PLoS Pathog* 2008;4:e35.
666 <https://doi.org/10.1371/journal.ppat.0040035>.

667 [65] Zhai B, Ola M, Rolling T, Tosini NL, Joshowitz S, Littmann ER, et al. High-
668 resolution mycobiota analysis reveals dynamic intestinal translocation preceding invasive
669 candidiasis. *Nat Med* 2020;26:59–64. <https://doi.org/10.1038/s41591-019-0709-7>.

670 [66] Mokart D, Lambert J, Schnell D, Fouché L, Rabbat A, Kouatchet A, et al. Delayed
671 intensive care unit admission is associated with increased mortality in patients with cancer
672 with acute respiratory failure. *Leuk Lymphoma* 2013;54:1724–9.

673 <https://doi.org/10.3109/10428194.2012.753446>.

- 674 [67] Azoulay E, Pène F, Darmon M, Lengliné E, Benoit D, Soares M, et al. Managing
675 critically ill hematology patients: Time to think differently. *Blood Reviews* 2015;29:359–67.
676 <https://doi.org/10.1016/j.blre.2015.04.002>.
- 677 [68] Mokart D, Darmon M, Resche-Rigon M, Lemiale V, Pène F, Mayaux J, et al.
678 Prognosis of neutropenic patients admitted to the intensive care unit. *Intensive Care Medicine*
679 2015;41:296–303. <https://doi.org/10.1007/s00134-014-3615-y>.
- 680 [69] Song HK. Changing Presentation and Management of Neutropenic Enterocolitis.
681 *Archives of Surgery* 1998;133:979-82. <https://doi.org/10.1001/archsurg.133.9.979>.
- 682 [70] Freifeld AG, Bow EJ, Sepkowitz KA, Boeckh MJ, Ito JI, Mullen CA, et al. Clinical
683 practice guideline for the use of antimicrobial agents in neutropenic patients with cancer:
684 2010 Update by the Infectious Diseases Society of America. *Clin Infect Dis* 2011;52:427–31.
685 <https://doi.org/10.1093/cid/ciq147>.
- 686 [71] Schnell D, Azoulay E, Benoit D, Clouzeau B, Demaret P, Ducassou S, et al.
687 Management of neutropenic patients in the intensive care unit (NEWBORNS EXCLUDED)
688 recommendations from an expert panel from the French Intensive Care Society (SRLF) with
689 the French Group for Pediatric Intensive Care Emergencies (GFRUP), the French Society of
690 Anesthesia and Intensive Care (SFAR), the French Society of Hematology (SFH), the French
691 Society for Hospital Hygiene (SF2H), and the French Infectious Diseases Society (SPILF)
692 *Ann Intensive Care* 2016;6:90. doi: 10.1186/s13613-016-0189-6. Epub 2016 Sep 15.
- 693 [72] Maertens J, Marchetti O, Herbrecht R, Cornely OA, Flückiger U, Frère P, et al.
694 European guidelines for antifungal management in leukemia and hematopoietic stem cell
695 transplant recipients: summary of the ECIL 3--2009 update. *Bone Marrow Transplant*
696 2011;46:709–18. <https://doi.org/10.1038/bmt.2010.175>.
- 697 [73] Martin-Loeches I, Antonelli M, Cuenca-Estrella M, Dimopoulos G, Einav S, De
698 Waele JJ, et al. ESICM/ESCMID task force on practical management of invasive candidiasis

- 699 in critically ill patients. *Intensive Care Med* 2019;45:789–805.
700 <https://doi.org/10.1007/s00134-019-05599-w>.
- 701 [74] Tissot F, Agrawal S, Pagano L, Petrikkos G, Groll AH, Skiada A, et al. ECIL-6
702 guidelines for the treatment of invasive candidiasis, aspergillosis and mucormycosis in
703 leukemia and hematopoietic stem cell transplant patients. *Haematologica* 2017;102:433–44.
704 <https://doi.org/10.3324/haematol.2016.152900>.
- 705 [75] Schiffer CA, Bohlke K, Delaney M, Hume H, Magdalinski AJ, McCullough JJ, et al.
706 Platelet Transfusion for Patients With Cancer: American Society of Clinical Oncology
707 Clinical Practice Guideline Update. *Journal of Clinical Oncology* 2018;36:283–99.
708 <https://doi.org/10.1200/JCO.2017.76.1734>.
- 709 [76] Biasoli I, Spector N, Portugal RD, Domingues AC, Pulcheri W. Risk factors for
710 typhlitis: A case-control study. *ONCOLOGY REPORTS* 1997;4:1029-31.
711 doi: 10.3892/or.4.5.1029.
- 712 [77] Hanada T, Ono I, Hirano C, Kurosaki Y. Successful treatment of neutropenic
713 enterocolitis with recombinant granulocyte colony stimulating factor in a child with acute
714 lymphocytic leukaemia. *European Journal of Pediatrics* 1990;149:811–2.
715 <https://doi.org/10.1007/BF01957292>.
- 716 [78] Cherif H, Axdorph U, Kalin M, Björkholm M. Clinical experience of granulocyte
717 transfusion in the management of neutropenic patients with haematological malignancies and
718 severe infection. *Scandinavian Journal of Infectious Diseases* 2013;45:112–6.
719 <https://doi.org/10.3109/00365548.2012.714906>.
- 720 [79] Aapro MS, Bohlius J, Cameron DA, Lago LD, Donnelly JP, Kearney N, et al. 2010
721 update of EORTC guidelines for the use of granulocyte-colony stimulating factor to reduce
722 the incidence of chemotherapy-induced febrile neutropenia in adult patients with
723 lymphoproliferative disorders and solid tumours. *European Journal of Cancer* 2011;47:8–32.

724 <https://doi.org/10.1016/j.ejca.2010.10.013>.

725 [80] Clark OAC, Lyman GH, Castro AA, Clark LGO, Djulbegovic B. Colony-stimulating
726 factors for chemotherapy-induced febrile neutropenia: a meta-analysis of randomized
727 controlled trials. *J Clin Oncol* 2005;23:4198–214. <https://doi.org/10.1200/JCO.2005.05.645>.

728 [81] Hernandez G, Velasco N, Wainstein C, Castillo L, Bugedo G, Maiz A, et al. Gut
729 mucosal atrophy after a short enteral fasting period in critically ill patients. *Journal of Critical*
730 *Care* 1999;14:73–7. [https://doi.org/10.1016/S0883-9441\(99\)90017-5](https://doi.org/10.1016/S0883-9441(99)90017-5).

731 [82] Demehri FR, Barrett M, Ralls MW, Miyasaka EA, Feng Y, Teitelbaum DH. Intestinal
732 epithelial cell apoptosis and loss of barrier function in the setting of altered microbiota with
733 enteral nutrient deprivation. *Frontiers in Cellular and Infection Microbiology* 2013;3:105.
734 <https://doi.org/10.3389/fcimb.2013.00105>.

735 [83] Kuiken NSS, Rings EHHM, Havinga R, Groen AK, Tissing WJE. Effect of minimal
736 enteral feeding on recovery in a methotrexate-induced gastrointestinal mucositis rat model.
737 *Supportive Care in Cancer* 2016;24:1357–64. <https://doi.org/10.1007/s00520-015-2911-6>.

738 [84] Shamberger RC, Weinstein HJ, Delorey MJ, Levey RH. The medical and surgical
739 management of typhlitis in children with acute nonlymphocytic (myelogenous) leukemia.
740 *Cancer* 1986;57:603–9. [https://doi.org/10.1002/1097-0142\(19860201\)57:3<603::AID-](https://doi.org/10.1002/1097-0142(19860201)57:3<603::AID-CNCR2820570335>3.0.CO;2-K)
741 [CNCR2820570335>3.0.CO;2-K](https://doi.org/10.1002/1097-0142(19860201)57:3<603::AID-CNCR2820570335>3.0.CO;2-K).

742 [85] Steinberg D. Necrotizing Enterocolitis in Leukemia. *Archives of Internal Medicine*
743 1973;131:538. <https://doi.org/10.1001/archinte.1973.00320100066008>.

744 [86] Mower WJ. Neutropenic Enterocolitis in Adults With Acute Leukemia. *Archives of*
745 *Surgery* 1986;121:571. <https://doi.org/10.1001/archsurg.1986.01400050089012>.

746 [87] Katz JA, Mahoney DH, Fernbach DJ, Wagner ML, Gresik MV. Typhlitis. An 18-year
747 experience and postmortem review. *Cancer* 1990;65:1041–7. [https://doi.org/10.1002/1097-](https://doi.org/10.1002/1097-0142(19900215)65:4<1041::AID-CNCR2820650433>3.0.CO;2-A)
748 [0142\(19900215\)65:4<1041::AID-CNCR2820650433>3.0.CO;2-A](https://doi.org/10.1002/1097-0142(19900215)65:4<1041::AID-CNCR2820650433>3.0.CO;2-A).

- 749 [88] Sloas MM, Flynn PM, Kaste SC, Patrick CC. Typhlitis in Children with Cancer: A 30-
750 Year Experience. *Clinical Infectious Diseases* 1993;17:484–90.
751 <https://doi.org/10.1093/clinids/17.3.484>.
- 752 [89] Jain Y, Arya LS, Kataria R. NEUTROPENIC ENTEROCOLITIS IN CHILDREN
753 WITH ACUTE LYMPHOBLASTIC LEUKEMIA. *Pediatric Hematology and Oncology*
754 2000;17:99–103. <https://doi.org/10.1080/088800100276712>.
- 755 [90] Pastore D, Specchia G, Mele G, Montagna MT, Margari A, Carluccio P, et al.
756 Typhlitis Complicating Induction Therapy in Adult Acute Myeloid Leukemia. *Leukemia &*
757 *Lymphoma* 2002;43:911–4. <https://doi.org/10.1080/104281902900171105>.
- 758 [91] Hogan WJ, Letendre L, Litzow MR, Tefferi A, Hoagland HC, Pruthi RK, et al.
759 Neutropenic Colitis After Treatment of Acute Myelogenous Leukemia With Idarubicin and
760 Cytosine Arabinoside. *Mayo Clinic Proceedings* 2002;77:760–2.
761 <https://doi.org/10.4065/77.8.760>.
- 762 [92] McCarville MB, Adelman CS, Li C, Xiong X, Furman WL, Razzouk BI, et al.
763 Typhlitis in childhood cancer. *Cancer* 2005;104:380–7. <https://doi.org/10.1002/cncr.21134>.
- 764 [93] Alioglu B, Avci Z, Ozcay F, Arda S, Ozbek N. Neutropenic Enterocolitis in Children
765 with Acute Leukemia or Aplastic Anemia. *International Journal of Hematology* 2007;86:364–
766 8. <https://doi.org/10.1532/IJH97.E0739>.
- 767 [94] Mullassery D, Bader A, Battersby AJ, Mohammad Z, Jones ELL, Parmar C, et al.
768 Diagnosis, incidence, and outcomes of suspected typhlitis in oncology patients—experience
769 in a tertiary pediatric surgical center in the United Kingdom. *Journal of Pediatric Surgery*
770 2009;44:381–5. <https://doi.org/10.1016/j.jpedsurg.2008.10.094>.
- 771 [95] Rizzatti M, Brandalise SR, Azevedo AC de, Pinheiro VRP, Aguiar S dos S.
772 NEUTROPENIC ENTEROCOLITIS IN CHILDREN AND YOUNG ADULTS WITH
773 CANCER: Prognostic Value of Clinical and Image Findings. *Pediatric Hematology and*

- 774 Oncology 2010;27:462–70. <https://doi.org/10.3109/08880018.2010.489934>.
- 775 [96] Li K, Zheng S, Dong K, Gao Y, Wang H, Liu G, et al. Diagnosis and outcome of
776 neutropenic enterocolitis: experience in a single tertiary pediatric surgical center in China.
777 Pediatric Surgery International 2011;27:1191–5. <https://doi.org/10.1007/s00383-011-2938-9>.
- 778 [97] Altinel E, Yarali N, Isik P, Bay A, Kara A, Tunc B. Typhlitis in Acute Childhood
779 Leukemia. Medical Principles and Practice 2012;21:36–9. <https://doi.org/10.1159/000331587>.
- 780 [98] Sundell N, Boström H, Edenholm M, Abrahamsson J. Management of neutropenic
781 enterocolitis in children with cancer: Typhlitis in paediatric oncology patients. Acta
782 Paediatrica 2012;101:308–12. <https://doi.org/10.1111/j.1651-2227.2011.02465.x>.
- 783 [99] Shafey A, Ethier M-C, Traubici J, Naqvi A, Sung L. Incidence, Risk Factors, and
784 Outcomes of Enteritis, Typhlitis, and Colitis in Children With Acute Leukemia: Journal of
785 Pediatric Hematology/Oncology 2013;35:514–7.
786 <https://doi.org/10.1097/MPH.0b013e31829f3259>.
- 787 [100] Aksoy DY, Tanriover MD, Uzun O, Zarakolu P, Ercis S, Ergüven S, et al. Diarrhea in
788 neutropenic patients: a prospective cohort study with emphasis on neutropenic enterocolitis.
789 Annals of Oncology 2007;18:183–9. <https://doi.org/10.1093/annonc/mdl337>.
- 790

791 **FIGURE LEGENDS**

792

793 **Figure 1: Suspected pathophysiology for neutropenic enterocolitis.**

794

795 **Figure 2: Contrast enhanced abdominal CT-scans of neutropenic enterocolitis.**

796 Fig 2A: Segmental bowel wall thickening (➔) with mucosal enhancement of the duodenum and the jejunum. a)

797 Cross section (> 4mm) b) Longitudinal section (>30mm).

798 Fig 2B: Parietal pneumatosis (➔) with mucosal enhancement involving the entire digestive tract and no arterial
799 thrombosis.

800 Fig 2C: Peritoneal effusion (➔) with bowel wall thickening and mucosal enhancement.

801

802 **Figure 3: Nesher and Rolston diagnostic criteria [52] and suggested microbiologic tests**
803 **to exclude differential diagnosis.**

804 Enteric PCR panels should include *Norovirus*, *Rotavirus*, *Adenovirus*, *human Astrovirus*, *Sapovirus*, *Salmonella*
805 *spp.*, *Yersinia enterocolitica*, *Shigella spp. Enterotoxigenic* and *Shiga toxin-producing Escherichia coli*,
806 *Campylobacter spp.*, *Plesiomonas shigelloides*, and *Vibrio spp.* aGvHD-GI: Gastrointestinal acute graft versus
807 host disease. EVA: verbal rating scale. CMV: Cytomegalovirus. GI: gastrointestinal. IBD: Inflammatory Bowel
808 Diseases. PCR: polymerase chain reaction. qPCR: quantitative polymerase chain reaction.

809

810 **Figure 4: Histopathological observations.**

811 Hematoxylin and eosin stain.

812 X5 scanning magnification (Fig 4A and 4B), and X10 scanning magnification (Fig 4C).

813 Fig 4A: Extensive coagulative mucosal necrosis with intramural hemorrhage (*).

814 Fig 4B: Extensive coagulative mucosal necrosis with submucosal edema (**). Paucity of inflammatory cells
815 infiltrate.

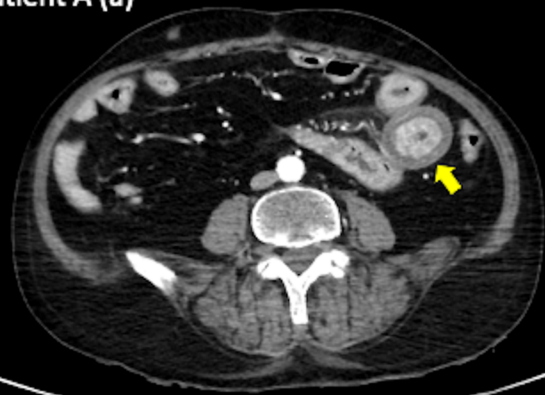
816 Fig 4C: Necrotic colonic glands (†) and congestive vessels (‡).

817

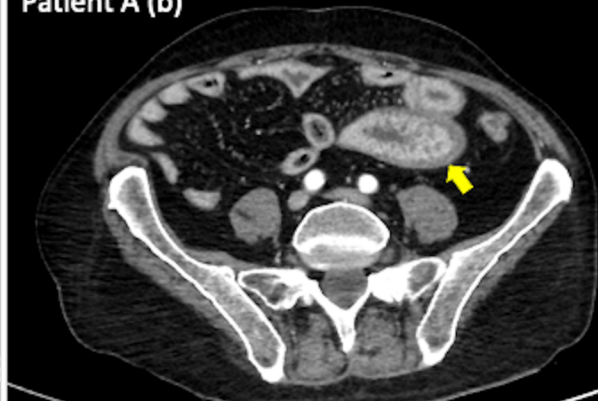
818 **Figure 5: Proposed therapeutic management for neutropenic enterocolitis.**

819 G-CSF: hematopoietic growth factor. US: ultrasound.

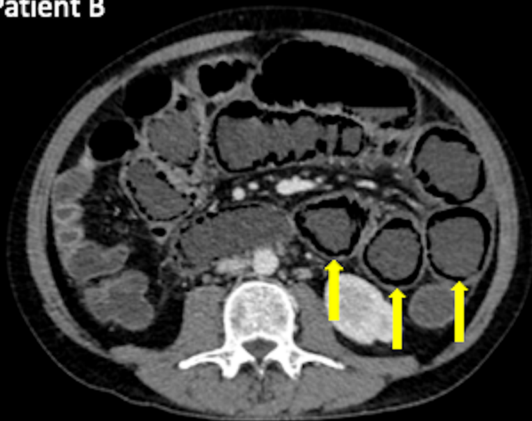
Patient A (a)



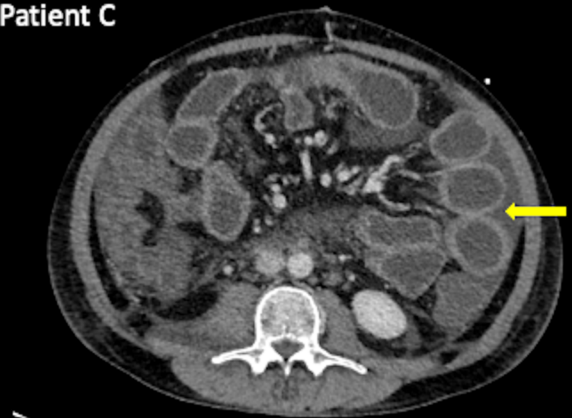Patient A (b)



Patient B



Patient C



Major Criteria	
	<ul style="list-style-type: none"> ➤ Severe neutropenia less than $500 \cdot 10^9$ neutrophils/L ➤ Fever exceeding 38.3°C (oral or rectal) ➤ Thickening of the intestinal wall (CT-scan or ultrasound) > 4mm (cross-section) and > 30mm (longitudinal)
Minor Criteria	
	<ul style="list-style-type: none"> ➤ Severe abdominal pain (EVA > 3/10) ➤ Abdominal distension ➤ Abdominal cramps ➤ Diarrhea ➤ Lower GI bleeding

aGvHD-GI
 Radiation-induced enterocolitis
 Exacerbation of IBD
 Mesenteric ischemia

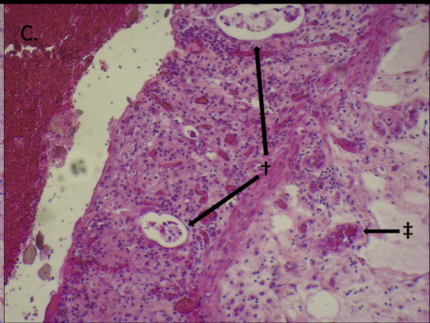
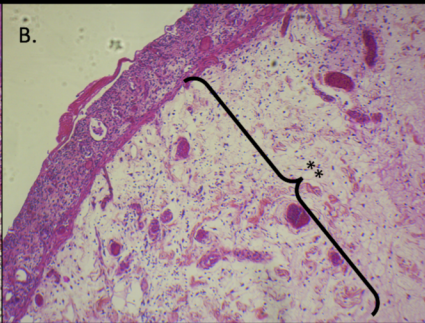
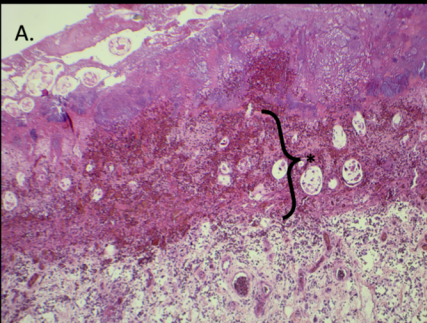
Infectious colitis

Stool Tests
<ul style="list-style-type: none"> ➤ Stool culture ➤ Toxigenic Clostridium Difficile detection ➤ Bacterial and viral enteric PCR panels ➤ Parasitological stool examination
Blood Tests
<ul style="list-style-type: none"> ➤ qPCR CMV ➤ qPCR Mucormycosis ➤ Aspergillus Galactomannan Antigen

Neutropenic enterocolitis

(+)

(-)



Neutropenic enterocolitis Therapeutic Management

→ G-CSF

→ Transfusion support

- Platelet count > 50G/L
- Fibrinogen level > 1.5g/L
- Prothrombin time > 40%

→ Empiric Antibiotherapy

- 1) Penicillin active against *Pseudomonas spp*
- 2) Antibiotic active against Gram-positive cocci
- 3) Antianaerobic

Radiologically assessed enteritis
(US or CT scan)

Refractory hemodynamic
instability
(high doses vasopressors)

- Perforation
- Enteral and/or colic necrosis
- Gastrointestinal bleeding
- Fistula
- Abscess

→ Empiric Antifungal therapy
active against *Candida spp*

→ Surgery

Article	Inclusion period	Population	Underlying pathology	Diagnostic criteria	Prevalence (%)	Mortality (%)
Onco-hematologic population						
Steinberg et al. 1973 [85]	1969-1971	Adults	Hematology	Histologic	12.0	NC
Moir et al. 1976 [4]	1968-1975	Child	Hematology	Histologic	46.0	NC
Shamberger et al. 1986 [84]	1976-1984	Child	AML	Clinic	32.5	8.00
Mower et al. 1986 [86]	1962-1985	Adults	AL	Histologic	2.60	NC
Katz et al. 1990 [87]	1970-1987	Child	AL	Histologic	24.0	NC
Sloas et al. 1993 [88]	1962-1992	Child	Oncology	Clinico-radiologic	0.35	8.30
Jain et al. 2000 [89]	1990-1995	Child	ALL	Clinic	6.10	4.00
Cartoni et al. 2001 [47]	1995-1998	Adults	Hematology	Clinico-radiologic	2.60	29.5
Pastore et al. 2002 [90]	1999-2000	Adults	AML	Clinic	4.30	28.5
Hogan et al. 2002 [91]	1997-1998	Adults	AML	Clinico-radiologic	15.0	40.0
McCarville et al. 2005 [92]	1990-2001	Child	Oncology	Radiologic	2.60	2.40
Alioglu et al. 2007 [93]	1997-2006	Child	AL and AA	Clinic	9.30	NC
Moran et al. 2009 [25]	1995-2005	Child	Oncology	Clinico-radiologic	5.00	0.00
Mullassery et al. 2009 [94]	2001-2005	Child	Oncology	Clinico-radiologic	6.10	2.50
Rizzatti et al. 2010 [95]	2003-2007	Child	Oncology	Clinico-radiologic	16.2	11.7
El Matary et al. 2011 [20]	1988-2008	Child	Oncology	Clinico-radiologic	0.22	11.0
Li et al. 2011 [96]	2000-2009	Child	Oncology	Clinico-radiologic	2.50	8.30
Altinel et al. 2012 [97]	2006-2009	Child	AL	Clinico-radiologic	13.3	20.0
Sundell et al. 2012 [98]	1995-2006	Child	Oncology	Clinico-radiologic	1.70	0.00
Shafey et al. 2013 [99]	1999-2088	Child	AL	Radiologic	8.50	3.90
Gil et al. 2013 [5]	2006-2010	Adults	HSCT	Clinico-radiologic	12.0	9.60
Pugliese et al. 2017 [50]	2002-2012	Adults	AML	Clinico-radiologic	23.8	23.0
User et al. 2018 [43]	2011-2017	Child	AL	Clinico-radiologic	6.40	30.0
Seddon et al. 2018 [21]	2009-2013	Adults	AML	Clinico-radiologic	37.6	0.00
Neutropenic populations						
Biasoli et al. 1997 [76]	1987-1996	Adults	FN	Clinic	2.00	80.0
Gorschluter et al. 2002 [48]	2001	Adults	Neutropenia	Clinico-radiologic	6.50	50.0
Aksoy et al. 2007 [100]	2001-2003	Adults	Neutropenia	Clinico-radiologic	5.10	18.2
Badgwell et al. 2008 [28]	2000-2006	Adults	Neutropenia Acute Abdomen	Clinico-radiologic	28.0	47.0
Vogel et al. 2010 [51]	2003-2009	Adults	Neutropenia	Clinico-radiologic	7.00	26.0

Table 1: All cohort studies indicating the prevalence and mortality rate of neutropenic enterocolitis in onco-hematologic patients and neutropenic patients.

AML: Acute myeloid leukemia; AL: Acute leukemia; AA: Aplastic anemia; HSCT: Human stem-cell transplantation; FN: Febrile neutropenia; ICU: Intensive care unit.

Table 2: Chemotherapeutic agents that have been associated with neutropenic enterocolitis

Topoisomerase inhibitors	Anthracyclines (daunorubicin, doxorubicin, idarubicin, epirubicin and mitoxantrone) Irinotecan Etoposide
Microtubule inhibitors	Taxanes Vinca alkaloids
Antimetabolite agents	Pemetrexed Cytarabine Gemcitabine 5-fluorouracil and capecitabine its pro-drug
Alkylants	Cyclophosphamide Ifosfamide Platinum-based chemotherapy

Table 3: Proposition for empirical antibiotherapy in neutropenic enterocolitis

Gram-negative bacilli: - Pseudomonas spp. - Enterobacteria	Penicillin: - Piperacillin-tazobactam Cephalosporin: - Ceftazidime - Cefepime Carbapenem: - Meropenem - Imipenem
Anaerobes	Nitroimidazoles (if cephalosporin is selected) - Metronidazole - Ornidazole
Gram-positive Cocci: - Streptococcus spp. - Enterococcus spp. - Staphylococcus spp.	Glycopeptides: - Vancomycin - Teicoplanin Daptomycin Linezolid
Fungi: - Candida spp.	Echinocandins Fluconazole