



HAL
open science

Aerococcus urinae infection of the pubic symphysis: A rare case report

Camille Langbour, Sara Mahmoud, François Coustillères, Marie-Frédérique Lartigue, Jessica René

► **To cite this version:**

Camille Langbour, Sara Mahmoud, François Coustillères, Marie-Frédérique Lartigue, Jessica René. Aerococcus urinae infection of the pubic symphysis: A rare case report. *IDCases*, 2023, 34, pp.e01911. 10.1016/j.idcr.2023.e01911 . hal-04415121

HAL Id: hal-04415121

<https://hal.inrae.fr/hal-04415121v1>


Submitted on 24 Jan 2024

HAL is a multi-disciplinary open access archive for the deposit and dissemination of scientific research documents, whether they are published or not. The documents may come from teaching and research institutions in France or abroad, or from public or private research centers.

L'archive ouverte pluridisciplinaire **HAL**, est destinée au dépôt et à la diffusion de documents scientifiques de niveau recherche, publiés ou non, émanant des établissements d'enseignement et de recherche français ou étrangers, des laboratoires publics ou privés.



Distributed under a Creative Commons Attribution - NonCommercial - NoDerivatives 4.0 International License



Case report

***Aerococcus urinae* infection of the pubic symphysis: A rare case report**Camille Langbour^a, Sara Mahmoud^a, François Coustillères^b, Marie-Frédérique Lartigue^{c,d}, Jessica René^{a,e,*}^a CHU Tours, Service Rhumatologie, 37170 Chambray-les-Tours, France^b CHU Tours, Service Médecine Interne et Maladies Infectieuses, 37000 Tours, France^c CHU Tours, Service de Bactériologie-Virologie-Hygiène, F-37044 Tours, France^d ISP, UMR1282, Université de Tours, INRAE, F-37032 Tours, France^e Université François Rabelais de Tours, 37000 Tours, France

ARTICLE INFO

Keywords:

Septic arthritis
Aerococcus urinae
Pubic symphysis
Osteomyelitis

ABSTRACT

Aerococcus urinae is a Gram-positive, catalase-negative coccus, rarely responsible for urinary tract infections and seldom described for musculoskeletal infections like spondylodiscitis. An 86-year-old man presented to our hospital for groin pain without fever. Pelvic CT-guided biopsy revealed an *A. urinae* pubic symphysis osteomyelitis. He received a treatment by amoxicillin *per os* for six weeks, and did not need any surgery. An eight-month follow-up showed a favorable evolution.

Pubic symphysis infection can be induced by a wide variety of pathogens, and may have very different clinical presentations. Some authors recommend systematic surgery, but in case of susceptible pathogen associated with a low level of joint destruction, medical treatment alone should be sufficient to cure and make surgery unnecessary.

Background

Pubic symphysisitis is a rare infection that leads to severe pain and lameness. Four major risk factors were described: women recently having undergone surgery for urinary incontinence, athletes, patients with pelvic malignancies, and intravenous drug users. Clinical presentations are heterogeneous, but the most common symptoms are pubic and groin pains. Fever is present in the majority of cases, but not all. The serum white blood count (WBC) is normal in 65 % of cases. Microbiological diagnosis can be challenging because it presents a great diversity of the pathogens involved. The most common ones are *Staphylococcus aureus* (6–34 %), *Pseudomonas aeruginosa* (10–24 %), *Candida* spp. (22 %), *Enterococcus* spp. (5–18 %) [1,2]. Polymicrobial infections are also frequent. According to some authors, treatment should include prolonged antibiotherapy and systematic surgical debridement.

Aerococcus urinae is a Gram-positive, α -hemolytic, catalase-negative, facultative anaerobic coccus, which can be an uncommon cause of urinary tract infection, isolated in 0.2–0.8 % of all urinary cultures [1]. Of note, misidentified as a contaminant for years by the use of biochemical techniques, and previously considered as a contaminant, the species is now well recognized and known as potentially causing invasive

infections. It mostly affects elderly men (> 65 years old) with underlying urinary tract disease, particularly those with a urinary tract catheter [3, 4], leading even to bacteremia [5,6] and endocarditis [7,8] in rare cases. Musculoskeletal infections due to this pathogen, mostly spondylodiscitis, have also rarely been described [9,10].

We will, thereby, report a unusual case of pubic symphysisitis due to *A. urinae* in an 86-year-old patient, cured by medical treatment only. Then, we will discuss the relationship between urinary tract infection and pubic symphysisitis, and the global management of these infections.

Case presentation

An 86-year-old French man presented to the emergency department with left groin soreness associated to progressive lameness that had started one month before. His medical history included an ischemic cardiomyopathy, non-insulin dependent (type II) diabetes mellitus, monoclonal gammopathy of undetermined significance (MGUS) and bladder sphincter stenosis that had led to the introduction of indwelling urinary catheter three years before. His catheter was changed regularly, about every two months. He was a retired mason, living at home, still autonomous and walked with no aid device. He had stopped smoking for

* Correspondence to: Service de Rhumatologie, CHU de Tours, 37170 Chambray-les-Tours, France.

E-mail address: jessica.rene@univ-tours.fr (J. René).<https://doi.org/10.1016/j.idcr.2023.e01911>

Received 13 January 2023; Received in revised form 11 October 2023; Accepted 12 October 2023

Available online 13 October 2023

2214-2509/© 2023 The Authors. Published by Elsevier Ltd. This is an open access article under the CC BY-NC-ND license (<http://creativecommons.org/licenses/by-nc-nd/4.0/>).

forty years and had no history of chronic alcoholism. The clinical examination showed that he was unable to walk, due to left hip pain (numerical rating scales 5/10) and limitation (abduction 30° vs. 45° for contralateral). Moreover, there was a sharp pain at the palpation of the pubic symphysis. There was no fever. Urines were clear, and he described no sign of past or present urinary catheter infection.

First, the biology showed an elevated C-reactive protein (CRP) at 54.4 mg/L that was not associated with hyperleukocytosis. The pelvis radiography did not reveal any fracture nor any lytic lesion. Concerning microbiological examination, blood cultures were sterile, and the cytobacteriologic examination of urine (CBEU) revealed leukocyturia (22,000/mL) and microscopic hematuria (977,000/mL), while urine culture was positive to *Enterococcus faecalis*. Computed Tomography (CT) of the pelvis (Fig. 1) revealed an osteolytic lesion of the cortical of the anteromedial part of the left pubic symphysis without any fracture. The distance between the two pubic branches was 16.21 mm. In addition, Magnetic Resonance Imaging (MRI) of the pelvis (Fig. 2) showed the presence of small abscessed collections in the soft parts, in particular within the left external obturator muscle (12 × 12 × 9 mm). There was no evidence for neoplasm and vesico-symphysial fistula was excluded according to the radiologist interpretation.

Secondly, we performed a pelvic symphysis CT-guided biopsy (sampling of 2 mL of joint fluid), and the culture became positive for *A. urinae* within three days (MALDI-TOF mass spectrometry, Bruker Daltonics GmbH®, Bremen, Germany; score >2). The strain was susceptible to penicillin G (Minimal Inhibitory Concentration, MIC = 0.064 mg/L), amoxicillin (MIC < 0.016 mg/L, E-Test Biomérieux®, Marcy-l'Étoile, France), levofloxacin and vancomycin.

The patient, thus, received an exclusive *per os* antibiotherapy with 6 g of amoxicillin (2 g tid) for six weeks. Urinary catheter was changed two days after the beginning of the antibiotics. After eight days of good clinical and biological evolution under antibiotic, the patient was discharged, and no surgery was necessary. One month later, pain had totally disappeared and he was able to walk again with no technical aid device. At last, another CT of the pelvis was performed at three months, which showed a good evolution with the disappearance of collections and no new osteolytic lesion (Fig. 3). The distance between the two pubic branches was 15.06 mm. The evolution was still favorable at eight-month- follow-up, with no element of recurrence.

Discussion

We describe above a rare case report of *A. urinae* pubic symphysis osteomyelitis. Only a few musculoskeletal infections due to this pathogen have been documented so far, but their number is increasing over the years, probably because *A. urinae* has been easier to identify since the introduction of MALDI-TOF MS in routine laboratories [11]. To our knowledge, only few cases of spondylodiscitis, one case of ankle arthritis [1], one of periarticular hip abscess [12] and one of prosthetic hip

infection [13] have been reported so far, in a recent case-based review [1]. We also found few cases of pubic symphysis osteomyelitis due to *A. urinae*, but with no further description [14–16]. Thus, this is the first published and detailed case report about this kind of infection due to this microorganism. Nosé et al. notably mentioned four different cases of *A. urinae* pubic bone infection associated to urinary-pubic symphysis fistulae, emphasizing both the ability of *A. urinae* to colonize the urinary tract, and the anatomical proximity of these two sites. Thus, finding *A. urinae* as a pathogen of pubic symphysis osteomyelitis is not incongruous. Interestingly enough, an initial urinary tract contamination may occur in most situations before bone and joint infection or endocarditis due to *A. urinae*. However, for spondylodiscitis and endocarditis, the distant infection site is explained by subsequently blood and systemic infection, whereas symphysis joint and bone infection is more likely to be induced by a loco-regional translocation. Thus, patients with urinary tract specific conditions might logically be more vulnerable [15], and in these cases, we think that the hypothesis of urinary-pubic symphysis fistulae should always be considered. As refer to our patient, I suspect that catheter exchange could not be sufficiently traumatic to cause fistulae across local tissue planes to the pubic symphysis. But the resulting uroepithelial trauma could translocate pathogens into blood, and thus act as a hematogenous source [17]. A direct urinary source is commonly observed from radiation-induced or trauma-induced fistulae to the pubic symphysis. Interestingly, transient bacteremia from the urologic tract into Batson's venous plexus has been postulated as a source of vertebral osteomyelitis, in addition to arterial sources. Whether that can be proven is debatable, but pelvic lymphatic return should not involve the symphysis if the anatomy is normal. The relationship of bacteriuria in the setting of pubic symphysis is also debatable, since asymptomatic bacteriuria is common in the setting of a bladder catheter. This case report, as the authors attest, demonstrates the value of diagnostic aspiration or biopsy for cultures, rather than attributing the source to the flora cultured from urine. In some cases of symphysis due to vesical fistula [15], the pathogen can be identified both in the urine and bone biopsy. In what refers to the case we reported, only *E. faecalis* was found in the urine culture, which might have hidden the presence of *A. urinae* if we hadn't make any further analysis. Therefore, bone biopsies or surgical samples should always be made, because indeed, urine may be contaminated without any correlation with the pathogens identified in the joint [16].

A. urinae is usually treated with a β -lactam, using penicillin for less severe cases or penicillin associated with gentamicin for more severe cases [18]. Vancomycin can be used if there is a β -lactam allergy. In fact, this pathogen is very susceptible to antibiotics, especially β -lactams and glycopeptides. It has a low level of resistance to aminoglycosides and resistance to sulfonamides. For pubic symphysis osteomyelitis, a review of a hundred cases revealed an average 54 days long antibiotic therapy (more than half of the duration of intravenous treatment), associated with surgical management for about half of the cases [2]. Some authors recommend systematic surgical debridement [14,19], although no comparative study has been published yet, and in many case series reports, all patients underwent surgery [15,18,19]. However, global prognosis with medical treatment only seems to be good, with full recovery and no relapse in most medically managed cases [2]. Our patient has had an excellent outcome, with fast improvement and no relapse despite the sole medical management. We assume that in cases of easy-to-treat pathogen, low inoculum without large abscess, and no or very low joint destruction level, medical treatment only should be enough, and that surgery should be considered only in complex situations or in case of medical management failure.

Consent

Obtained.

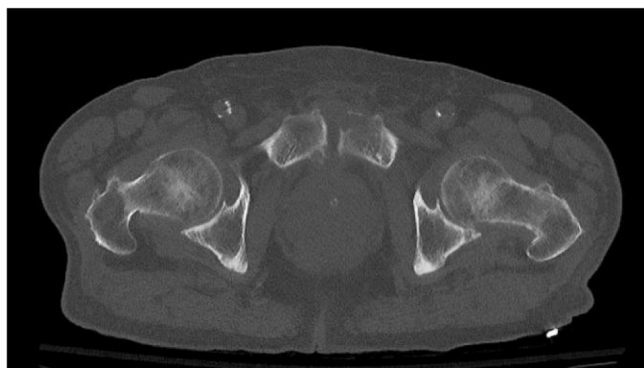


Fig. 1. Osteolytic lesion of the cortical of the anteromedial part of the left pubic symphysis in the initial CT-scanner.

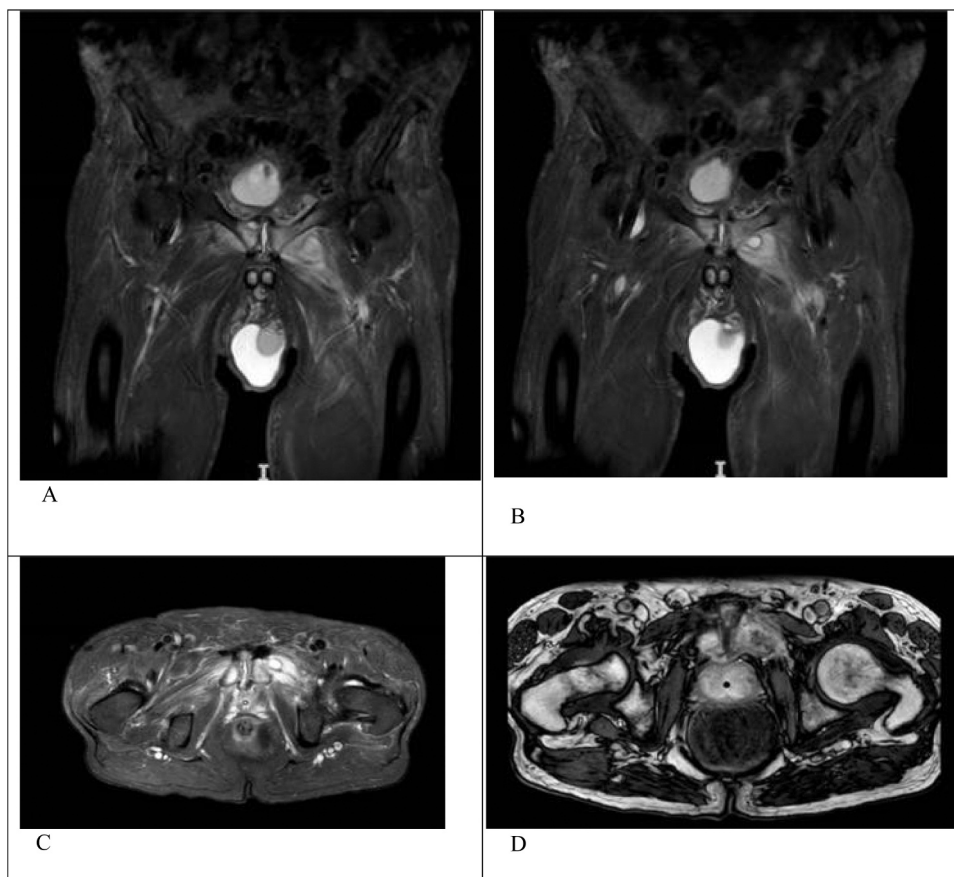


Fig. 2. A. Subchondral abscess on a coronal section MRI. B. Abscessed collection of the left obturator muscle on a coronal section MRI. C. Abscesses on an axial section on T2 MRI. D. Abscesses on an axial section on T1 MRI.

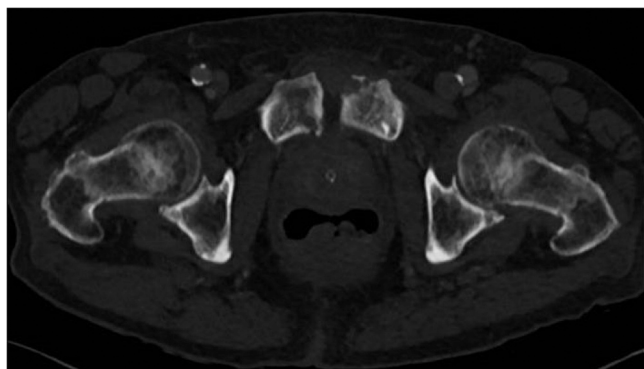


Fig. 3. Favorable evolution of symphysis osteomyelitis on a CT-scan performed two months after antimicrobial therapy initiation.

CRediT authorship contribution statement

Camille Langbour: data collections, writing. **Sara Mahmoud:** data collections, writing. **François Coustillères:** writing. **Marie-Frédérique Lartigue:** data collections, writing. **Jessica René:** data collections, writing.

Conflicts of interest

None.

Acknowledgements

The authors would like to acknowledge the efforts of the laboratory technicians, especially Dr Hugo Langris, microbiologist, and Dr Loïc Bouilleau, the radiologist who performed the CT-guided biopsy, and Mrs Catherine Dalloz for correction of syntax and spelling in English language.

References

- [1] Greco M, et al. Musculoskeletal infections caused by *Aerococcus urinae*: a case-based review. *Clin Rheumatol* 2018;37:2587–94.
- [2] Ross JJ, Hu LT. Septic arthritis of the pubic symphysis: review of 100 cases. *Medicine* 2003;82:340–5.
- [3] Sahu KK, Lal A, Mishra AK, Abraham GM. *Aerococcus*-related infections and their significance: a 9-year retrospective study. *J Microsc Ultrastruct* 2021;9:18–25.
- [4] Higgins A, Garg T. *Aerococcus urinae*: an emerging cause of urinary tract infection in older adults with multimorbidity and urologic cancer. *Urol Case Rep* 2017;13: 24–5.
- [5] Jost C, et al. First case of pregnant women bacteraemia and probable early-onset neonatal infection due to *Aerococcus urinae*. *N Microbes N Infect* 2015;3:1–3.
- [6] Serephanoglu K, Turan H, Dogan R, Gullu H, Arslan H. A case of *Aerococcus urinae* septicemia: an unusual presentation and severe disease course. *Chin Med J (Engl)* 2005;118:1318–20.
- [7] Ebnöther C, Altwegg M, Gottschalk J, Seebach JD, Kronenberg A. *Aerococcus urinae* endocarditis: case report and review of the literature. *Infection* 2002;30: 310–3.
- [8] Allegre S, Deyi Miendje, Beyer VY, Pepersack, T I, Cherifi S. *Aerococcus urinae* endocarditis: first case report in Belgium and review of the literature. *Rev Med Brux* 2008;29:568–71.
- [9] Lyagoubi A, Souffi C, Baroiller V, Vallee E. *Aerococcus urinae* spondylodiscitis: an increasingly described localization. *EJIFCC* 2020;31:169–73.
- [10] Astudillo L, et al. Spondylodiscitis due to *Aerococcus urinae*: a first report. *Scand J Infect Dis* 2003;35:890–1.
- [11] Degroote E, Yildiz H, Lecouvet F, Verroken A, Belkhir L. *Aerococcus urinae*: an underestimated cause of spine infection? Case report and review of the literature. *Acta Clin Belg* 2018;73:444–7.

- [12] Goetz LL, et al. Hip abscess due to *Aerococcus urinae* in a man with paraplegia: case report. *Spinal Cord* 2013;51:929–30.
- [13] Opota O, et al. Diagnosis of *Aerococcus urinae* infections: Importance of matrix-assisted laser desorption ionization time-of-flight mass spectrometry and broad-range 16S rDNA PCR. *Clin Microbiol Infect Publ Eur Soc Clin Microbiol Infect Dis* 2016;22:e1–2.
- [14] Devlieger B, Wagner D, Hopf J, Rommens PM. Surgical debridement of infected pubic symphysis supports optimal outcome. *Arch Orthop Trauma Surg* 2021;141:1835–43.
- [15] Nosé BD, et al. Extirpative cultures reveal infectious pubic bone osteomyelitis in prostate cancer survivors with urinary-pubic symphysis fistulae (UPF). *Urology* 2020;142:221–5.
- [16] Shu HT, Elhessy AH, Conway JD, Burnett AL, Shafiq B. Orthopedic management of pubic symphysis osteomyelitis: a case series. *J Bone Jt Infect* 2021;6:273–81.
- [17] Ambrosini F, Zegna L, Testino N, Vecchio E, Mantica G, Suardi N, et al. Management of osteomyelitis of the pubic symphysis following urinary fistula in patients with radiation-induced urethral strictures after prostate cancer treatment. *Cent Eur J Urol* 2022;75(3):284–9.
- [18] de Vries TW, Brandenburg AH. Foul smelling urine in a 7-year-old boy caused by *Aerococcus urinae*. *Pediatr Infect Dis J* 2012;31:1316–7.
- [19] Hansen RL, Bue M, Borgognoni AB, Petersen KK. Septic arthritis and osteomyelitis of the pubic symphysis - a retrospective study of 26 patients. *J Bone Jt Infect* 2022; 7:35–42.