



HAL
open science

Pros and cons of internal limiting membrane peeling during epiretinal membrane surgery: a randomised clinical trial with microperimetry (PEELING)

Jean-Baptiste Ducloyer, Yannick Eude, Christelle Volteau, Olivier Lebreton, Alexandre Bonissent, Paul Fossum, Ramin Tadayoni, Catherine Creuzot-Garcher, Yannick Le Mer, Julien Perol, et al.

► To cite this version:

Jean-Baptiste Ducloyer, Yannick Eude, Christelle Volteau, Olivier Lebreton, Alexandre Bonissent, et al.. Pros and cons of internal limiting membrane peeling during epiretinal membrane surgery: a randomised clinical trial with microperimetry (PEELING). *British Journal of Ophthalmology*, 2024, pp.bjo-2023-324990. 10.1136/bjo-2023-324990 . hal-04667620

HAL Id: hal-04667620

<https://hal.inrae.fr/hal-04667620v1>

Submitted on 5 Aug 2024

HAL is a multi-disciplinary open access archive for the deposit and dissemination of scientific research documents, whether they are published or not. The documents may come from teaching and research institutions in France or abroad, or from public or private research centers.

L'archive ouverte pluridisciplinaire **HAL**, est destinée au dépôt et à la diffusion de documents scientifiques de niveau recherche, publiés ou non, émanant des établissements d'enseignement et de recherche français ou étrangers, des laboratoires publics ou privés.



Distributed under a Creative Commons Attribution - NonCommercial 4.0 International License



OPEN ACCESS

Clinical science

Pros and cons of internal limiting membrane peeling during epiretinal membrane surgery: a randomised clinical trial with microperimetry (PEELING)

Jean-Baptiste Ducloyer ,^{1,2} Yannick Eude,¹ Christelle Volteau,³ Olivier Lebreton,¹ Alexandre Bonissant,¹ Paul Fossum,¹ Ramin Tadayoni,⁴ Catherine P Creuzot-Garcher,⁵ Yannick Le Mer,⁶ Julien Perol,⁷ June Fortin,³ Alexandra Jobert,³ Fanny Billaud,^{1,2} Catherine Ivan,^{1,2} Alexandra Poinas,² Michel Weber,^{1,2} for the CFSR Research Net

► Additional supplemental material is published online only. To view, please visit the journal online (<https://doi.org/10.1136/bjo-2023-324990>).

For numbered affiliations see end of article.

Correspondence to

Dr Jean-Baptiste Ducloyer, CHU Nantes Department of Ophthalmology, Nantes University, Nantes, France; jeanbaptiste.ducloyer@chu-nantes.fr

Part of these data were presented at the "Société Française d'Ophthalmologie" congress on May 6, 2023.

Received 29 November 2023
Accepted 2 June 2024

ABSTRACT

Background After idiopathic epiretinal membrane (iERM) removal, it is unclear whether the internal limiting membrane (ILM) should be removed. The objective was to assess if active ILM peeling after iERM removal could induce microscotomas.

Methods The PEELING study is a national randomised clinical trial. When no spontaneous ILM peeling occurred, patients were randomised either to the ILM peeling or no ILM peeling group. Groups were compared at the month 1 (M1), M6 and M12 visits in terms of microperimetry, best-corrected visual acuity (BCVA) and optical coherence tomography findings. The primary outcome was the difference in microscotoma number between baseline and M6.

Results 213 patients were included, 101 experienced spontaneous ILM peeling and 100 were randomised to the ILM peeling (n=51) or no ILM peeling group (n=49). The difference in microscotoma number between both groups was significant at M1 (3.9 more microscotomas in ILM peeling group, (0.8;7.0) p=0.0155) but not at M6 (2.1 more microscotomas in ILM peeling group (-0.5;4.7) p=0.1155). Only in the no ILM peeling group, the number of microscotomas significantly decreased and the mean retinal sensitivity significantly improved. The ERM recurred in nine patients in the no ILM peeling group (19.6%) versus zero in the ILM peeling group (p=0.0008): two of them underwent revision surgery. There was no difference in mean BCVA and microperimetry between patients experiencing or not a recurrence at M12.

Conclusion Spontaneous ILM peeling is very common. Active ILM peeling prevents anatomical ERM recurrence but may induce retinal impairments and delay visual recovery.

Trial Registration [NCT02146144](https://clinicaltrials.gov/ct2/show/study/NCT02146144).

INTRODUCTION

Idiopathic epiretinal membrane (ERM) is a common age-related degenerative condition that can result in visual impairment.¹ Symptomatic ERM may be surgically removed by vitrectomy and ERM peeling using a microforceps. As the internal limiting membrane (ILM) is adherent to the ERM, spontaneous ILM peeling may occur. When the ILM is not

WHAT IS ALREADY KNOWN ON THIS TOPIC

⇒ Internal limiting membrane (ILM) peeling decreases the risk of postoperative epiretinal membrane (ERM) recurrence, does not modify the postoperative best-corrected visual acuity (BCVA) and alters the retinal anatomy. Very few microperimetry data are available and spontaneous ILM cases were not taken into account in previous randomised clinical trial.

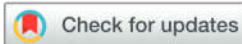WHAT THIS STUDY ADDS

⇒ During ERM peeling with Eckardt microforceps, spontaneous ILM peeling was very common (50%). Anatomical ERM recurrence was drastically lower with active ILM peeling (0%) than without any ILM peeling (19.6%): the rate of surgical revision was 4% and visual outcomes with or without recurrent ERM were similar. Besides, active ILM peeling was associated with anatomical retinal damages and a delayed visual recovery in terms of BCVA and microperimetry.

HOW THIS STUDY MIGHT AFFECT RESEARCH, PRACTICE OR POLICY

⇒ After ILM peeling with Eckardt microforceps, microscotomas can appear, linked or not to the point of ILM pinch. To peel or not to peel the ILM after ERM removal remains an open question, and every surgeon needs to keep the pros and cons in mind.

spontaneously peeled off, whether or not surgeons should deliberately remove it remains controversial. As active ILM peeling does not improve the postoperative visual acuity, its only expected benefit is to decrease the risk of postoperative ERM recurrence.^{2,3} However, active ILM peeling is associated with adverse effects, including an extended operating time, increased surgical risks,^{4,5} a histological disorganisation of the retina⁶ and an alteration of the fibre layer on optical coherence tomography (OCT).⁷⁻⁹ Some retrospective studies have found that active ILM peeling can induce microscotomas detected on microperimetry.^{10,11} These



© Author(s) (or their employer(s)) 2024. Re-use permitted under CC BY-NC. No commercial re-use. See rights and permissions. Published by BMJ.

To cite: Ducloyer J-B, Eude Y, Volteau C, et al. *Br J Ophthalmol* Epub ahead of print: [please include Day Month Year]. doi:10.1136/bjo-2023-324990

microscotomas may explain the postoperative visual discomfort reported by some patients that is not detected when assessing the visual acuity and/or visual field.

The aim of the PEELING study was to assess if active ILM peeling could induce microscotomas by comparing the difference in microscotoma number between patients undergoing active ILM peeling versus no ILM peeling between baseline and 6 months after surgery.

METHODS

Design and intervention

The PEELING study was a prospective, randomised, two-arm, controlled, single-blind, multicentric clinical trial. The study design and methodology have been previously described in detail (online supplemental file 13).¹² On the day of surgery (D0), the interventions were performed by experienced senior surgeons as follows: phacoemulsification for all phakic eyes, central and peripheral vitrectomy (25 gauge), ERM dissection. Staining with MembraneBlue-Dual for 1 min was performed before ERM peeling and was performed a second time after ERM peeling to stain the ILM. If the ILM spontaneously peeled off on a surface with a diameter of at least two optic disc diameters, patients were not randomised and were included in an ancillary study. Otherwise, patients were randomised intraoperatively to the no ILM peeling group or to the ILM peeling group. In this last group, ILM peeling was performed only with Eckardt microforceps over an area of at least two optic disc diameters around the fovea, corresponding to a 'disc' of four optic disc diameters. At the end of the surgery, a periphery search for retinal breaks was performed. After surgery, three follow-up visits were performed at 1 month (M1), 6 months (M6) and 12 months (M12) by ophthalmologists and orthoptists who were blinded to the group assignment. The operative report did not mention whether the ILM was peeled off or not in order not to influence the orthoptists who performed the functional assessment and the patients. Patients were informed of the assigned group at the end of the study.

This clinical study was approved by a ethics committee on 02 April 2014 and by the French Health Authority (Agence Nationale de Sécurité du Médicament et des produits de santé) on 21 February 2014. The study was conducted in accordance with the good clinical practices, the tenets of the Declaration of Helsinki and the Consolidated Standards of Reporting Trials guidelines.¹³ All participants provided their written informed consent. Online supplemental file 13

Participants and sample size

Patients were enrolled in the five ophthalmology departments of Nantes University Hospital, Lariboisière University Hospital, Dijon University Hospital, Adolphe de Rothschild Eye Foundation, Saint Herblain private hospital (polyclinic of the Atlantic). The main inclusion criteria were: symptomatic idiopathic ERM resulting in a decrease in visual acuity and/or metamorphopsia, age ≥ 18 years. If both eyes required surgery, only the most affected eye was included in the study. Main exclusion criteria were: ocular comorbidity (age-related macular degeneration, retinal vein occlusion, diabetic retinopathy, glaucoma with macular visual field defect, uveitis or history of uveitis), any eye injury or eye surgery < 6 months before the study.

The sample size was set at 100 patients¹² with a power of 80% and a type I error of 5%, to highlight a halving of the number of microscotomas in the no ILM peeling group compared with the ILM peeling group (eg, mean number of 6 ± 6 microscotomas in

the ILM peeling group compared with 3 ± 4.6 microscotomas in the no ILM peeling).

Randomisation

An open-label randomisation was performed and patients were stratified according to the centre, using a 1:1 ratio and balanced by blocks, using SAS software V.9.4. The randomisation key was known only to the biostatistician and data managers.

Examinations and outcomes

The primary outcome was the difference in microscotoma number assessed by microperimetry (OPKO/OTI, Miami, USA) between before (baseline) and 6 months (M6) after surgery. The 'Ivana' protocol supervised by the ophthalmology department of Lariboisière hospital was used: retinal sensitivity is assessed at each of the 29 measurement points in the central 9° (centred on the fovea). Retinal sensitivity is better within 3° around the fixing point, with a mean foveal threshold of 20 dB and a 0.275 dB mean decrement for each 10°. Scotomas are defined as absolute (if the patient does not perceive the maximum stimulation, the sensitivity is 0 dB) or relative (retinal sensitivity < 10 dB).^{10 12}

As for microperimetry, the secondary outcome measures were assessed at each visit and included the best-corrected visual acuity (BCVA, ETDRS (Early Treatment Diabetic Retinopathy Study) scale), microscotoma number and types on microperimetry, the mean retinal sensitivity on microperimetry, a visual discomfort questionnaire completed by the patient, OCT findings (central macular thickness in the central 1000 μ m diameter area (CMT), pericentral macular thickness, peripapillary retinal nerve fibre layer thickness (pRNFL), swelling of the arcuate fibre layer (SANFL), dissociated optic nerve fibre layer (DONFL) and recurrence of ERM). If microscotomas appeared between baseline and M6, the surgical videos were reviewed by two independent ophthalmologists to determine whether the location of the new microscotomas correlated with a gripping area of the ERM or ILM.

Statistical analysis

Analyses were performed in the intention-to-treat population. The primary endpoint was compared between the two groups using a linear regression model adjusted for the preoperative number of microscotomas (the stratification according to the centre was not taken into account due to the insufficient number of patients in some centres). Multiple imputation was used for missing data with the predictive mean matching method on 20 imputed data sets.

Mixed linear regression models (taking into account repeated data measured over time) were used to compare the change in microscotoma number, mean retinal sensitivity, BCVA, CMT and RNFL between baseline and M12. Exploratory analyses were performed for the temporal, nasal, inferior and superior perifoveal sectors. The changes in visual symptoms, SANFL and DONFL were compared between both groups using logistic generalised linear mixed models for repeated measurements. The rate of ERM recurrence was compared between both groups using a Fisher's exact test.

A p value ≤ 0.05 was considered statistically significant. Statistical analyses were performed using SAS software, V.9.4 (SAS Institute).

RESULTS

Study population

Between September 2014 and January 2021, 213 patients were enrolled: 113 were not randomised (including 101 cases of

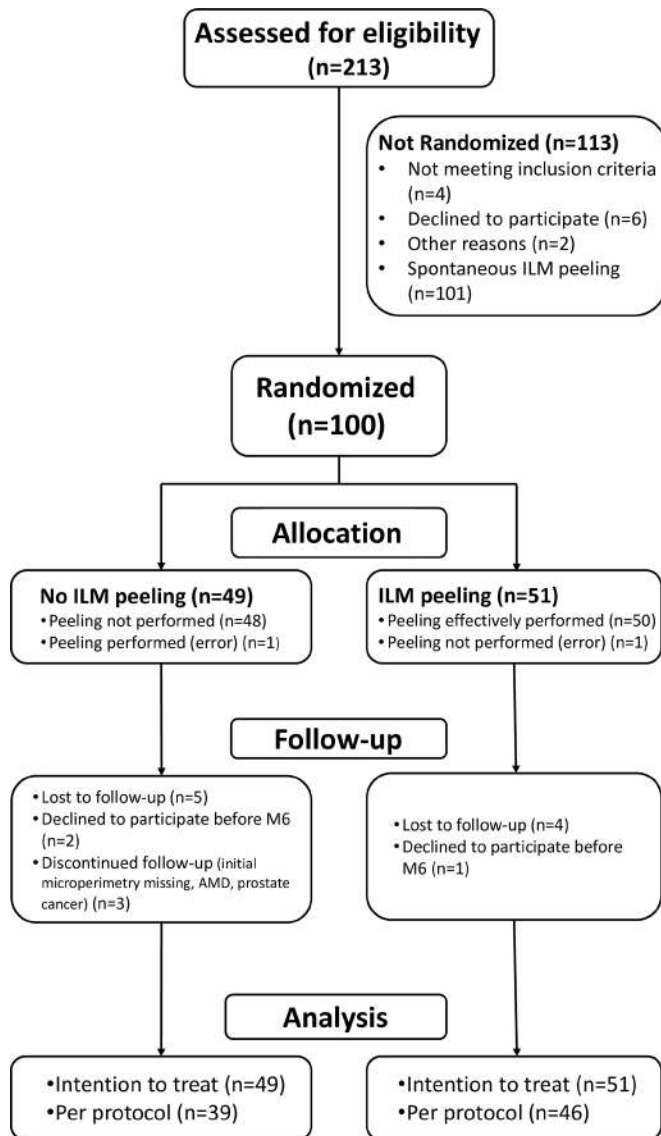


Figure 1 Study flowchart. AMD, age-related macular degeneration; ILM, internal limiting membrane.

spontaneous ILM peeling) and 100 were randomised intraoperatively (figure 1). Patients' mean age was 71 ± 7.6 years (table 1).

Microperimetry

Between baseline and M1, the difference in microscotoma number was significantly higher in the ILM peeling group than in the no ILM peeling group (mean difference: $+3.9$ (0.8; 7.0), $p=0.0155$) but the difference between the two groups was not significant at M6 ($+2.1$ (-0.5 ; 4.7), $p=0.1155$). Similarly, the difference in absolute microscotoma number baseline and M1 was significantly higher in the ILM peeling group ($+1.3$ (0.2; 2.5), $p=0.0210$) while it was not significant at M6 ($+0.8$ (-0.3 ; 1.8), $p=0.1653$) (figure 2). A significant reduction in the number of pre-existing microscotomas was observed in the no ILM peeling group between baseline and M12 (-3.5 (-6.5 ; -0.6), $p=0.0176$) while it was not observed in the ILM peeling group (-2.1 (-4.7 ; 0.4), $p=0.1$) (figure 2).

Similarly, the mean retinal sensitivity was significantly higher in the no ILM peeling group than in the ILM peeling group only at M1 ($+1.6$ (0.1; 3.1), $p=0.0357$) and a significant improvement in mean retinal sensitivity was observed in the no ILM peeling

Table 1 Baseline characteristics of randomised patients

Characteristics	ILM peeling group (N=51)	No ILM peeling group (N=49)	Total (N=100)
Female N (%)	34 (66.66)	25 (51.02)	59 (59)
Age mean (SD)	71.63 (8.37)	70.57 (6.68)	71.11 (7.57)
Right included eye N (%)	22 (43.14)	26 (53.06)	48 (48)
Patient's history N (%)			
Included eye's glaucoma	3 (5.88)	2 (4.08)	5 (5)
Diabetes	4 (7.84)	5 (10.20)	9 (9)
BCVA mean (SD)	69.25 (8.51)	70.00 (9.58)	69.62 (9.01)
Eye status			
Phakic	32 (62.75%)	39 (79.59%)	71 (71%)
Posterior vitreous detachment	24 (48.00%)	27 (56.25%)	51 (52.04%)
Intraretinal oedema	13 (25.49%)	12 (24.49%)	25 (25%)
Pseudo macular hole	5 (9.80%)	8 (16.33%)	13 (13%)
Cystoid macular oedema	6 (11.76%)	4 (8.16%)	10 (10%)
Serous retinal detachment	2 (3.92%)	2 (4.08%)	4 (4%)
Patient discomfort (moderate/severe)			
Blurry vision	39 (76.47%)	43 (89.58%)	82 (82.83%)
Metamorphopsia	26 (50.98%)	25 (52.08%)	51 (51.51%)
Relative scotoma	8 (15.68%)	8 (16.66%)	16 (16.16%)
Diplopia	7 (13.72%)	5 (10.41%)	12 (12.12%)
Micropsia	3 (5.88%)	4 (8.33%)	7 (7.07%)

BCVA, best-corrected visual acuity; ILM, internal limiting membrane.

group between baseline and M12 while it was not observed in the ILM peeling group (figure 3).

In the subgroup analysis of the temporal, nasal, inferior and superior perifoveal sectors, no significant difference in microscotoma number or in mean retinal sensitivity was found between both groups or between the different sectors.

New microscotomas appeared between baseline and M6 in 20 patients in the ILM peeling group and in 8 patients in the no ILM peeling group: these microscotomas correlated with gripping areas of the ERM or ILM in 40% (8/20) and 50% (4/8) of cases, respectively.

BCVA and patient visual discomfort

A progressive improvement in BCVA was observed in both groups after surgery (figure 3). While the postoperative BCVA was already significantly improved from M1 in the no ILM peeling group ($+4.7$ letters $p<0.0001$ at M1, $+6.8$ letters $p<0.001$ at M6 and $+7.3$ letters $p=0.0003$ at M12), it was significantly improved only from M6 in the ILM peeling group ($+2.1$ letters $p=0.2277$ at M1, $+8.41$ letters $p<0.0001$ at M6 and $+9.4$ letters $p<0.001$ at M12). However, there was no significant difference between both groups and the percentage of patients with a 10-letter improvement was similar between both groups (online supplemental e-tables 1,2).

The overall prevalence of patient-reported blurred vision decreased from 82% at baseline to 49% at M1 and 29% at M12. Metamorphopsia, relative scotoma, diplopia and micropsia tended to stabilise or improve during the follow-up and rarely worsened. These changes were similar between both groups (table 2).

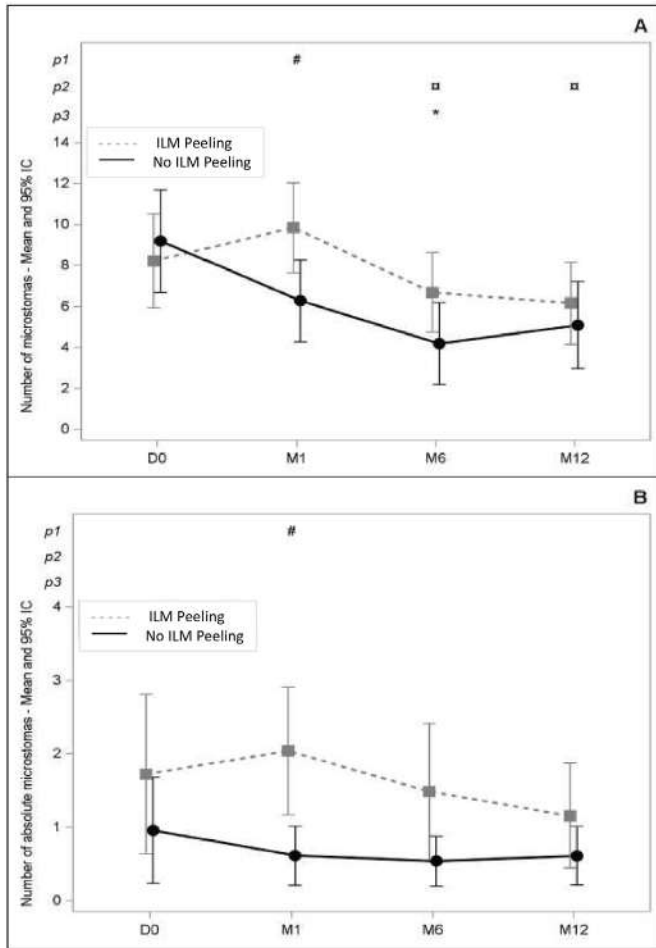


Figure 2 Change in total (A) and absolute (B) numbers of microscotomas between the ILM peeling group and no ILM peeling group Nb: number; M1: 1-month follow-up visit; M6: 6-month follow-up visit; M12: 12-month follow-up visit; p1 #: significant difference between both groups; p2 □: significant difference compared with baseline in the 'no peeling' group; p3 *: significant difference compared with baseline in the 'active peeling' group. ILM, internal limiting membrane.

OCT findings

In both groups, the mean CMT decreased between baseline and M12 (from $470.5 \pm 91.0 \mu\text{m}$ to $375.4 \pm 47.8 \mu\text{m}$ in the ILM peeling group, from $473.5 \pm 80.4 \mu\text{m}$ to $402.7 \pm 93.2 \mu\text{m}$ in the no ILM peeling group). The final CMT tended to be higher in the no ILM peeling group but there was no significant difference between both groups and this trend was reduced after the exclusion of patients with ERM recurrence from the analysis (online supplemental e-tables 3,4). In the additional analysis of the macular pericentral sectors after excluding patients with ERM recurrence, the mean superior and temporal macular retinal thicknesses were significantly lower at M12 in the ILM peeling group than in the no ILM peeling group ($-21.5 \mu\text{m}$ $p=0.0013$ and $-25.7 \mu\text{m}$ $p=0.0024$, respectively) (online supplemental e-table 5).

The mean pRNFL thickness in the temporal sector was significantly lower at M12 in the ILM peeling group than in the no ILM peeling group ($-10.4 \mu\text{m}$ $p=0.0135$) while the difference was not significant in the temporal superior sector ($-7.1 \mu\text{m}$ $p=0.0729$) and absent in the temporal inferior sector ($+1.34 \mu\text{m}$ $p=0.7642$) (online supplemental e-table 6).

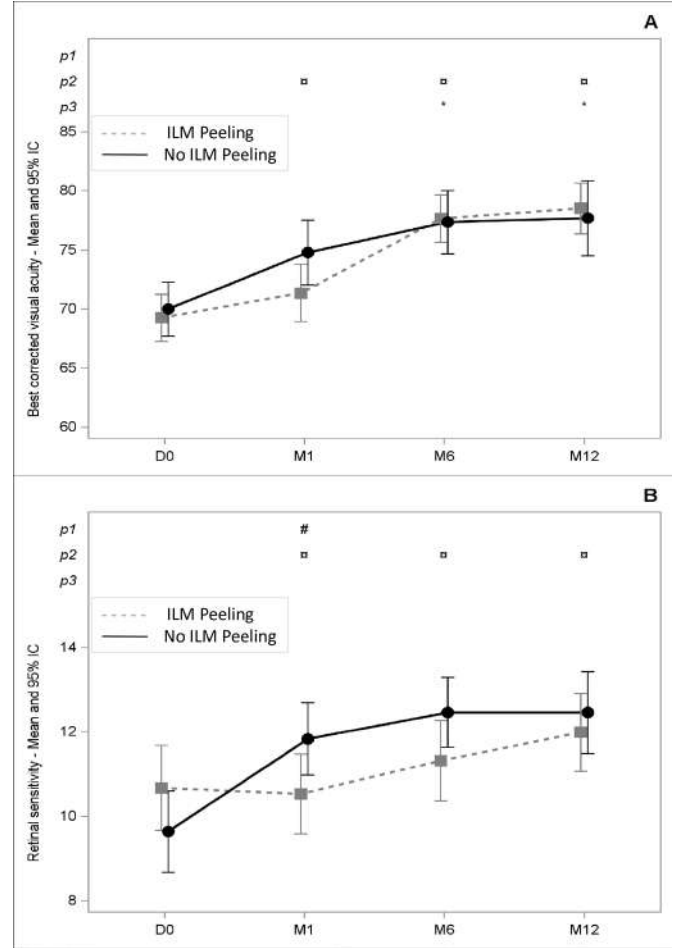


Figure 3 Change in best-corrected visual acuity (A) and retinal sensitivity (B) between the ILM peeling group and no ILM peeling group M1: 1-month follow-up visit; M6: 6-month follow-up visit; M12: 12-month follow-up visit; p1 #: significant difference between both groups; p2 □: significant difference compared with baseline in the 'no peeling' group; p3 *: significant difference compared with baseline in the 'active peeling' group. ILM, internal limiting membrane.

During the 12-month follow-up, the number of patients with DONFLs gradually increased in both groups and was significantly higher in the ILM peeling group than in the no ILM peeling group at all time points (table 2). Conversely, the rate of SANFLs was similar in both groups.

Recurrence of ERM

The ERM recurred in nine patients (19.6%) in the no ILM peeling group versus zero patient in the ILM peeling group ($p=0.0008$). Two of them underwent revision surgery at M8 and M10, because of an insufficient improvement in BCVA. The comparison of relapsing and non-relapsing patients in the no ILM peeling group at M12 did not show any significant difference in mean BCVA, mean number of microscotomas and mean retinal sensitivity (online supplemental e-table 7). However, the decrease in CMT between baseline and M12 was lower in the relapsing patients ($-33.0 \pm 137.9 \mu\text{m}$) than in the non-relapsing patients ($-94.9 \pm 90.6 \mu\text{m}$, $p=0.3080$): this difference was significant when considering the superior ($-20.3 \pm 65.4 \mu\text{m}$ vs $-78.9 \pm 56 \mu\text{m}$, $p=0.0324$) and temporal macular thicknesses ($-30.0 \pm 69.6 \mu\text{m}$ vs $-94.5 \pm 70.2 \mu\text{m}$, $p=0.0443$) (online supplemental e-table 8).

Table 2 Functional and anatomical outcomes between the ILM peeling group and no ILM peeling group

	ILM peeling group (N=51)	No ILM peeling group (N=49)	P value
Microscotomas - mean±SD (nmiss)			
D0	8.22±9.75	9.19±10.23 (2)	
M1	9.84±9.38	6.27±7.89 (5)	0.0155
M6	6.69±7.79 (6)	4.18±7.40 (10)	0.1155
M12	6.16±7.92 (7)	5.10±6.98 (18)	0.1701
Absolute microscotomas - mean±SD (nmiss)			
D0	1.73±4.64	0.96±2.95 (2)	
M1	2.04±3.69	0.61±1.59 (5)	0.0210
M6	1.49±3.69 (6)	0.54±1.25 (10)	0.1653
M12	1.16±2.82 (7)	0.61±1.31 (18)	0.3194
Relative microscotomas - mean±SD (nmiss)			
D0	6.49±7.62	8.23±9.24 (2)	
M1	7.80±8.05	5.66±7.12 (5)	0.0608
M6	5.20±5.70 (6)	3.64±6.57 (10)	0.1270
M12	5.00±6.48 (7)	4.48±6.62 (18)	0.5001
BCVA - mean±SD (nmiss)			
D0	69.25±8.51	70.00±9.58	
M1	71.35±10.36	74.78±11.05 (3)	0.1186
M6	77.67±8.33 (3)	77.35±9.96 (9)	0.4916
M12	78.53±8.61 (6)	77.71±10.98 (15)	0.3927
Retinal sensitivity (dB) - mean±SD (nmiss)			
D0	10.67±4.29	9.64±3.94 (2)	
M1	10.53±3.99 (1)	11.83±3.34 (6)	0.0357
M6	11.32±3.81 (6)	12.46±3.03 (11)	0.0877
M12	11.99±3.55 (9)	12.46±3.12 (19)	0.2098
Blurry vision - n (%) (nmiss)			
Stable or improvement D0/M1	41 (83.67) (2)	40 (88.89) (4)	0.4734
Stable or improvement D0/M6	41 (95.35) (8)	37 (94.87) (10)	0.9182
Stable or improvement D0/M12	38 (90.48) (9)	30 (88.24) (15)	0.8130
Metamorphopsia - n (%) (nmiss)			
Stable or improvement D0/M1	46 (93.88) (2)	42 (93.33) (4)	0.9153
Stable or improvement D0/M6	41 (95.35) (8)	35 (89.74) (10)	0.3542
Stable or improvement D0/M12	41 (97.62) (9)	31 (91.18) (15)	0.2770
Relative scotomia - n (%) (nmiss)			
Stable or improvement D0/M1	43 (87.76) (2)	42 (93.33) (4)	0.3662
Stable or improvement D0/M6	40 (93.02) (8)	37 (94.87) (10)	0.7281
Stable or improvement D0/M12	36 (85.71) (9)	34 (100.0) (15)	0.9733
Diplopia - n (%) (nmiss)			
Stable or improvement D0/M1	46 (93.88) (2)	42 (93.33) (4)	0.9142
Stable or improvement D0/M6	39 (90.70) (8)	37 (94.87) (10)	0.4753
Stable or improvement D0/M12	40 (95.24) (9)	34 (100.0) (15)	0.9757
Micropsia - n (%) (nmiss)			
Stable or improvement D0/M1	43 (87.76) (2)	44 (97.78) (4)	0.1064
Stable or improvement D0/M6	38 (90.48) (8)	38 (97.44) (10)	0.2065
Stable or improvement D0/M12	37 (92.50) (9)	33 (97.06) (15)	0.4091
pRNFL temporal+superior temporal+inferior temporal - mean±SD (nmiss)			
D0	115.42±28.94	118.57±16.49 (1)	
M1	116.69±26.22 (1)	119.76±20.32 (6)	0.8382

Continued

Table 2 Continued

	ILM peeling group (N=51)	No ILM peeling group (N=49)	P value
M6	103.45±24.58 (6)	111.86±19.88 (9)	0.0119
M12	100.02±24.21 (12)	109.75±20.32 (16)	0.0311
DONFL - n (%) (nmiss)			
M1	19 (38.00) (1)	7 (15.56) (4)	0.0028
M6	24 (50.00) (3)	8 (20.00) (9)	0.0003
M12	27 (61.36) (7)	13 (38.24) (15)	0.0132
SANFL - n (%) (nmiss)			
M1	4 (8.00) (1)	4 (8.70) (3)	0.8735
M6	6 (12.77) (4)	6 (15.00) (9)	0.8221
M12	5 (11.36) (7)	4 (11.76) (15)	0.7634
ERM recurrence - n (%) (nmiss)			
M12	0 (0.00) (1)	9 (19.57) (3)	0.0008

*Statistically significant, p<0.05.
BCVA, best-corrected visual acuity; DONFL, dissociation of the optic nerve fiber layer; ERM, epiretinal membrane; ILM, internal limiting membrane; pRNFL, peripapillary retinal nerve fiber layer; SANFL, swelling of the arcuate nerve fiber layer.

Adverse events

There were respectively 1 and 7 severe surgery-related adverse event in the no ILM peeling group (post-traumatic choroidal neovascularisation) and in the ILM peeling group (metamorphopsia, visual field defects, blurred vision, visual discomfort, scotoma) affecting a single patient. There were no cases of retinal detachment or endophthalmitis.

Enrolment data and other outcome measurements were overall similar between inclusion centre (online supplemental e-table 9,10). A difference in the initial rates of pseudomacular holes and intraretinal oedema was observed in centres 3 and 4 (online supplemental e-table 9): a further comparison between centre 3 and centre 4 revealed no significant difference in the evolution of microscotomas (online supplemental e-table 11). Patients with intraretinal oedema at baseline tended to have more microscotomas at baseline than patients without intraretinal oedema (11.96±10.8 vs 7.56±9.45, p=0.08): a further comparison revealed no significant difference in the evolution of microscotomas (online supplemental e-table 12).

DISCUSSION

Active ILM peeling was associated with a delayed improvement in BCVA, an increased microscotoma number and a decreased mean retinal sensitivity at M1, a decreased superior and temporal macular thicknesses, an increased loss in RNFL thickness, an increased rate of DONFL and prevented an improvement in mean retinal sensitivity during the 12-month follow-up.

The similar BCVA found at M12 in the ILM peeling group and no ILM peeling group is consistent with the results of the most recent meta-analysis.^{14 15} The delayed improvement in BCVA is consistent with a previous retrospective study in which additional ILM peeling was associated with a poorer BCVA and a higher number of photoreceptor defects on OCT only 1 month after surgery.¹⁶ Microperimetry provides refined quantitative data about the retinal sensitivity of the central retina. Therefore, microperimetry of the included patients with ERM associated with decrease in BCVA found some pre-existing visual defects: microscotomas were absolute (sensitivity=0 dB) or relative (sensitivity <10 dB) (table 2). After ERM peeling, a significant increase in mean retinal sensitivity was observed only in the no ILM peeling group in correlation with the increase in BCVA (figure 3). This increase in mean retinal sensitivity explains the

significant reduction in the number of microscotomas observed in the no ILM peeling group (figure 2).

The use of scanning laser ophthalmoscope microperimetry with eye tracking was the main strength of our study because it highlighted visual impairments that were not detectable based on the BCVA assessment.

As the decibel scale used in microperimetry is a logarithmic scale, a loss of three decibels in retinal sensitivity means that a doubling of the amount of light is required to see the spot. Case series of patients who underwent macular hole surgery have found an increase in microscotoma number after ILM peeling,¹⁰ a decrease in retinal sensitivity in the perifoveal temporal sector¹⁷ and an increase in mean retinal sensitivity in the normal retina surrounding the macular hole.¹⁸ During ERM surgery, a retrospective study has found a significant increase in microscotoma number after active ILM peeling compared with spontaneous ILM peeling.¹¹ A randomised clinical trial (RCT) has found a slight drop in foveal sensitivity after 'complete' ILM peeling compared with a significant improvement in foveal sensitivity after 'foveal sparing' ILM peeling.¹⁹ Another RCT has found an increase in absolute microscotoma number and a poorer improvement in mean central retinal sensitivity after ILM peeling compared with no ILM peeling.²⁰ However, no ILM staining was performed in the 'no ILM peeling' group so that spontaneous ILM peeling was neither diagnosed nor taken into account.

The other strength of our study was that patients were randomised in the operating room just after ERM peeling and ILM staining, allowing randomising only patients whose ILM was still attached. Indeed, spontaneous ILM peeling is common: 50% of spontaneous ILM peeling >4 optic disc diameters in our study and 31% of spontaneous ILM peeling >50% of the macular area in a previous retrospective study.¹¹ Similarly, Tranos *et al* have reported 80% of spontaneous ILM peeling on all-size areas and 50% of spontaneous ILM peeling >50% of the peeled ERM area.²¹ Randomising in the operating room was therefore particularly relevant and unusual: in other RCTs comparing ERM surgery with and without ILM peeling, patients were randomised before surgery and cases with spontaneous peeling were not taken into account.^{20 22–24}

In our study, active ILM peeling was associated with a significant decrease in pRNFL thickness and an increase in DONFL rate. These findings had never been reported before and the pRNFL thickness had not been assessed in previous RCTs.^{19 20 22–24} These findings are consistent with cases series of patients who underwent ERM and macular hole surgery.^{7 8 25 26} We also showed the presence of DONFL in the no ILM peeling group and there was no difference in the rate of SANFL with and without ILM peeling. These data suggest that the qualitative alterations of the RNFL are not as specific to ILM peeling as retrospective studies had asserted.

We observed a protective effect of active ILM peeling on ERM recurrence. These data are valuable because the data available were not conclusive: the most recent meta-analysis study has found a significant reduction in recurrence rate after ILM peeling during idiopathic ERM surgery (OR: 0.26 (0.19–0.37), respectively),¹⁵ but a meta-analysis of only prospective studies has failed to show any significant difference (OR: 0.21 (0.04–1.05)).¹⁴ This discrepancy could be due to undiagnosed cases of spontaneous ILM peeling in the 'no peeling' groups, which could have artificially decreased the recurrence rate. In case of ERM recurrence, a visual impairment has been reported in only half of the patients and ERM surgery might be repeated in these cases.²⁷ In our study, the proportion of patients with a visual

impairment for whom second ERM surgery was needed was lower and patients experiencing ERM recurrence had similar visual outcomes to those of patients experiencing no recurrence.

The main limitation in interpreting the results was that the increase in microscotoma number in the ILM peeling group was not significant at M6. Similarly, the decrease in mean retinal sensitivity was only significant at M1. It could be explained either by the regenerative capacity of the retina or by the lack of study power due to the small sample size and patients lost to follow-up. To standardise the surgical procedure, the study only allowed the use of Eckardt microforceps to pinch the ILM, so we do not know whether using another device could make a difference in the induction of microscotomas. No microperimetry data is available about the use of other devices such as flex loop of diamond dusted scraper but the few anatomical data available show that they also induce retinal damages.^{28–30}

In summary, spontaneous ILM peeling was very common. Active ILM peeling prevented anatomical ERM recurrence but ERM recurrences were not associated with a significant visual impairment and a surgical revision was rarely needed at 1 year. Active ILM peeling induced anatomic retinal damages, delayed visual recovery in terms of BCVA and microscotomas and prevented improvement in mean retinal sensitivity. As the increase in microscotomas found at M1 recovered throughout the follow-up, the PEELING study does not settle the debate of active ILM peeling during idiopathic ERM surgery. To peel or not to peel the ILM remains an open question. Every surgeon needs to keep the pros and cons in mind to determine for each patient whether the risk of microscotomas outweighs the 20% risk of anatomical ERM recurrence at 1 year and the 4% risk of revision surgery at 1 year. Longer follow-up data could help to answer this question.

Author affiliations

¹CHU Nantes Department of Ophthalmology, Nantes University, Nantes, France

²Inserm, CIC 1413, CHU Nantes, Nantes, Pays de la Loire, France

³CHU Nantes, Sponsor Département, Nantes University, Nantes, Pays de la Loire, France

⁴Ophthalmology department, Hoital Lariboisière, AP-HP, Université Paris 7 - Sorbonne Paris Cité, Paris, France

⁵Ophthalmology, CHU Dijon, Dijon, Bourgogne-Franche-Comté, France

⁶Fondation Ophtalmologique Adolphe de Rothschild, Paris, France

⁷Ophthalmology Department, Polyclinique de l'Atlantique, Saint Herblain, France

Acknowledgements This study was supported by a grant from the French Ministry of Health awarded in 2013 (under the Hospital Clinical Research Program), no.13-0170. We thank Sophie Pegorier (EURL Pegorier Traductions) for her careful English proofreading. The CFSR (Club Francophone des spécialistes de la rétine) supports this trial and all the participants are part of it.

Contributors MW and JB-D had full access to all of the data of the study and take responsibility for the integrity of the data and the accuracy of the data analysis. Guarantor author: JB-D. Study concept and design: MW. Acquisition, analysis or interpretation of data: All authors. Drafting of the manuscript: J-BD, AP. Critical revision of the manuscript for important intellectual content: All authors. Statistical analysis: CV. Obtained funding: MW. Administrative, technical or material support: JF, AJ, FB, CI and AP. Study supervision: MW, J-BD, JF and CI.

Funding This study was supported by a grant from the French Ministry of Health awarded in 2013 (under the Hospital Clinical Research Program), no. 13-0170. This grant was allocated following a peer review.

Competing interests None declared.

Patient consent for publication Consent obtained directly from patient(s).

Ethics approval This study involves human participants and was approved by Comité de Protection des Personnes Ouest IV - Nantes^o 13/14. Participants gave informed consent to participate in the study before taking part.

Provenance and peer review Not commissioned; externally peer reviewed.

Data availability statement All data relevant to the study are included in the article or uploaded as supplementary information.

Supplemental material This content has been supplied by the author(s). It has not been vetted by BMJ Publishing Group Limited (BMJ) and may not have been peer-reviewed. Any opinions or recommendations discussed are solely those of the author(s) and are not endorsed by BMJ. BMJ disclaims all liability and responsibility arising from any reliance placed on the content. Where the content includes any translated material, BMJ does not warrant the accuracy and reliability of the translations (including but not limited to local regulations, clinical guidelines, terminology, drug names and drug dosages), and is not responsible for any error and/or omissions arising from translation and adaptation or otherwise.

Open access This is an open access article distributed in accordance with the Creative Commons Attribution Non Commercial (CC BY-NC 4.0) license, which permits others to distribute, remix, adapt, build upon this work non-commercially, and license their derivative works on different terms, provided the original work is properly cited, appropriate credit is given, any changes made indicated, and the use is non-commercial. See: <http://creativecommons.org/licenses/by-nc/4.0/>.

ORCID iD

Jean-Baptiste Ducloyer <http://orcid.org/0000-0002-1306-1908>

REFERENCES

- Meurer SM, Myers CE, Klein BEK, et al. The epidemiology of Vitreoretinal interface abnormalities as detected by spectral-domain optical coherence tomography: the beaver dam eye study. *Ophthalmology* 2015;122:787–95.
- Azuma K, Ueta T, Eguchi S, et al. Effects of internal limiting membrane peeling combined with removal of idiopathic epiretinal membrane: a systematic review of literature and meta-analysis. *Retina Phila Pa* 2017. 10.1097/IAE.0000000000001537. Available: <https://pubmed.ncbi.nlm.nih.gov/28207608/>
- Far PM, Yeung SC, Ma PE, et al. Effects of internal limiting membrane peel for idiopathic epiretinal membrane surgery: a systematic review of randomized controlled trials. *Am J Ophthalmol* 2021;231:79–87.
- Hussain N, Mitra S. Multiple Extrafoveal macular holes following internal limiting membrane peeling. *Int Med Case Rep J* 2018;11:105–11.
- Rush RB, Simunovic MP, Aragon AV, et al. Postoperative macular hole formation after vitrectomy with internal limiting membrane peeling for the treatment of epiretinal membrane. *Retina* 2014;34:890–6.
- Wolf S, Schnurbusch U, Wiedemann P, et al. Peeling of the basal membrane in the human retina: ultrastructural effects. *Ophthalmology* 2004;111:238–43.
- Tadayoni R, Paques M, Massin P, et al. Dissociated optic nerve fiber layer appearance of the fundus after idiopathic Epiretinal membrane removal. *Ophthalmology* 2001;108:2279–83.
- Runkle AP, Srivastava SK, Yuan A, et al. FACTORS associated with development of dissociated optic nerve fiber layer appearance in the pioneer intraoperative optical coherence tomography study. *Retina* 2018;38 Suppl 1:S103–9.
- Clark A, Balducci N, Pichi F, et al. Swelling of the Arcuate nerve fiber layer after internal limiting membrane peeling. *Retina* 2012;32:1608–13.
- Tadayoni R, Svorenova I, Erginay A, et al. Decreased retinal sensitivity after internal limiting membrane peeling for macular hole surgery. *Br J Ophthalmol* 2012;96:1513–6.
- Deltour J-B, Grimbert P, Masse H, et al. Detrimental effects of active internal limiting membrane peeling during epiretinal membrane surgery. *Retina* 2017;37:544–52.
- Ducloyer J-B, Ivan J, Poinas A, et al. Does internal limiting membrane peeling during epiretinal membrane surgery induce microscotomas on microperimetry? Study protocol for PEELING, a randomized controlled clinical trial. *Trials* 2020;21:500.
- Schulz KF, Altman DG, Moher D, et al. CONSORT 2010 statement: updated guidelines for reporting parallel group randomised trials. *BMJ* 2010;340:c332.
- Sun Y, Zhou R, Zhang B. With or without internal limiting membrane peeling for idiopathic epiretinal membrane: a meta-analysis of randomized controlled trials. *Retina Phila Pa* 2021;41:1644–51.
- Huang Q, Li J. With or without internal limiting membrane peeling during idiopathic epiretinal membrane surgery: A meta-analysis. *PLoS ONE* 2021;16:e0245459.
- Ahn SJ, Ahn J, Woo SJ, et al. Photoreceptor change and visual outcome after idiopathic epiretinal membrane removal with or without additional internal limiting membrane peeling. *Retina* 2014;34:172–81.
- Tao J, Yang J, Wu Y, et al. Internal limiting membrane peeling distorts the retinal layers and induces scotoma formation in the perifoveal temporal macula. *Retina* 2022;42:2276–83.
- Qi Y, Wang Z, Li S-M, et al. Effect of internal limiting membrane peeling on normal retinal function evaluated by microperimetry-3. *BMC Ophthalmol* 2020;20:140.
- Russo A, Morescalchi F, Gambicorti E, et al. Epiretinal membrane removal with foveal-sparing internal limiting membrane peeling: a pilot study. *Retina* 2019;39:2116–24.
- Ripandelli G, Scarinci F, Piaggi P, et al. Macular pucker: to peel or not to peel the internal limiting membrane? A microperimetric response. *Retina Phila Pa* 2015;35:498–507.
- Tranos P, Wickham L, Dervenis N, et al. The role of membrane-inner retina adherence in predicting simultaneous internal limiting membrane peeling during idiopathic epiretinal membrane surgery. *Eye* 2017;31:636–42.
- De Novelli FJ, Goldbaum M, Monteiro MLR, et al. Surgical removal of epiretinal membrane with and without removal of internal limiting membrane: comparative study of visual acuity, features of optical coherence tomography, and recurrence rate. *Retina* 2019;39:601–7.
- Tranos P, Koukoulas S, Charteris DG, et al. The role of internal limiting membrane peeling in epiretinal membrane surgery: a randomised controlled trial. *Br J Ophthalmol* 2017;101:719–24.
- Storch MW, Khattab MH, Lauermaier P, et al. Macular pucker surgery with and without delamination of the internal limiting membrane - a prospective randomized study. *Ophthalmol Z Dtsch Ophthalmol Ges* 2019;116:1038–45.
- He S, Ye X, Qiu W, et al. Analysis of retinal microstructure in eyes with dissociated optic nerve fiber layer (DONFL) appearance following idiopathic macular hole surgery: an optical coherence tomography study. *J Pers Med* 2023;13:255.
- Faria MY, Ferreira NP, Cristóvão DM, et al. Tomographic structural changes of retinal layers after internal limiting membrane peeling for macular hole surgery. *Ophthalmic Res* 2018;59:24–9.
- Diaz-Valverde A, Wu L. To peel or not to peel the internal limiting membrane in idiopathic epiretinal membranes. *Retina* 2018;38:S5–11.
- Uchida A, Srivastava SK, Ehlers JP. Analysis of retinal architectural changes using intraoperative OCT following surgical manipulations with membrane flex loop in the DISCOVER study. *Invest Ophthalmol Vis Sci* 2017;58:3440–4.
- Leung EH, Flynn HW, Rosenfeld PJ. Crescent-shaped retinal defects associated with membrane peeling with a diamond-dusted membrane scraper. *Ophthalmic Surg Lasers Imaging Retina* 2016;47:90–3.
- Bagci F, Citirik M, Dülger SÇ, et al. Standard internal limiting membrane peeling versus internal limiting membrane abrasion technique for primary epiretinal membrane surgery. *ABO* 2022;87.